

# The Buccal Fat Pad Flap for Periorbital Reconstruction: A Cadaver Dissection and Report of Two Cases

Luther H. Holton, III, M.D., Eduardo D. Rodriguez, D.D.S., M.D., Ronald P. Silverman, M.D., Navin Singh, M.D., Anthony P. Tufaro, D.D.S., M.D., and Michael P. Grant, M.D., Ph.D.

Baltimore, Md.

The buccal fat pad is a trilobed collection of adipose tissue found in the midface. It is located behind the zygomatic arch, medial to the masseter muscle and lateral to the buccinator muscle from which it derives its name.<sup>1-4</sup> It consists of a body and four processes: the buccal, pterygoid, superficial, and deep temporal.<sup>1-3</sup> The body lies behind the zygomatic arch and the processes extend from the body to their respective surrounding tissue spaces.<sup>4</sup> The buccal fat pad has recently been described as having three lobes: an anterior lobe, an intermediate lobe, and a posterior lobe.<sup>4</sup> The pad receives an abundant vascular supply from three well-defined sources, namely, the facial and internal maxillary arteries and the deep transverse facial vessels.<sup>2,4</sup> The major vascular supply enters the posterior lobe, requiring that this lobe remain attached when the buccal fat pad is used as a pedicled flap. Notably, the size of the pad remains relatively constant from childhood throughout adulthood, and it appears to be resistant to wasting even in the most cachectic patients.

The buccal fat pad has been proposed to have a number of native functions. It fills the masticatory space and has traditionally been suggested to have a role in mastication and suckling, especially in the newborn. The pad functions as a gliding pad during the contraction of the masticatory and mimetic muscles.<sup>4</sup> In addition, it protects the deep facial neurovascular bundles from outside forces as well as from extrusion of muscle contraction. It may

serve as a venous network involved in cranial blood flow through the pterygoid plexus.<sup>5</sup> Despite these various proposed functions, the buccal fat pad can be safely sacrificed in the adult patient.

Clinically, the buccal fat pad has been used for aesthetic and reconstructive applications.<sup>1-3,6,7,8-11</sup> In cosmetic surgery, buccal fat pad lipectomy has been used to improve midface width in full-faced individuals.<sup>6-8</sup> Similarly, buccal fat pad removal has been used alone and in conjunction with face lift surgery to modify facial contours and enhance the malar prominence.<sup>2,6,8,9</sup> In addition, it has been described in rhytidectomy for improvement of the nasolabial fold.<sup>4</sup> As early as 1977, the reconstructive use of a pedicled buccal fat pad flap was described by Egyedi<sup>10</sup> for the closure of oroantral and oronasal communications following oncologic resection. In 1983, Neder<sup>11</sup> elucidated its use as a free graft for the oral cavity. A number of other studies have further described the use of buccal fat pad flaps and grafts for the reconstruction of intraoral defects. The versatility of the buccal fat pad is evident from the variety of other novel reconstructive uses that have been described, including coverage of irregularities following bony trauma, closure of nasal defects, and use as vascularized filler material.<sup>3,10,11</sup> There is, however, no literature describing its use in orbital reconstruction.

Using a cadaver study, we demonstrate that the buccal fat pad can be reliably mobilized to provide sufficient coverage for orbital reconstructions. In addition, we present two case

From the University of Maryland Medical System and Johns Hopkins Hospital. Received for publication October 29, 2003; revised February 5, 2004.

DOI: 10.1097/01.PRS.0000138257.44949.BB

studies using this technique. We conclude by discussing the advantages and potential drawbacks of this novel approach for orbital reconstruction.

#### MATERIALS AND METHODS

In the cadaver study, eight bilateral buccal fat pad dissections were performed on four cadavers via a Weber-Ferguson approach. A combination of blunt and sharp dissection was used to expose and mobilize the anterior and intermediate lobes of the pad while the posterior lobe remained attached to the vascular supply. Of note, in those patients who have undergone maxillectomy and require orbital floor reconstruction, less length would be needed to reach the orbit. After the pads were mobilized to allow the maximum cephalad reach, measurements were taken to ascertain the length of the flaps. Length of flap was defined by a measurement taken from the alveolar ridge at the level of the second molar to the cephalad aspect of the mobilized flap.

#### RESULTS

The mean length of the buccal fat pad flap was 9.34 cm (SD,  $\pm 0.76$  cm), with an average approximate volume of 24 cm<sup>3</sup>. In all eight dissections, the length of the flap and the volume of mobilized tissue were easily sufficient to cover the inferior orbital rim, despite the fact

that none of the cadavers had undergone resection of the maxilla. Figure 1 depicts the relevant regional anatomy and the arc of rotation.

#### CASE REPORTS

##### Case 1

A 74-year-old man presented with metastatic melanoma involving the left paranasal sinuses. The tumor involved the cheek, eyelid, nasal sidewall, anterior wall of the maxilla, orbital rim, and orbital floor. The tumor was extirpated following a modified Weber-Ferguson approach (Fig. 2).

After resection of the soft and hard tissues, including a partial maxillectomy and 50 percent of the orbital floor, the orbit was reconstructed with a titanium plate along the rim and porous polyethylene along the orbital floor. Due to fears of exposure and infection, recruitment of vascularized tissue was indicated. The buccal fat pad was dissected and utilized to provide vascular lining for the synthetic implant (Fig. 3).

The buccal fat pad was harvested by mobilizing the anterior attachments while preserving the posterior lobe and its vascular supply. The facial nerve was not disturbed during the dissection. The flap was advanced medially, protecting its posterior vascular pedicle, and inset along the orbital floor, separating the implant from the maxillary sinus. The skin defect was closed using a cervicofacial rotation flap.

At his 6-month postoperative visit, the patient was doing well and had minimal scleral show, no diplopia, and no difficulties with his orbital floor implant (Fig. 4). By 7 months, his tumor was noted to have recurred and he went on to have a radical craniofacial resection of the previously reconstructed left orbital area.

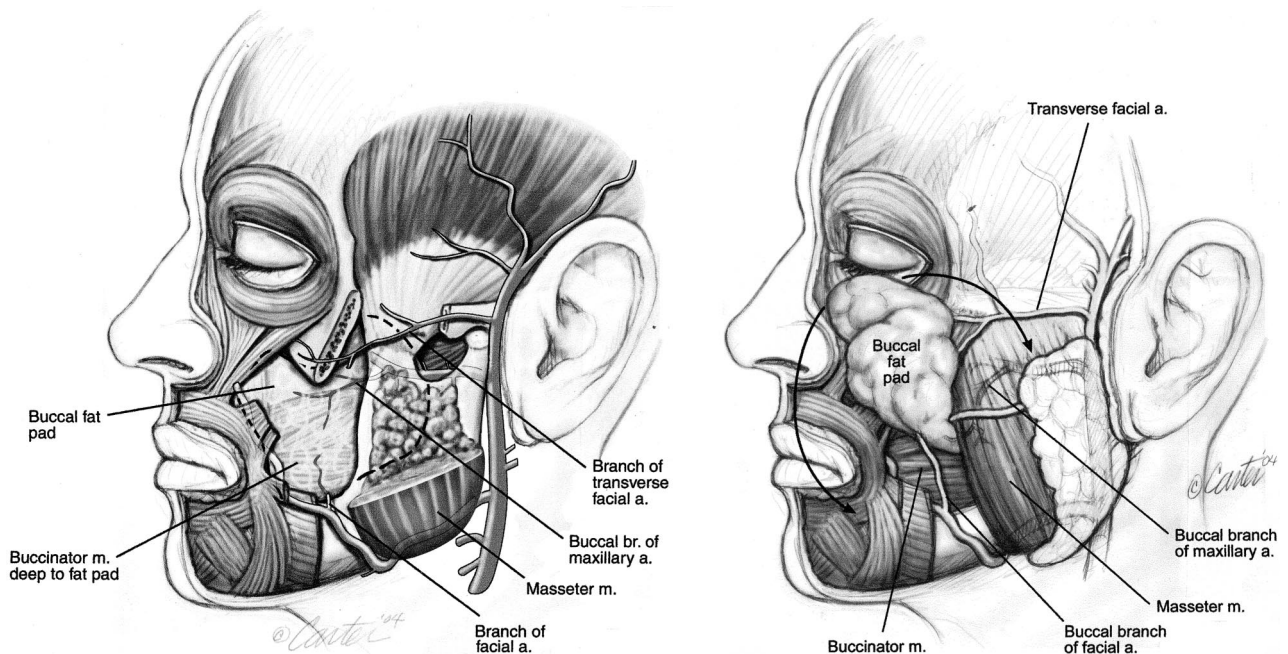


FIG. 1. (Left) Illustration of the buccal space demonstrating its relationship to the buccinator and masseter muscles as well as the blood supply. (Right) Illustration demonstrating the arc of rotation of the buccal fat pad.

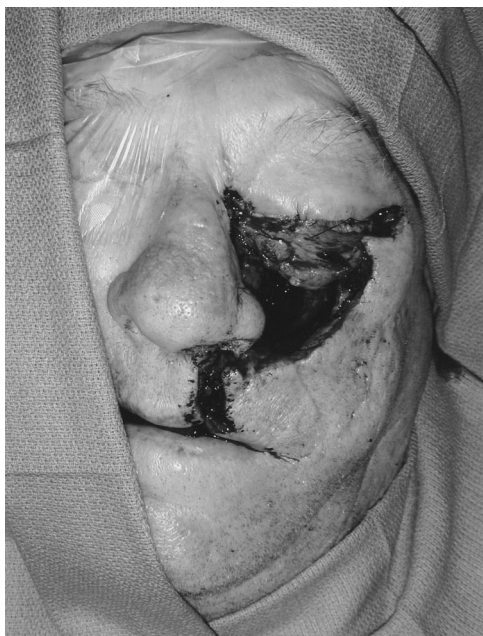

FIG. 2. Case 1. Facial defect following tumor extirpation.

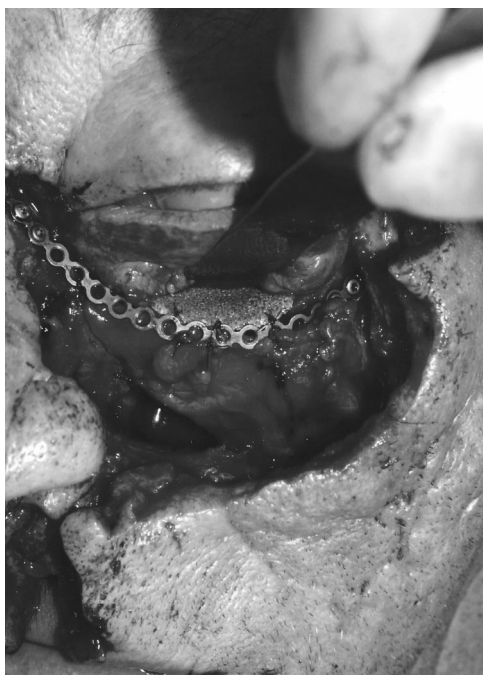

FIG. 3. Case 1. Orbital floor reconstruction with titanium, porous polyethylene, and the pedicled buccal fat pad.

### Case 2

A 32-year-old man presented for evaluation and management of a lipo-epithelial carcinoma of his right maxillary sinus. The tumor involved the maxilla and palate, extending back to the junction of the hard and soft palate, nasal fossa, and orbital floor. The tumor was extirpated following a modified Weber-Ferguson approach.

After extensive resection of the right maxilla, including 90 percent of the orbital floor and pterygoid plates, a large

defect resulted (Fig. 5, *left*). The orbital floor was reconstructed using a thick sheet of AlloDerm (Lifecell Corporation, Branchburg, N.J.) (Fig. 5, *center*), which was inset to stable bone. The buccal fat pad was dissected and used to provide a vascular bed for the AlloDerm and to augment the soft-tissue volume.

The buccal fat pad was harvested in a similar fashion as previously described and inset along the orbital floor and rim (Fig. 5, *right*). The Weber-Ferguson skin flap was passively replaced, and the open intraoral maxillary defect, measuring 4 × 6 cm, was lined with a split-thickness skin graft. A palatal prosthesis was utilized to obturate the defect.

At the 3-month postoperative visit, the patient was doing well, with mild postradiation changes of the right lower eyelid. There was no evidence of scleral show, diplopia, or limitation of ocular motion (Fig. 6).

### DISCUSSION

The anatomical location of the buccal fat pad makes it an ideal source of tissue for orbital reconstruction. It is easily visualized and mobilized following the buccal vestibular incision for the Weber-Ferguson approach. This extended approach avoids injury to the facial nerve. We believe the buccal fat pad can also be accessed via combined transconjunctival and upper gingival buccal sulcus incisions. The buccal fat pad is a structure that persists at a constant volume throughout life, even in patients with extreme wasting of other fat stores.<sup>6,12</sup> Therefore, it can be utilized in nearly all patients, except in those who have had previous procedures that violated the fat pad.

As described above, the buccal fat pad is a highly vascular structure that derives its arterial

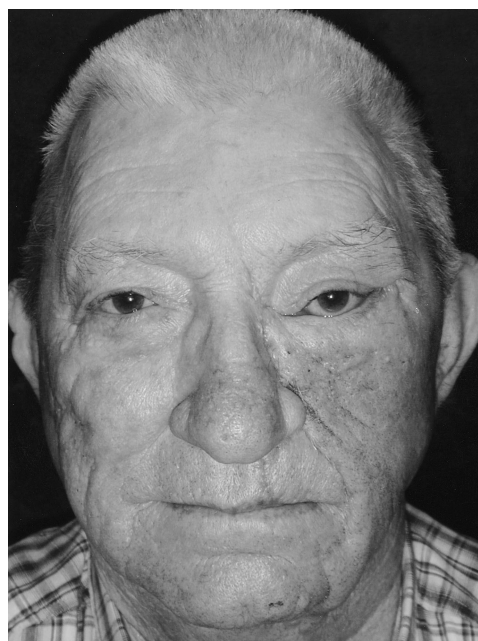


FIG. 4. Six-month follow-up view of the patient in case 1.



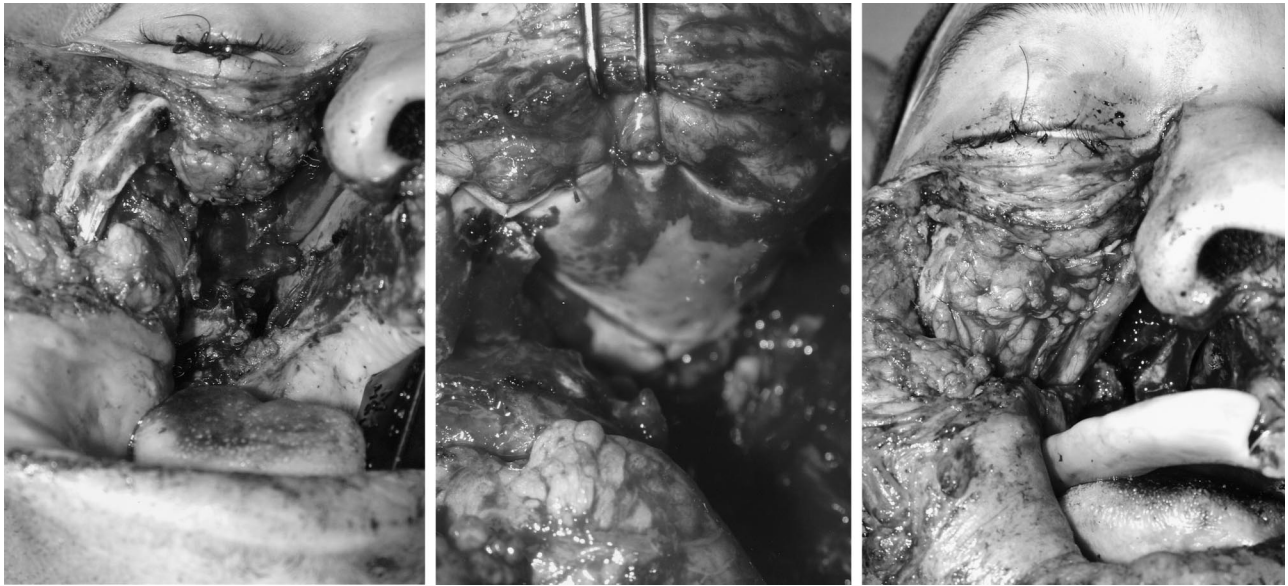


FIG. 5. Case 2. (Left) Facial defect following tumor extirpation. (Center) Orbital floor reconstruction with AlloDerm. (Right) Orbital floor reconstruction with pedicled buccal fat pad.

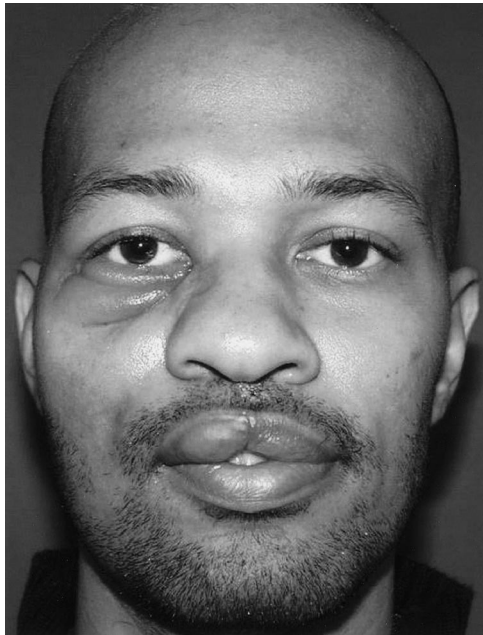

FIG. 6. Three-month follow-up view of patient in case 2.

blood supply from a rich network. Furthermore, its venous plexus is robust, and the pad has been suggested to play a role in drainage from the pterygoid plexus. This robust vascularity obviously supports the viability of this structure in its reconstructive applications. Accordingly, the buccal fat pad can be expected to serve as a valuable source of vascular tissue when alloplastic or biologic implants are being used. This is germane to orbital reconstruction, as favored methods utilize titanium, po-

rous polyethylene implants, and various allograft materials, including AlloDerm.<sup>13,14</sup>

Although the flap is robust and accessible, potential drawbacks exist. Mobilization of the fat pad may create diminished midface volume or asymmetry that can be aesthetically displeasing. In addition, this flap is limited by a relatively small volume of available tissue. This volume is generally adequate for coverage of periorbital prosthetics, but for massive soft-tissue defects, other options, such as local tissue flaps (temporalis muscle flap) or free-tissue transfer, should be considered.

Since the buccal fat pad is a highly vascular and fatty tissue, we believe this may improve the tolerance to radiation therapy. However, to date, this has not been documented and may be worthy of further investigation, since it is proposed for patients who have recently undergone oncologic resection and may proceed to radiation therapy.

#### SUMMARY

We have shown that the buccal fat pad is a robust and reliable flap that may improve the success rate of orbital reconstruction by providing well-vascularized tissue of suitable volume. The buccal fat pad has been utilized for numerous aesthetic and reconstructive facial applications and provides excellent vascularized tissue support when alloplastic or allograft materials are being used. We propose that using the pedicled buccal fat pad in conjunction with

titanium, porous polyethylene mesh, polyamide sheets, or various other allograft materials can improve the success rates of reconstruction. This approach has not previously been described in the literature. This technique is an excellent compliment to periorbital reconstruction given the ease of dissection, quality of vascularized tissue, and consistent volume between patients.

Ronald P. Silverman, M.D.

Division of Plastic and Reconstructive Surgery

University of Maryland Medical Center

22 South Greene Street, S8D12

Baltimore, Md. 21201

rsilverman@smail.umaryland.edu

#### REFERENCES

1. Dean, A., Alamillos, F., Garcia-Lopez, A., Sanchez, J., and Penalba, M. The buccal fat pad flap in oral reconstruction. *Head Neck* 23: 383, 2001.
2. Stuzin, J. M., Wagstrom, L., Kawamoto, H. K., Baker, T. J., and Wolfe, S. A. The anatomy and clinical applications of the buccal fat pad. *Plast. Reconstr. Surg.* 85: 29, 1990.
3. Tideman, H., Bosanquet, A., and Scott, J. Use of the buccal fat pad as a pedicled graft. *J. Oral Maxillofac. Surg.* 44: 435, 1986.
4. Zhang, H.-M., Yan, Y.-P., Qi, K.-M., Wang, J.-Q., and Liu, Z.-F. Anatomical structure of the buccal fat pad and its clinical adaptations. *Plast. Reconstr. Surg.* 109: 2509, 2002.
5. Racz, I., Maros, T. N., and Seres-Sturm, L. Structural characteristics and functional significance of the buccal fat pad (corpus adiposum buccae). *Morphol. Embryol.* 35: 73, 1989.
6. Matarasso, A. Anatomy of the buccal fat pad and its clinical significance. *Plast. Reconstr. Surg.* 103: 2061, 1999.
7. Matarasso, A. Buccal fat pad excision: Aesthetic improvement of the midface. *Ann. Plast. Surg.* 26: 413, 1991.
8. Jackson, I. T. Anatomy of the buccal fat pad and its clinical significance. *Plast. Reconstr. Surg.* 103: 2059, 1999.
9. Ramirez, O. M. Buccal fat pad pedicle flap for midface augmentation. *Ann. Plast. Surg.* 43: 109, 1999.
10. Egyedi, P. Utilization of the buccal fat pad for closure of oral-antral and/or oral-nasal communications. *J. Maxillofac. Surg.* 5: 241, 1977.
11. Neder, A. Use of the buccal fat pad for grafts. *Oral Surg. Oral Med. Oral Pathol.* 55: 349, 1983.
12. Xiao, H., Bayramicli, M., and Jackson, I. T. Volumetric analysis of the buccal fat pad. *Eur. J. Plast. Surg.* 22: 177, 1999.
13. Schubert, W., Gear, A. J., Lee, C., et al. Incorporation of titanium mesh in orbital and midface reconstruction. *Plast. Reconstr. Surg.* 110: 1022, 2002.
14. Villarreal, P. M., Monje, F., Morillo, A. J., et al. Porous polyethylene implants in orbital floor reconstruction. *Plast. Reconstr. Surg.* 109: 877, 2002.