

# SOFT TISSUE INJURIES

*Navin Singh • Karen A. McQuillan*

Because the skin is the enveloping external organ of the human organism, it is the first line of defense in any injury and thus is nearly always injured when trauma occurs. Although a soft tissue injury may not be the critical illness from which a trauma victim suffers, it can contribute to the challenges of clinical management. Injury to skin and soft tissues predisposes the individual to secondary complications such as (1) localized and systemic infection, (2) hypoproteinemia, (3) hypothermia, and (4) sequelae related to tissue necrosis. Soft tissue injury and subsequent complications incur a high financial cost—not only from direct health care costs, but also from workdays lost for the patient and decreased quality of life secondary to having to live with scars or deformity.

Minimizing the risk of secondary complications and maximizing wound healing foster achievement of optimal outcomes for the patient with soft tissue injury. This chapter describes soft tissue injuries and their optimal assessment and management by the multidisciplinary health care team throughout the trauma cycle.

Skin is an organ with great variety: It is thin and mobile in some parts, such as the eyelids, and thick and immobile in others, such as the back and soles of the feet. It overlies other soft tissues in some areas and various bony protuberances in others (e.g., the mandible, zygoma, and malleoli). Therefore the pattern and degree of injury vary. Injurious modalities may impart low, medium, or high amounts of energy to the soft tissue envelope, depending on the particular mechanism of injury (e.g., motor vehicle crash, animal or human bites, blunt assault, or ballistic penetrating trauma). The skin may be abraded, avulsed, amputated, lacerated, contused, punctured, crushed, or bitten. When the patient is seen at the hospital, the soft tissue envelope may have already developed complications such as necrotizing infection if a prolonged period elapsed from injury to rescue and hospitalization.

## SOFT TISSUE ANATOMY

### SKIN

Skin is the largest organ in the body, having the largest surface area of all the organs and accounting for 16% of body weight. Intact skin provides many functions that are essential to survival. It serves as a barrier to invasion by microorganisms and chemicals. Skin also prevents loss of proteins and assists with regulation of electrolytes and fluid. Intact skin retains body heat, yet cutaneous vasodilation and activation of sweat glands help cool the body. Finally, skin provides sensory feedback about pressure, thermoperception, proprioception, touch, and pain.

Skin is a composite of several elementary tissues, including (1) connective tissue (collagen, elastin); (2) epithelium, including secondary skin appendages such as sweat glands and hair follicles; (3) nerves, including sensory structures such as Meissner's and pacinian corpuscles; and (4) blood vessels (Figure 27-1). The skin consists of two layers, the epidermis and dermis. The epidermis, the external surface of the skin, is composed of keratinized squamous epithelial cells. These cells produce a protein keratin, which is the same protein in hair and nails. Thickness of the epidermis varies depending on the functional forces to which it is subjected. For instance, it is thickest on the soles of the feet and on the palms.

The epidermis consists of five layers of cells (Figure 27-2). First is the stratum basale, which is the germinative layer of the epidermis. It is from this layer that cells divide by mitosis and undergo maturational changes to go on to produce keratin. Next is the stratum spinosum layer, which contains cells in the process of growth and early keratin synthesis. Stratum granulosum, a granular layer 1 to 4 cells thick,<sup>1</sup> is next followed by the stratum lucidum, which is present only in thick skin such as on the palms or soles of the feet. Most superficial is the stratum corneum layer, which consists of nonviable flattened fused cells composed mainly of the fibrous protein keratin. This superficial layer constantly

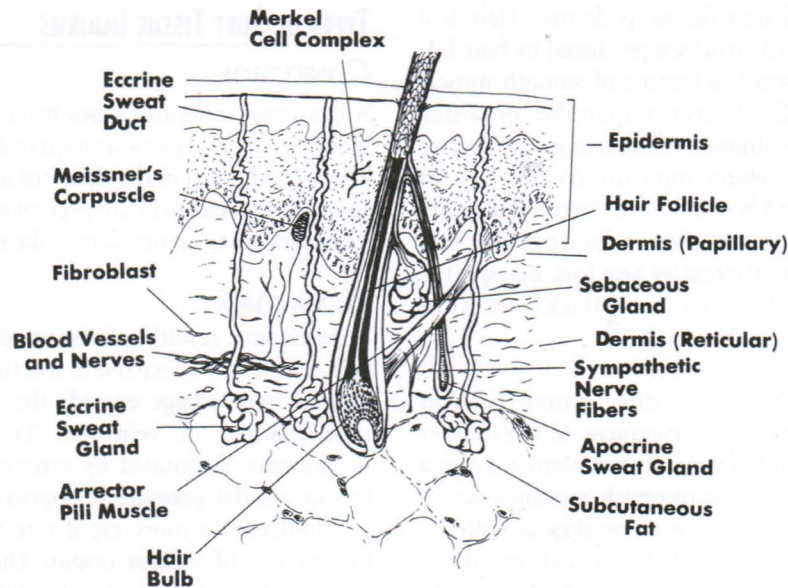


FIGURE 27-1 Schematic Vertical Cross-Section of Skin. (From Johnson TM, Nelson BR: Anatomy of the skin. In Baker SR, Swanson NA, editors: *Local flaps in facial reconstruction*, Chicago, 1995, Mosby, 4.)

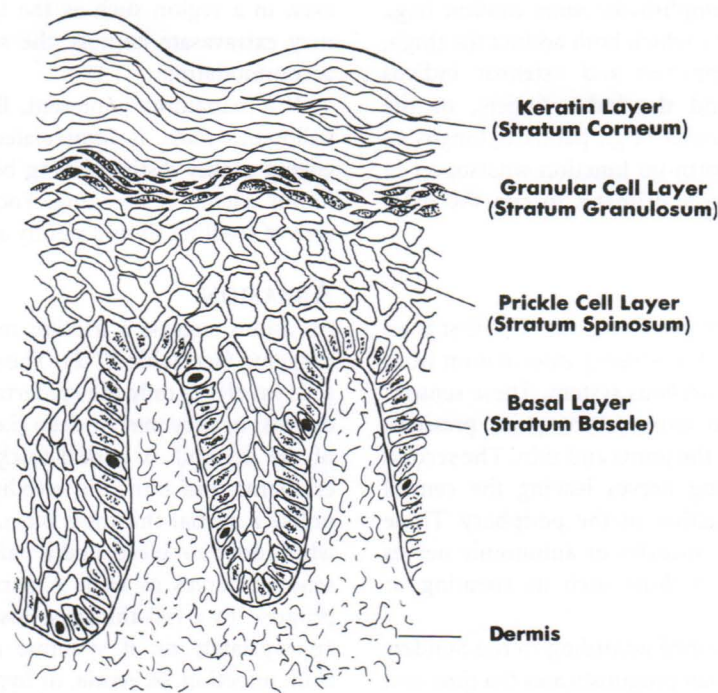


FIGURE 27-2 Layers of Epidermis. (From Johnson TM, Nelson BR: Anatomy of the skin. In Baker SR, Swanson NA, editors: *Local flaps in facial reconstruction*, Chicago, 1995, Mosby, 7.)

sheds. Melanin is also present in the epidermis and is elaborated by melanocytes, which migrate through and are scattered in the basal layers of the epidermis.

Immediately subjacent to the epidermis is the dermis, a highly vascular layer that contains many sensory receptors. The basement membrane zone connects the epidermis and dermis. This zone blocks passage of certain substances (e.g., chemicals) and provides mechanical support to the epidermis.<sup>1,2</sup> At the interface of the dermis and epidermis there are

rete ridges. These are interdigitations of the epidermis and dermis, which prevent the epidermis from sheering off. The most superficial layer of the dermis is the papillary dermis, which is highly vascular with fine interlaced collagen fibers. The main bulk of the dermis is in the reticular layer, which contains most of the collagen. The cells of the dermis are largely fibroblasts, which produce collagen, elastin, and ground substance.

Skin appendages such as hair follicles, sebaceous glands,

and sweat glands extend into the deep dermis. Hair is a highly modified keratinized structure produced by hair follicles. Associated with them is a bundle of smooth muscle cells called the arrector pili, which are responsible for raising hair and producing goose pimples. Sebaceous glands secrete an oily substance called sebum onto the hair surface to provide waterproofing and moisturizing. Sweat glands are coiled tubular glands that secrete a watery fluid onto the skin surface to cool the body by evaporative heat loss. Beneath the dermis lies subcutaneous tissue, a variable thick layer of fat.

MUSCLE

Another soft tissue is muscle, which directly underlies skin everywhere except at the bony protuberances. In this chapter the discussion is limited to the skeletal musculature. From a functional viewpoint, muscles accomplish motion—acting on bones across joints or acting directly on skin, as with the muscles of facial expression. Muscle has a high metabolic demand and is relatively intolerant of ischemia. Vascularity to muscle is immense, serving its higher metabolic demand. Although muscles provide important functions, some are expendable because of either redundancy in the system, whereby many muscles accomplish the same motion (e.g., gracilis and adductor magnus, which both adduct the thigh, or extensor digitorum communis and extensor indicis proprius, which both extend the index finger), or the vestigial nature of some muscles (e.g., palmaris longus or plantaris longus, which perform no function whatsoever in humans but are used by lower primates to cup the palm or sole).

NERVES

Nerves in the soft tissue serve two functions. The first is an afferent function, the retrieval of sensory information from the periphery to the central nervous system. These sensory nerves relay information on temperature, pain, pressure, position, and vibration from the joints and skin. The second function is efferent, signaling nerves leaving the central nervous system to execute action in the periphery. These motor nerves are directed to muscles or autonomic nerves that regulate involuntary functions such as sweating or vessel dilation.

Nerve injuries can be classified according to the Sunderland system (Table 27-1), which prognosticates the time and degree of functional recovery.<sup>3</sup> Extent of nerve damage is often unclear at the initial evaluation and can be surmised only by neurometric tests and serial examinations to evaluate functional progress.

TYPES OF SOFT TISSUE INJURIES

CONTUSION

A contusion or bruise arises from rupture of subcutaneous blood vessels and extravasation of erythrocytes (Table 27-2). There is no break in the skin, but discoloration or ecchymosis, swelling, and pain are present at the site of contusion. A hematoma may accumulate at the site of ecchymosis.

HEMATOMA

A hematoma, resulting from rupture of a deeper and larger vein or artery, will expand in soft tissues until pressure in the area of hemorrhage exceeds the pressure within the disrupted artery or vein (see Table 27-2). Thus arterial hematomas, elaborated by arteries under greater pressure (mean arterial pressure is approximately 80-100 mm Hg) accumulate at a more rapid rate and to a larger size than hematomas of venous origin. The size of the hematoma is also related to the capacitance of the tissues in which it forms. For instance, in the hand, where the tissues are not so distensible, the pressure will rise quickly as the skin starts to distend and tamponade the extravasation. However, in a region such as the thigh, several liters of blood may extravasate because the soft tissue envelope is more accommodating.

If a hematoma is present, fluid fluctuance or a doughy ballotable mass is appreciated on palpation. Postinjury edema makes distinguishing between hematoma and profound edema challenging. Focal ecchymosis overlying an area of swelling should signify a hematoma as well.

ABRASION

Abrasions suggest a friction mechanism of injury such as dragging (see Table 27-2). These injuries may be superficial (i.e., involving only the epidermis or partial thickness of the dermis) or they may be deep (i.e., violating the full thickness of the dermis). A partial-thickness abrasion demonstrates erythema and punctate bleeding and is painful. It is not unlike a partial-thickness burn. A full-thickness abrasion is white, does not bleed, and is painless because of injury to the sensory nerves as well. A partial-thickness abrasion may progress to a full-thickness loss of skin if it is not treated appropriately or, if systemic resuscitation is suboptimal, from infection, ischemia, or hypoxia.

Traumatic abrasions are often contaminated with debris implanted into the skin, resulting in traumatic tattooing.<sup>4</sup> Gravel or road debris may become imbedded, for instance, in a patient ejected during a motor vehicle crash. This

TABLE 27-1 The Sunderland Classification System for Nerve Injuries			
Grade	Structures Injured	Name	Prognosis
I	Loss of myelin sheath	Neurapraxia	Complete recovery in days to months
II	Neural death but intact sheath	Axonotmesis	Complete return in months
III	Neural and endoneurial injury		Mild/moderate reduction in function
IV and V	Disruption of all nerve structures	Neurotmesis	Marked reduction in function

TABLE 27-2 Summary of Traumatic Wounds

Type	Description	Mechanism of Injury	Assessment	Therapeutics	Complications
Contusion/ hematoma	An injury that does not involve the breaking of the skin. Characterized by swelling, pain, and discoloration. The rupture of small blood vessels causes extravasation of blood into the tissues, forming a hematoma.	Caused by blunt trauma.	Test for sensation and movement. Assess vascular involvement by measuring changes in the surface area of the bruise. Check for any underlying fractures.	Elevate the injured part and apply cold packs. Administer mild analgesics as required. May require up to 2-3 weeks for the hematoma to be reabsorbed.	Development of compartment syndrome, in which blood collects and increases pressure within the fascial compartment, compromising in the circulation and function of the affected area.
Crush injury	A composite injury involving two or more tissue types and graded severity of injury.	Incident involving high energy exchange such as a fall of significant distance or a motor vehicle crash in which a part of the body is run over and crushed.	Assess for size and anatomic location of crushed area. Check neurologic status and test for loss of function. Assess for tissue and blood loss and effect on underlying structures. Use invasive or noninvasive transcutaneous monitoring to detect increased compartment pressure (pressure exceeds diastolic arterial pressure).	Apply a pressure dressing, elevate, and cool. Treat open portions as described above. Surgical intervention may be required for serial debridement, fasciotomy, and fracture stabilization. Measure urine myoglobin when extensive muscle damage is present.	Complications include those of abrasions, avulsions, amputations, lacerations, and contusions. High risk of compartment syndrome. Amputation of crushed extremity may result.
Abrasion	A scraping or rubbing away of a layer or layers of the skin caused by friction with a hard object or surface. Abrasions vary in depth but are never deeper than the dermis.	Often caused by motorcycle crash or any incident in which the patient is dragged or slides across a rough surface.	Assess for size, depth, location, and degree of contamination. An abrasion covering a large amount of the body surface should raise concern for lost body fluids. Depth and number of exposed nerve endings affect the amount of pain experienced. Location affects limitation of movement, especially if the abrasion occurs over a joint. Dirt and debris are commonly embedded.	Local infiltration or topical application of anesthetic. Parenteral sedation for extensive abrasions. Meticulous cleansing by scrubbing with a saline- or surfactant cleanser-soaked sponge or surgical brush and copious irrigation. Do not use detergents because they produce additional pain. A needle, No. 11 surgical blade, or forceps may be required to remove embedded particles. Coat with antibiotic ointment and leave open or cover with nonadherent or occlusive dressing. Healing time varies with depth, location, and degree of contamination.	Direct sunlight may cause changes in skin pigmentation. "Traumatic tattooing," or the retention of foreign debris such as gunpowder, asphalt, and sand in the wound after healing, is characterized by a blue hue and a rough appearance.

Continued

TABLE 27-2 Summary of Traumatic Wounds — cont'd

Type	Description	Mechanism of Injury	Assessment	Therapeutics	Complications
Avulsion	A tearing away of tissue, resulting in full-thickness loss. Wound edges cannot be approximated. Degloving injuries, which result from shearing types of force, are one type of avulsion.	Caused when an extremity is cut by a meat slicer or saw or when an individual is thrown through the window in a motor vehicle crash.	Assess for amount of lost tissue, location, loss of function, and damage to underlying structures. The amount of tissue lost determines the course of treatment (e.g., grafting vs. revision and use of a flap). A large avulsion may result in fluid loss. Disability and disfigurement particularly occur when the avulsion involves the hand or face.	Thorough cleansing as described above. Control bleeding by direct pressure. Thorough irrigation with saline and early debridement of damaged tissue. Split-thickness grafting for closure when required. Complex avulsions may require use of a free flap placed with microvascular surgical techniques.	Disfigurement and loss of limb may result in changes in patient's body image and may affect vocation and avocations.
Amputation	An avulsion in which the affected limb is completely separated from the body	Caused when a digit or extremity is caught in a piece of equipment and is sheared off. Guillotine type of injury is caused when a digit or extremity is cleanly cut off by a power saw or similar tool.	As with avulsion, assess for amount of lost tissue, location, loss of function, and damage to underlying structures. In addition, the separated part must be assessed for its viability after transport.	Thorough cleansing as described above. Wrap amputated part in a dry, sterile dressing and place in a sterile plastic bag or container. Place wrapped part in an insulated cooler with ice. Do not freeze the amputated part. Properly managed, the part may be maintained for 6-12 hours before replantation.	Infection and hypertrophic scarring are the most frequent complications of amputations. Loss of viability or inability to replant the amputated part is related to mechanism of injury and warm ischemic time. Muscle in the amputated part is sensitive to ischemia and a large amount of muscle may have an adverse effect on the part's viability.
Laceration/incision	An open wound resulting from tearing or cutting of the skin. It is termed <i>superficial</i> if it involves only the dermis and epidermis and <i>deep</i> when it extends into the underlying tissues or structures.	Caused by rupture of the skin when struck by a blunt force, producing a torn, jagged wound; or a sharp object such as a shard of glass can cut the soft tissue.	Assess for damage to underlying structures and degree of contamination. Perform neurovascular checks to determine any sensory or motor deficits. Assess age of injury for degree of contamination and desiccation.	Thorough cleansing and irrigation, with hemostasis by pressure and elevation. Necrotic wound edges should be excised and edges approximated and closed with suture or skin tape. Use antibiotic ointment and nonadherent or occlusive dressing. Dressing should provide some pressure to reduce swelling and hematoma formation. Splints or casts are used when immobilization is required.	Sutures too tight or left in too long cause unsightly cross-hatching; sutures too loose cause wide scars. Improper approximation of the wound edges causes raised scars or tunnels that permit infection and hematoma formation. A loose dressing permits the wound to bleed and gaping to occur; a dressing applied too tight causes wound ischemia.

Puncture wound	A wound in which there is a small external opening in the skin but deep penetration of the underlying tissue.	Caused by the penetration of the skin by a sharp or pointed object. A high-pressure spray gun or similar equipment produces numerous punctures.	Assess for depth of penetration, degree of contamination, and any retained or injected foreign material. Appearance of surface injury may be benign. Assess for underlying tissue damage.	Soak the wound and examine the tract of the penetrating object. Remove any foreign bodies and irrigate the wound. Filling the wound space may be required for adequate healing.	Complications most frequently involve infection related to retained foreign material.
Mammalian bites	An animal or human bite causing puncture and a crushing wound by the teeth and jaws of the mammal and resulting in a grossly contaminated injury.	Caused by animal or human teeth and pressure from jaw force.	Determine the source of the bite and potential for infection. Assess wound's age, depth, and size and damage to underlying tissue.	Scrub and irrigate with povidone-iodine solution and apply cold pack. Bites more than 12 hours old should not have primary closure except in the face. Hand bites should be covered with a large bulky dressing. Plastic surgery may be required for facial bites. Antibiotic treatment is required in human and some animal bites. Tetanus and rabies prophylaxis may be needed.	Infection from microorganisms in the saliva. Human bites produce both gram-negative and gram-positive infections.

mechanism of injury is suggested by linear streaking within the abrasion.

### AVULSION

Avulsions result from stretching or tearing away of the soft tissues, creating a full-thickness loss (see Table 27-2). Unfortunately, the magnitude of an avulsion injury is often underestimated. Tissues that appear viable and salvageable today are simply not so 24 hours later. This scenario is often repeated every 24 hours, with progressive loss of tissue. The tissue that remains behind is thus significantly compromised and declares itself viable or not over 48 to 96 hours.

### LACERATION

Lacerations, compared with other soft tissue injuries, can appear to be a more elementary problem (see Table 27-2). Lacerations may be caused by sharp trauma such as glass or a knife wound. The adjacent area of crush and devitalization in these mechanisms may be small, approaching surgical incisions. These linear lacerations approximate well and have an optimal chance to heal. Facial lacerations that arise from blunt trauma generally occur along relaxed skin tension lines (normal skin creases), which are in areas of "skin fault lines," where skin is attenuated and susceptible to tearing<sup>5</sup> (Figure 27-3). This laceration pattern represents cleavage of the skin overlying the skeleton. If the laceration occurs at a right angle to the relaxed skin tension lines, healing generally takes longer and scarring is wider than if the laceration occurs within these lines.<sup>6,7</sup> Lacerations from

a blunt mechanism of injury are associated with larger margins of contused and compromised tissues. Often visible around the laceration is a halo of erythema or ecchymosis, indicating that the absolute zone of injury is larger than that of a laceration caused by a sharp object (e.g., a knife), and the relative zone of injury is quite large. Repair of this type of laceration is more challenging.

Lacerations that disrupt muscular tissues gap widely because of muscle contraction. Thus lacerations that divide muscles (e.g., across the full-thickness lip or eyelid) often give the appearance that tissue has been avulsed and is absent. By meticulously examining the functional elements, it can be ascertained that the tissues are present and can be reapproximated.

### PUNCTURE WOUND

Puncture wounds carry a heightened risk of infection (see Table 27-2). Although they do not cause vast soft tissue destruction or lacerations, puncture wounds can set up an aggressive infection because they deliver bacteria or foreign inoculum deep into the body. Puncture wounds should not be closed, so that any infections that may develop can exit. Animal bites are notorious causes of puncture wounds. A bite from a dog with large teeth often causes lacerations that have a lower likelihood of getting infected because the bacteria can work their way out. However, in contrast, because of their fine, needlelike teeth, cats can cause a deeper bacteria inoculum that seals over. Bacteria then flourishes and cannot egress, leading to a virulent infection.<sup>8,9</sup>

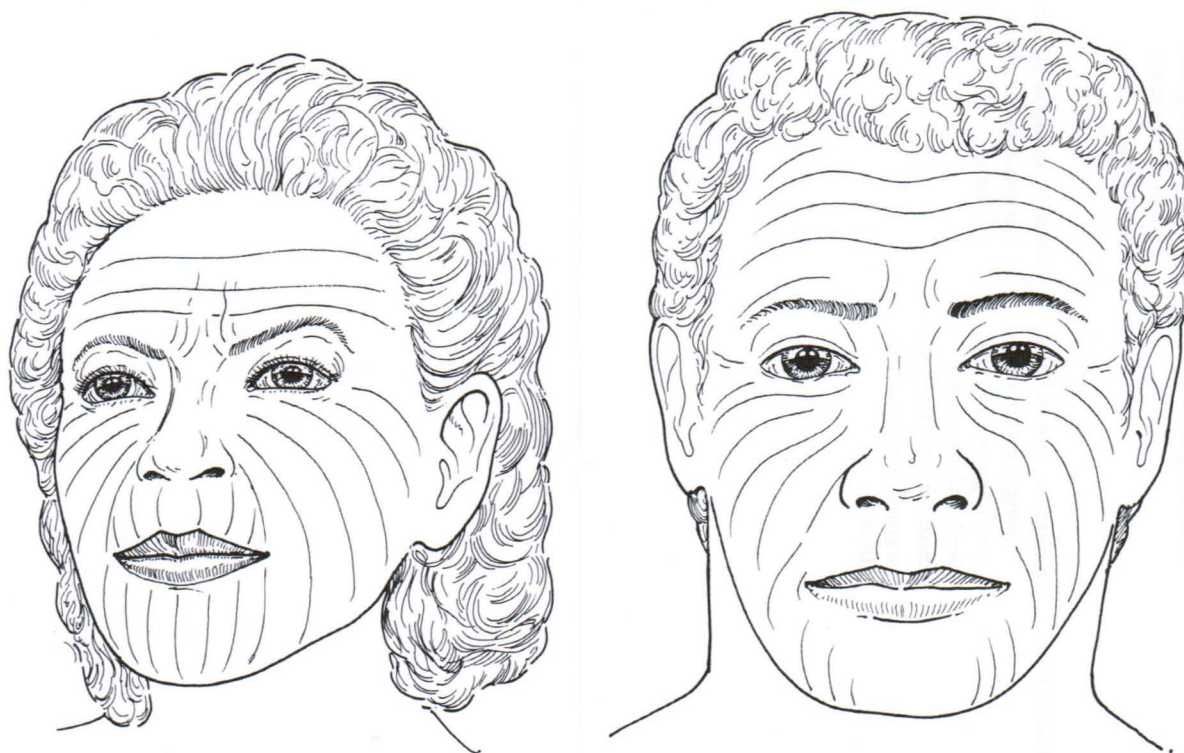


FIGURE 27-3 Relaxed Skin Tension lines. (From Cook TA, Brownlee RE: Rotation flaps. In Baker SR, Swanson NA, editors: *Local flaps in facial reconstruction*, Chicago, 1995, Mosby, 76.)

## ASSESSMENT OF SOFT TISSUE INJURY

On encountering the patient, the organ we cannot help but examine is the skin. Immediately, from seeing the tone of skin, the examiner can ascertain whether the patient is flushed and well oxygenated, blue and dusky from hypoxia, or pale and mottled from anemia or tissue hypoperfusion. From the turgor, indirect cues about the hydration and volume status of the patient can be ascertained. Wrinkles convey information regarding the age of the patient. From the temperature, as hands are laid on the patient, hypothermia, physiologic warmth, and febrile response are assessed.

### INJURY DATABASE

Information should be obtained from the prehospital care providers about the mechanism and environment of injury and treatment provided at the injury scene. Although external evidence of soft tissue injury may be present and obvious to the trauma team, information about the mechanism of injury may direct the practitioner to explore other less suspicious areas for soft tissue disruption. Any sustained pressure application over soft tissue and periods of hypoxia or hypotension in the prehospital phase should be noted because these factors can threaten the viability of soft tissues.

The health care team should also appreciate the time elapsed from the injury until hospital admission and definitive treatment of the wound. As this time interval increases, so does the likelihood of wound infection.<sup>9,10</sup> Decisions about wound closure and antibiotic prophylaxis may be based in part on this factor.<sup>8,9</sup>

In addition to the vectors of force directed and amount of kinetic energy delivered to the patient, the environment in which the injury occurred must be considered. Injuries sustained in environments with exposed soil (e.g., farms, construction sites) are likely to be highly contaminated with numerous pathogens, including gram-positive anaerobic bacteria (e.g., *Clostridia*). Wounds contaminated with certain species of *Clostridia* (e.g., *Clostridia perfringens*) can develop clostridial myonecrosis (gas gangrene) if provided an area of decreased oxidation-reduction potential (e.g., necrotic tissue, tissue lacking perfusion, hematoma, foreign body). Gas gangrene has a rapid and fulminating clinical course that can lead to tissue destruction, limb loss (sometimes within 24 to 48 hours), toxemia, and death.<sup>11</sup> Therefore, wounds acquired in a dirty or farm environment require aggressive, serial debridement at regular intervals.

Aquatic injuries are often contaminated with gram-negative bacteria. Brackish water in intertidal zones such as bays and estuaries is conducive to the proliferation of these organisms. Virulent bacteria from marine environments include *Vibrio*, *Aeromonas*, and *Mycobacterium* species. Wounds infected with these organisms require coverage with third-generation cephalosporins, quinolones, or other broad-spectrum antibiotics.

Industrial injuries, which deliver large loads or high pressure, can pose unique challenges. Chemical caustic agents used in industrial settings can penetrate skin. Mate-

rial data sheets from the site of the injury are important to obtain in order to evaluate the cytotoxic effects of these chemicals. High-pressure injection of these agents into subcutaneous tissues can lead to unsuspected wide dissemination of caustic agents underneath the skin. These wounds require aggressive debridement. In blunt trauma suffered in industrial settings, large loads, such as those typically manipulated by cranes or forklifts, are brought to bear on small areas such as the lower or upper extremities. This leads to large amounts of soft tissue devitalization and crush injuries. The patient often requires multimodality stabilization, including possible placement of an external fixator for fracture stabilization, control of hemorrhage with interventional radiologic or operative techniques, and surgical debridement of nonvital tissues.

### INITIAL ASSESSMENT PRIORITIES

Initial assessment and management priorities for trauma patients are to ensure a patent airway, adequate breathing, and sufficient circulation. Skin characteristics may provide clues about insufficient oxygenation, poor tissue perfusion, location of life-threatening injuries, and sources of hemorrhage, which are considered during the primary survey. However, a detailed soft tissue assessment is typically delayed until the ABCDE (airway, breathing, circulation, neurologic disability, exposure/environmental control) priorities of the trauma resuscitation protocol have been assessed and managed and the patient has been stabilized.<sup>12</sup>

### SOFT TISSUE ASSESSMENT

**INSPECTION AND PALPATION.** Starting in the head and neck region and proceeding downward, the soft tissue is evaluated carefully for injury. The patient should be disrobed completely to expose the entire skin surface. Care is taken to evaluate between all skin folds and beneath hair. The patient should be log-rolled to the side as soon as possible to permit thorough evaluation of the posterior aspect.

Location, size, and appearance of any wound or area of skin discoloration should be well documented in the medical record. It is important to note the amount, character, and odor of any wound exudate. Tissue swelling may be noted at or near the site of soft tissue injury, and the nurse should monitor the patient closely for any edema that impairs tissue perfusion or obstructs the airway. Extremity girth may be measured serially to detect increased soft tissue swelling. Any change in the appearance of a wound or wound drainage should be reported to the physician.

Soft tissue perfusion is evaluated by assessing capillary refill time, pulses, skin color, and temperature. Sluggish capillary refill time; absent or weak pulses; and pale, mottled, or bluish skin color are all symptoms of impaired tissue perfusion. When the skin is cool to touch, it signals the presence of systemic hypothermia or tissue hypoperfusion. Skin very warm to touch may provide evidence of underlying inflammation or systemic fever.

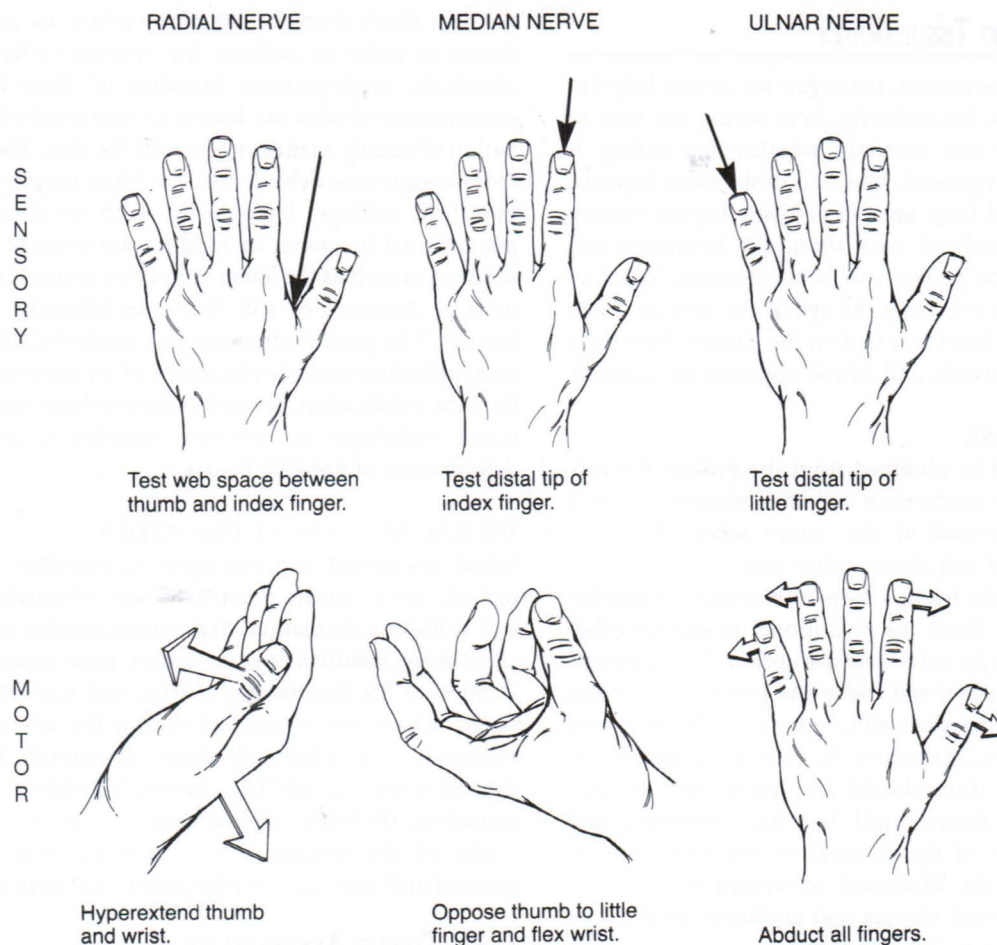


FIGURE 27-4 Upper Extremity Sensory-Motor Assessment.

When evaluating a wound, in addition to inspecting for erythema, purulence, and tenderness, the patient must be assessed for crepitus. Crepitus is produced by subcutaneous air or gas. Subcutaneous emphysema develops when air is trapped benignly along soft tissue planes or is being produced by an anaerobic organism (e.g., *C. perfringens*, coliforms, anaerobic streptococci, bacteroides).<sup>11</sup>

**NEUROMUSCULAR FUNCTION.** A neuromuscular examination is performed to discern the presence of muscle or nerve damage. In the alert and cooperative patient, a detailed motor and sensory examination, including assessment of the cranial nerves (see Chapter 19) and peripheral nerves distributed to the extremities, is performed (Figures 27-4 and 27-5). Sensation in other areas of the body should also be evaluated by determining if the patient can distinguish sharp versus dull stimulus in other sensory dermatomes. (Refer to Chapter 22 for an explanation of sensory assessment.)

Injuries to various regions of the body may prohibit certain components of the assessment from being carried out fully. For example, lower extremity fractures preclude obtaining a full motor function examination of the leg. Patients with an altered level of consciousness

are usually unable to reliably perform tests of motor function or sensation and require modifications to the neuromuscular examination. Examination of specific involuntary reflexes (e.g., pupillary light reflex, corneal reflex, gag reflex) evaluates some cranial nerve functions. (Refer to Chapter 19 for a thorough explanation of cranial nerve assessment.) In the comatose patient, motor function assessment is performed by examining the type and strength of patient movement in response to noxious stimuli. The only means of evaluating peripheral sensation is to observe responsiveness to noxious stimuli applied to the extremities.

Motor or sensory deficits should raise a signal of alarm not only for direct injury to the nerve but also for the possibility of limb-threatening compartment syndrome. After soft tissue injury, compartment syndrome occurs if bleeding and edema within a fascial compartment elevates the intracompartment pressure, resulting in compromised blood flow to the muscles and nerves of the compartment. (Refer to Chapter 26 for more information on compartment syndrome.) Diminution of sensation is the most reliable early diagnostic symptom of compartment syndrome.<sup>11</sup> Patient complaint of pain out of proportion to the injury and motor weakness may also be noted. Pulselessness is a

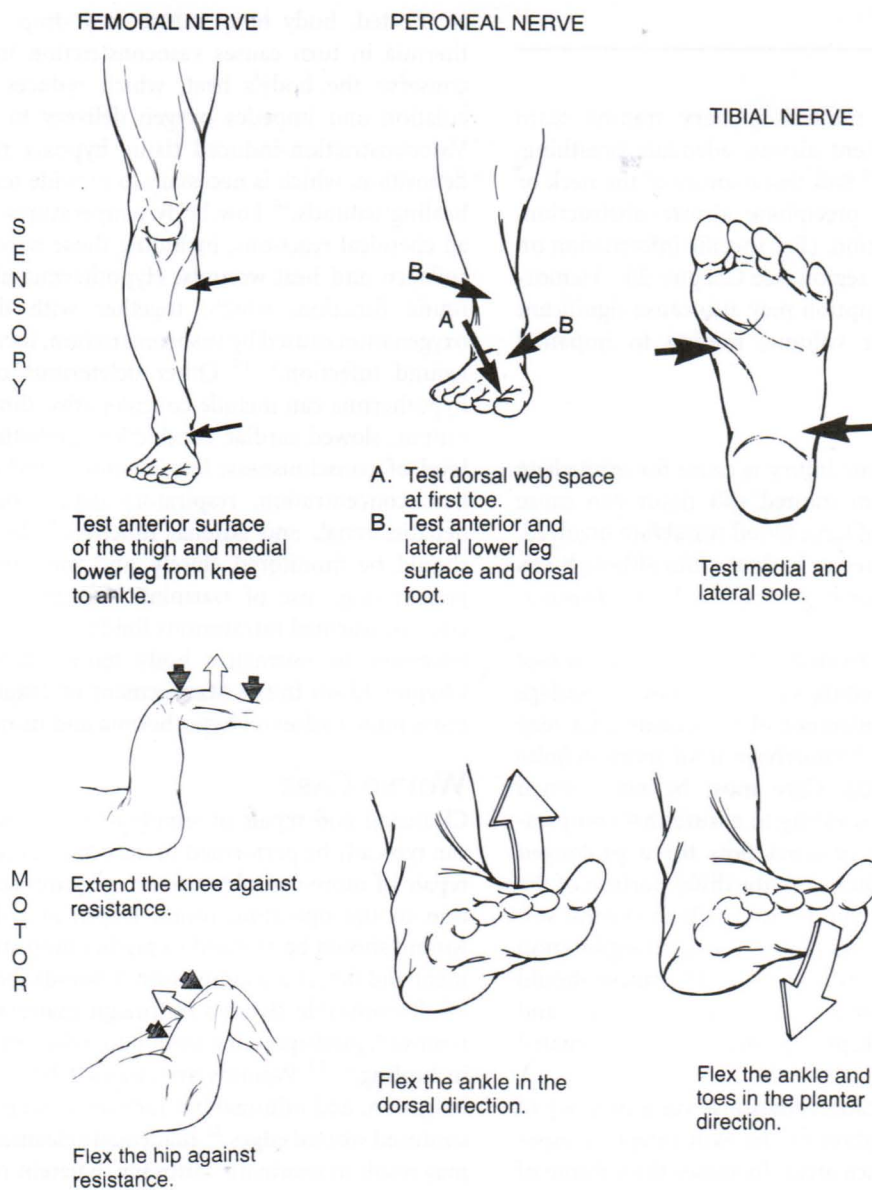


FIGURE 27-5 Lower Extremity Sensory-Motor Assessment.

very late finding, by which time tissue necrosis may have begun.<sup>11,13</sup>

**LABORATORY STUDIES.** A number of abnormal laboratory values may provide clues about underlying problems that require timely intervention. Low hemoglobin and hematocrit levels accompany substantial blood loss from soft tissue injury and may necessitate blood transfusion. Abnormal coagulation parameters require prompt correction to prevent excessive blood loss from soft tissue disruption. Persistent elevations of the white blood cell concentration may provide evidence of soft tissue infection. Elevation in the serum creatine phosphokinase (CPK) level or the presence of myoglobinuria implies muscle necrosis, which may result from development of compartment syndrome.<sup>14</sup>

**OTHER DIAGNOSTIC STUDIES.** Soft tissue damage often overlies other injuries such as fractures. For instance, periorbital ecchymosis (“black eyes” or “raccoon’s eyes”) is virtually pathognomonic for orbital, nasal, or basilar skull fractures. Findings of soft tissue disruption often trigger additional diagnostic studies to rule out or determine the extent of underlying injury.

Concern about the presence of an embedded foreign body may prompt additional diagnostic tests to confirm the presence, size and location of the object. Radiographs can usually detect foreign objects that are radiopaque (e.g., metal, gravel, glass) if they are large enough to be visualized.<sup>15,16</sup> A computed tomography (CT) scan may also be useful in locating a foreign body and determining what disruption the object caused to surrounding tissues.

## RESUSCITATION

### INITIAL PRIORITIES

First and foremost, the multidisciplinary trauma team focuses on ensuring a patent airway, adequate breathing, and sufficient circulation.<sup>12</sup> Soft tissue injury of the neck or maxillofacial region may precipitate airway obstruction, requiring immediate attention. (For specific information on injury to the maxillofacial region, see Chapter 20.) Hemorrhage from soft tissue disruption may also cause significant depletion of intravascular volume, leading to impaired circulation.

### CIRCULATION

Hemorrhage from soft tissue injury is cause for immediate concern. Hemorrhage from injured soft tissue can cause exsanguination, especially if large blood vessels are involved. Bleeding into the soft tissues or body cavities although less obvious than external hemorrhage, may also lead to hypovolemia and shock.

External hemorrhage is treated initially by application of direct pressure on the bleeding site.<sup>13</sup> A pressure bandage applied around the circumference of a bleeding area may effectively tamponade the hemorrhage until more definite treatment can be rendered. Care must be taken when applying a circumferential dressing to ensure that compression does not completely obstruct flow for a prolonged period, thereby causing ischemia to the distal portion of the affected body part. When compression fails to control soft tissue hemorrhage, the wound requires surgical exploration to clamp and ligate the bleeding vessel. The nurse should continuously monitor wound dressings and drainage, and the physician should be kept informed of the estimated blood loss.

Soft tissue injury also causes fluid loss via a number of other mechanisms. Disruption of the skin integrity, especially over large body surface areas, increases the volume of insensible fluid loss. Tissue injury can cause vascular damage and inflammation at and around the affected site, allowing fluid to extravasate out of the intravascular space and into the interstitium. Both these mechanisms contribute to depletion of the intravascular volume, which can lead to inadequate tissue perfusion.

Crystalloids, colloids, and, when appropriate, blood products are administered intravenously to restore adequate intravascular volume. The patient's hemodynamic parameters (e.g., heart rate, systemic blood pressure, central venous pressure) and indicators of tissue perfusion sufficiency (e.g., mentation, capillary refill time, urine output, acid-base balance, lactate levels) should be used to guide the appropriate volume of fluid therapy. If concern about persistent hemorrhage exists, serial evaluation of hemoglobin, hematocrit, and coagulation parameters may be prescribed.

### NORMOTHERMIA

Disruption of skin integrity allows loss of body heat through the skin opening. When a large area of the skin covering

is affected, body temperature may drop. Systemic hypothermia in turn causes vasoconstriction in an attempt to conserve the body's heat, which reduces peripheral circulation and impedes oxygen delivery to the tissues.<sup>17,18</sup> Vasoconstriction-induced tissue hypoxia reduces collagen deposition, which is necessary to provide tensile strength to healing wounds.<sup>18</sup> Low body temperatures also slow down all chemical reactions, including those needed to lay down collagen and heal wounds. Hypothermia also impairs immune function, which, together with decreased tissue oxygenation caused by vasoconstriction, increases the risk of wound infection.<sup>17-19</sup> Other deleterious consequences of hypothermia can include coagulopathy; diminished cardiac output; slowed cardiac conduction; arrhythmias; decreased level of consciousness; loss of motor and reflex function; hemoconcentration; respiratory depression; and reduced hepatic, renal, and adrenal function.<sup>20</sup> Body temperature should be monitored closely, and measures to warm the patient (e.g., use of warming blankets, heated ventilator circuits, warmed intravenous fluids) should be employed as necessary to normalize body temperature.<sup>12,20</sup> Refer to Chapter 13 on Initial Management of Traumatic Shock for more information on hypothermia and its management.

### WOUND CARE

Cleansing and repair of simple or minor soft tissue injury can typically be performed in the resuscitation area, whereas repair of more complex wounds requires surgical intervention in the operating room. Depth and direction of the wound should be assessed to predict deep structure involvement and detect contamination. Wounds should be cleansed of all nonviable tissue and foreign material, which, if not removed, predispose the wound to infection, causing a delay in healing.<sup>21-23</sup> Wounds are cleansed by scrubbing, pulsed irrigation, and minimal but judicious sharp debridement of contused wound edges.<sup>22</sup> Inadequate cleansing of the wound may result in traumatic tattooing, wherein road debris (e.g., gravel) is embedded into the dermis, making later excision impossible. Conservative debridement is indicated in those areas with little local tissue laxity, such as the distal nose, ears, eyelids, and vermilion of the lips. Superlative results are obtained when nonvital and compromised tissues are excised and the wound is closed primarily. Thus meticulous attention must be paid to closure and debridement at the time of repair; reliance should not be placed on later scar revision. The goal of complete excision of contused tissues is not always accomplishable because there may not be enough local tissue laxity to close the wound primarily if generous debridement is undertaken. In those situations, secondary scar revision is usually necessary. A layered repair then achieves an optimal result. Nurses should clarify with the physician specific care desired for wounds after closure or while awaiting closure.

Attention must be given to the soft tissue in contact with stabilization and immobilization devices applied in the field (i.e., backboard, cervical collar, traction, and splinting devices). These devices typically lack sufficient padding and

pose a substantial risk for skin breakdown if left on for an excessive time. The nurse should collaborate with the rest of the health care team to pursue removal of these devices in a timely fashion.

## PREVENTION OF INFECTION

Controversy surrounds the use of prophylactic antibiotics for traumatic wounds. Sufficient levels of antibiotics need to be present in the tissues at the time of injury to optimize their effectiveness, which is impossible in the case of unanticipated trauma. When given after injury, antibiotic effectiveness is significantly diminished.<sup>8,17</sup> Needless antibiotic use for minor decontaminated wounds is discouraged to decrease the risk of creating antibiotic-resistant infections. Administration of antibiotics may be considered when a clean wound cannot be created by debridement. Antibiotics may also be considered if there is major soft tissue disruption, an associated open injury to a joint or bone, or the patient has a premorbid history of immunosuppression or cardiac valvular disease.<sup>8</sup> Prophylactic antibiotics must be present in high concentrations before and during wound closure or surgical manipulation of the wound to be effective.<sup>8,17</sup> Consideration of the environment where the injury occurred is important when selecting an antibiotic so that the drug selected covers likely pathogens. Prophylactic antibiotics are not a substitute for thorough wound debridement, meticulous wound care, and adequate tissue perfusion and oxygenation to prevent infection.<sup>8,17,19,24</sup>

When the patient is admitted with an established infection of the soft tissue caused by delay in hospitalization after injury or demonstrates onset of infection during the resuscitation phase, the infection should be treated with thorough wound debridement and irrigation and appropriate antibiotics. Early onset of a rapidly progressing wound infection should trigger an investigation to rule out clostridial or group A streptococcal infection, which can develop within hours of injury.<sup>25</sup> Cultures of the wound bed and exudate provide essential information about the causative organism and which antibiotic would be most appropriate.

Adult patients who have not had a tetanus shot within the past 10 years should receive a tetanus toxoid booster. In severely contaminated wounds that are tetanus prone and for patients who have an inadequate immunization history, tetanus immune globulin should also be administered for passive immunization. The tetanus immune globulin should be administered at a different site than the tetanus toxoid so that the antibody and antigen do not neutralize each other in the same injection site.<sup>8</sup>

## PAIN MANAGEMENT

Soft tissue injury may cause a significant amount of patient discomfort. Pain can have an adverse effect on wound healing because it stimulates catecholamine release, causing vasoconstriction and reduced peripheral tissue perfusion and oxygen delivery.<sup>17,26</sup> The nurse should carefully assess and document the location and severity of the patient's pain. Once a baseline neurologic assessment is performed, pre-

scribed pain medication should be administered and the patient's pain relief should be evaluated. Increasing pain should not be dismissed or simply medicated with increasing doses of analgesics; instead the cause of the increasing pain should be investigated. Refer to Chapter 17 for more extensive information on pain management.

## OPERATIVE PHASE

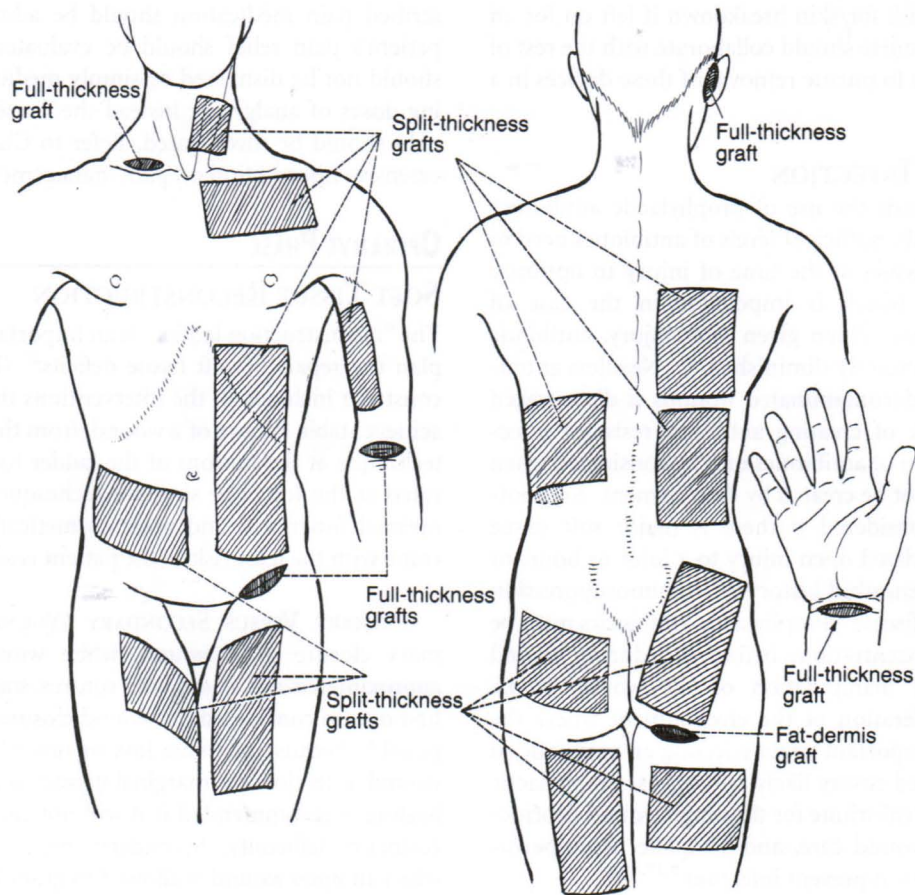
### SOFT TISSUE RECONSTRUCTION

The "reconstruction ladder" is an important concept used to plan the repair of soft tissue deficits<sup>27</sup> (Figure 27-6). This construct includes all the interventions that may be used to achieve stable closure of a wound, from the most elementary technique at the bottom of the ladder to the most complicated at the top. The simplest technique that achieves the optimal functional and most cosmetically acceptable outcome with the least risk to the patient is selected.<sup>8,27,28</sup>

**PRIMARY VERSUS SECONDARY WOUND CLOSURE.** Primary closure of a wound, when wound edges can be approximated and closed with sutures, staples, or tape, is the first option considered for wound closure. When that is not possible because of tissue loss or not advisable because of wound infection or marginal tissue, secondary intention healing is recommended if it will not cause a functional or cosmetic deformity. Secondary intention healing occurs when an open wound is allowed to granulate and eventually close on its own. Small wounds in cosmetically unimportant areas such as the abdomen, trunk, or legs can be treated with wet-to-dry saline dressings and allowed to granulate. Open management of wounds in the head and neck region is not advocated because of the unique vascularity, ability to heal, and social significance of this region.<sup>8</sup> Primary closure of facial wounds is preferred, with serial debridements and closures staged at 24 and 48 hours.

Free flap
Distant flap
Regional flap
Local flap
Skin graft
Primary closure

**FIGURE 27-6 The Reconstructive Ladder.** The simplest wound closure technique that achieves the most desirable outcome with the least risk to the patient is selected. Simplest techniques start at the bottom of the ladder.



**FIGURE 27-7 Available Donor Sites for Skin Grafts.** (From Rudolph R, Ballantyne DL. Skin grafts. In McCarthy JG, editor: *Plastic surgery*, vol 1, *General principles*, Philadelphia, 1990, WB Saunders, 227.)

As neovascularization (formation of new blood vessels) occurs, a healthy wound bed will take on a beefy red appearance. The wound bed reepithelializes from the edges because the epithelial cells lose their contact inhibition and start to proliferate, creeping into the wound. If a wound bed has full-thickness skin loss and the skin is allowed to granulate, the new skin will lack a dermis and will have only a friable epidermis layer. Over the ensuing months, as greater collagen deposition occurs, the wound will regain up to 80% of its original strength.<sup>28</sup> This is cosmetically inferior and does not provide durable coverage. Secondary closure is recommended only for small wounds because a large wound may take months, even up to 1 year, to fully reepithelialize. This time to full healing may be further prolonged in the nutritionally compromised patient.<sup>17,26</sup>

The Sure-Closure device (Life Medical Sciences, Princeton, NJ) may be used to stretch and increase the surface area of skin to enable wound closure. This skin-stretching device recruits the viscoelastic properties of skin, namely “creep” and “stress relaxation,” using incremental traction. Wound edges initially not coapted can be stretched together within minutes to days with this device simply by turning a screw.<sup>29,30</sup> Application of elastics is another method used to dynamically recruit the viscoelastic properties of skin to achieve wound closure.

**SPLIT-THICKNESS SKIN GRAFTS.** Wounds that have a healthy, viable bed with sufficient blood supply and that are too large to granulate over can be managed with skin grafts. Skin grafts can be split thickness or full thickness. Split-thickness skin grafts contain less tissue requiring revascularization and have greater capillary exposure, making them more likely to tolerate a recipient site with some vascular compromise. In contrast, full-thickness skin grafts require a recipient site that has a rich vascular supply.<sup>31</sup>

A split-thickness skin graft is harvested, when possible, from relatively hidden areas, using a dermatome device (Figures 27-7 and 27-8). Skin is harvested through the mid-dermis so that the split-thickness skin graft includes partial-thickness dermis and all of the epidermis (Figure 27-9). Typical thickness for a harvested split-thickness skin graft is .0012 of an inch to .0015 of an inch. When the skin graft is applied to an appropriately healthy wound bed, it should “take” to the bed. The skin graft may be meshed (meaning cut into a lattice format) to allow the skin graft to expand (Figure 27-10). Meshing is done to achieve closure of a large wound when donor sites are at a premium, for instance in a severely burned patient with only a few donor sites available. Mesh ratios typically used for skin grafts are 1.5:1 or 3:1, which respectively provide 150% or 300% coverage. An additional reason for meshing is to allow fluid collections beneath the graft to escape through the mesh

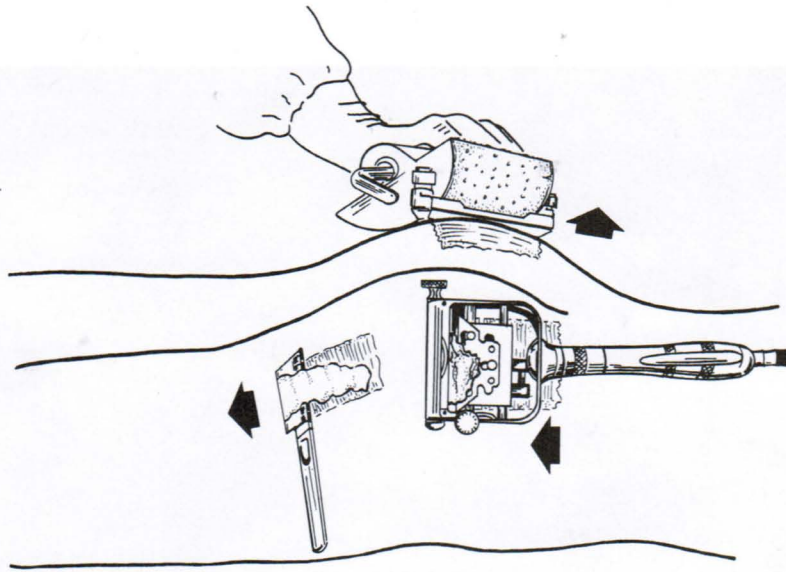


FIGURE 27-8 Split-thickness skin grafts should be harvested from relatively hidden areas such as the thighs and buttocks whenever possible. Drum dermatomes are generally used across a convex surface whereas power dermatomes and hand-held knives are best used longitudinally on an extremity. (From Rudolph R, Ballantyne DL. Skin grafts. In McCarthy JG, editor: *Plastic surgery*, vol 1, *General principles*, Philadelphia, 1990, WB Saunders, 227.)

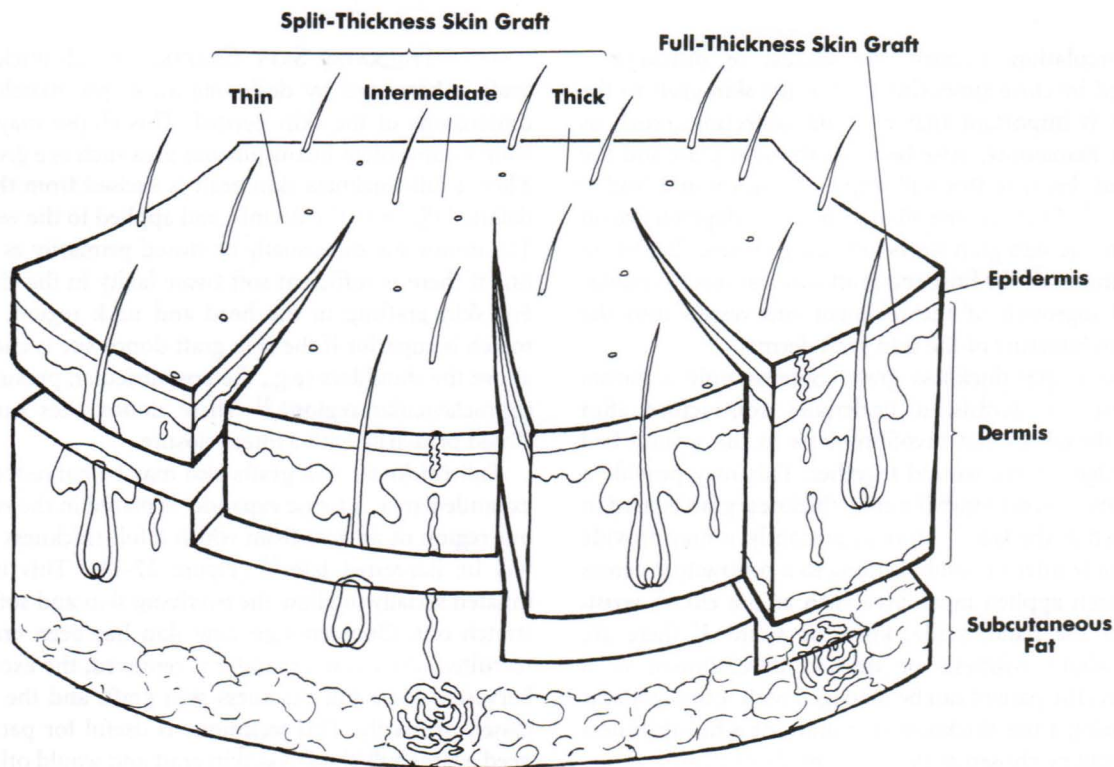


FIGURE 27-9 Relationship of Skin Graft Type to Thickness of Skin. (From Glogan RG, Haas AF: Skin grafts. In Baker SR, Swanson NA, editors: *Local flaps in facial reconstruction*, Chicago, 1995, Mosby, 249.)

openings. Whereas meshed skin grafts can give greater coverage and are more resistant to the development of a seroma (localized collection of serous fluid within tissue), hematoma, or even infection beneath the graft, they give a cosmetically inferior result because the mesh pattern is retained.

Skin graft “take” is a process that lasts several days. For the first 36 hours or so, a skin graft lives off imbibition. Imbibition, from the Latin for drinking, is essentially osmosis, whereby nutrients diffuse from a healthy wound bed to the skin graft and cellular waste products diffuse from the skin graft into the wound bed, where they are taken away

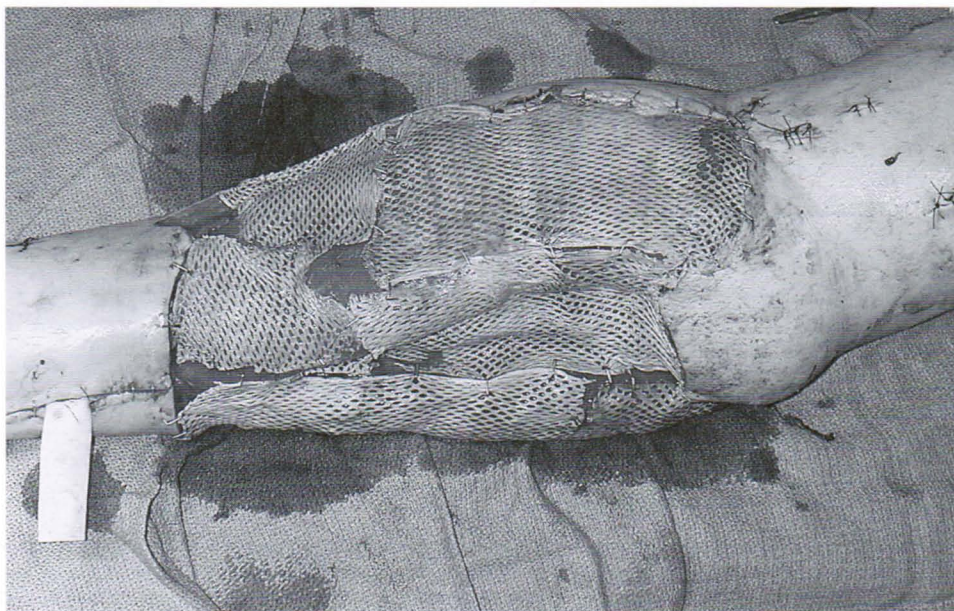


FIGURE 27-10 Meshed Skin Graft Applied to the Leg.

by the circulation. Because the success of diffusion is determined by close approximation of the skin graft to the wound, it is important that no fluid collections, such as seroma or hematoma, arise between the skin graft and the wound bed, because this will impair diffusion and lead to graft loss.<sup>27,31</sup> After the first 36 to 48 hours of dependence on imbibition, the skin graft starts to undergo revascularization by anastomoses of the host and graft vasculatures (inosculation) and ingrowth of the recipient site vessels into the capillary architecture of the skin graft dermis.<sup>32</sup>

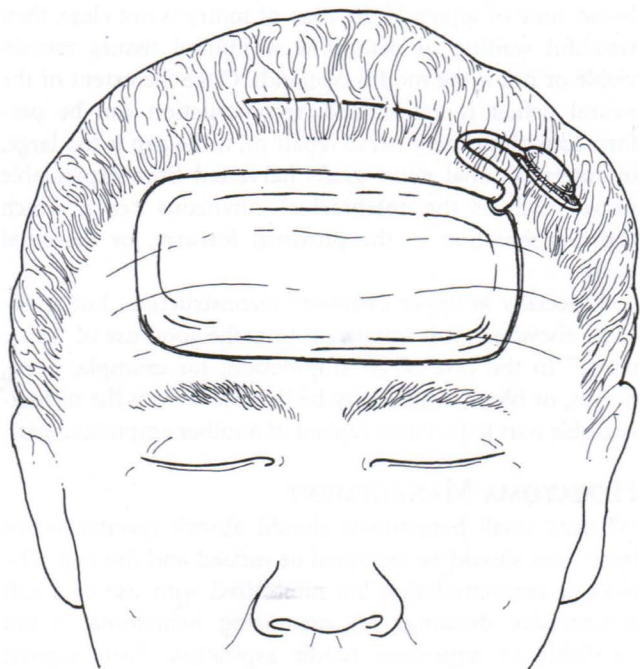
Because a split-thickness graft contains only a partial amount of the dermis, it undergoes contracture after healing. Fibroblasts and myofibroblasts in the wound bed pull the edges of the wound together. This may provide a cosmetically inferior result if a split-thickness graft is used in an area such as the face.<sup>31</sup> More importantly, it may provide a functionally inferior result, leading to a contracture across a joint, when applied in an area such as the elbow, wrist, dorsum of the hand, axilla, knee, or ankle. If there are concerns about cosmesis or delayed development of a contracture, the patient can be managed with secondary scar revision using a full-thickness skin graft, or a full-thickness skin graft can be chosen as the initial mode of treatment.

Meanwhile, the donor site for a split-thickness skin graft harvest heals spontaneously because only a partial thickness of the dermis has been harvested. Skin appendages such as sweat glands and hair follicles contain epithelial nests, which start to bud and volcano out of their roots in the deep dermis. These epithelial nests spread across the injured surface until they meet the epithelial cells from the adjacent accessory skin appendage. A harvest site reepithelializes within 7 to 10 days.

**FULL-THICKNESS SKIN GRAFTS.** A full-thickness skin graft is harvested by designing an ellipse matched to the dimensions of the skin needed. This ellipse may be taken from a convenient inconspicuous area such as a groin crease. Then a full-thickness skin graft is excised from this ellipse, defatted down to the dermis, and applied to the wound bed. The donor site can usually be closed primarily as a straight line if there is sufficient soft tissue laxity in the chosen site. For skin grafting in the head and neck region, the color match is superior if the skin graft donor site is chosen from above the shoulders (e.g., the postauricular, preauricular, or supraclavicular region).<sup>31</sup> These donor sites can also be closed primarily with a linear closure.

Full-thickness skin grafts also may be harvested from an expanded area. A tissue expander is placed in the subcutaneous region of an area from which a full-thickness skin graft will be harvested later<sup>33</sup> (Figure 27-11). This implant is inflated serially to allow the overlying skin and soft tissue to stretch out. Once enough new skin has been created and recruited, the tissue expander is removed, the excess skin is harvested for a full-thickness skin graft, and the wound is closed primarily. This technique is useful for patients who need a large full-thickness skin graft and would otherwise be unable to undergo primary closure of the donor site if so much skin was excised. Alternatively, a full-thickness skin graft can be excised from a donor area that can then be closed itself with a split-thickness skin graft from yet another area.

**OTHER TYPES OF SKIN REPLACEMENT.** Additional biologic, synthetic, and biosynthetic skin replacement products are available. A number of grafts are available for temporary



**FIGURE 27-11. Large Rectangular Tissue Expander is Placed Beneath Frontalis Muscle Through Small Incision Above Hair-line.** (From Argenta LC: Controlled tissue expansion in facial reconstruction. In Baker SR, Swanson NA, editors: *Local flaps in facial reconstruction*, Chicago, 1995, Mosby, 528.)

ily covering a wound to prevent infection, excessive discomfort, body fluid evaporation, and heat loss.<sup>27</sup> Xenografts, harvested from pigs, and allografts, from human cadavers, are temporary grafts used primarily for burns.<sup>27,34,35</sup> Several synthetic dermal coverings have also been developed (e.g., Integra, Alloderm).<sup>34,36</sup> Epithelial cells have been cultured and grafted onto wounds with limited success. Cultured cells have also been used to develop epidermal grafts, dermal replacements, and composite grafts, containing dermal and epidermal components.<sup>34,37</sup> Although most of these skin replacement products have been used and tested primarily with burns, they may have a role in healing selected traumatic soft tissue injuries. New developments in skin replacement offer tremendous hope for other more effective alternatives to manage soft tissue injury.

**FLAPS.** Wounds that are not suitable for primary closure, secondary intention healing, or closure with skin grafts may require a flap for closure. Flaps are required when vital structures such as nerves, blood vessels, tendons, or bones without any overlying vascular tissue are exposed. Because these vital structures need more padding than can be provided by a skin graft or they are no longer vascularized to support a skin graft (e.g., tendon without paratenon or bone without periosteum), they must be covered with tissue that brings its own vascularity—namely, a flap.

Flaps may be composed of various tissues. Skin and subcutaneous tissue flaps are called fasciocutaneous flaps. Flaps may also incorporate muscle, in which case they are

termed musculocutaneous flaps. Complex composite tissues including bone, muscle, skin, and fat may also be moved as a flap. These are termed osseomusculocutaneous or osseofasciocutaneous free flaps. Examples of these include the free fibula, in which a vascularized piece of the fibular bone from the lower extremity is transferred, using microsurgical techniques, to reconstruct other bony losses such as the humerus, radius, or mandible. This technique of free tissue transfer with complex composite tissue flaps represents the dawning of a new era of plastic surgery reconstruction. With advances in tissue engineering, a flap can essentially be designed and engineered in a remote location to replace detailed areas such as half of a face or portions of an arm. Once mature, the flap can be transported by microsurgical techniques to the desired location.

The type of flap used is based in part on patient habitus. In a slightly obese patient for whom bulk is needed to fill the wound bed, a fasciocutaneous flap may be well suited. However, when a pliable surface is required, such as on the face or the back of the hand, a thinner flap composed solely of fasciocutaneous tissues and underlying fat may be harvested from the back or abdomen of an appropriately thin patient.

Abundant vascularity is tremendously beneficial when muscles are used as flaps to provide soft tissue coverage and to ablate dead space in traumatic wounds. Because of augmented vascularity, a muscle flap that has been rotated to cover an exposed critical area can deliver polymorphonucleocytes, mononuclear lineage cells, and lymphocytes in the inflammatory phase of wound healing to enhance removal of debris and combat infection. Animal studies show that muscle flaps demonstrate greater resistance to infection than fasciocutaneous (skin) flaps when subjected to the same bacterial inoculum.<sup>38-40</sup> Enhanced vascularity provides greater traffic of erythrocytes and increases the oxygen tension in a wound, which expedites wound healing. Muscle flaps, compared with skin flaps, are more pliable and conform to complex surfaces and curves in three-dimensional space to ablate dead space and enhance final contour.

Flaps may be obtained from local or remote tissue. A flap from local tissue involves leaving the blood supply intact and rotating, transposing, or tunneling locally available tissue into the wound.<sup>41</sup> For example, the rectus abdominis muscle can be harvested and flipped from the abdomen to cover an exposed femoral artery and vein in the groin. Another example is a nasal labial flap, whereby vascularized tissue from the nasolabial crease is raised with its intact blood supply from the angular artery and vein and tunneled to cover defects on the sides of the nose.

When local tissues are not available, such as in the distal third of the leg where there is a paucity of soft tissue covering, remote tissues must be used for closure. An example of remote tissue use includes an across-leg flap, where tissue from one leg is bridged to the opposite injured leg. After 2 to 3 weeks, when the injured leg has adopted tissue from the healthy leg, the soft tissue is divided between

the two legs. Remote tissue is also used when a hand stripped of a soft tissue covering is "tucked in" to the abdomen for 2 to 3 weeks until it has revascularized and incorporated soft tissue from the abdomen.

Over the past 20 to 30 years the microsurgical technique for placement of free flaps has largely supplanted other techniques using remote tissue. A free flap does not initially retain its own vascularity. Using microsurgical techniques, the flap is harvested from its donor site (e.g., the rectus abdominis muscle is harvested from the abdomen or the latissimus dorsi muscle is harvested from the back) with its artery and vein intact. Then, under an operating microscope, the artery and vein are anastomosed with extremely fine suture (8.0 or 9.0 nylon) to suitable blood vessels in the region. This muscle flap now is revascularized because it is connected to a regional blood vessel. Large studies show that microsurgical techniques have a 95% to 98% success rate.<sup>42,43</sup>

Appropriate flap selection requires attention not only to the needs of the recipient site but also to minimizing undesirable alterations at the donor site. When possible, donor sites are located in inconspicuous areas and leave little scarring to minimize undesirable appearance of the site. Preservation of function at the donor site is probably a more important consideration when selecting tissues (i.e., muscle, nerves, and blood vessels) for transfer. Preferably tissues selected for transfer should be expendable or cause minimal functional loss at the donor site.<sup>44</sup>

**ADDITIONAL SOFT TISSUE REPAIR CONSIDERATIONS.** Consideration always needs to be given to involvement of underlying structures when establishing a plan for soft tissue repair. For example, injury of the lacrimal apparatus may accompany inner eyelid lacerations, or parotid duct injury may be present beneath trauma to the cheek. These underlying structures may require surgical repair in addition to the surface laceration.

Thorough description of repairs and reconstruction done to remedy motor deficits remains beyond the scope of this chapter but is mentioned to increase awareness. Motor defects may be corrected by repairing, grafting, or transplanting nerves, tendons, and muscles. For example, cranial nerve VII (the facial nerve), which innervates all the muscles of facial expression, can be reconstructed by (1) nerve grafts from the contralateral uninjured facial nerve to the intact muscles or (2) transplanting muscles and nerves from the back (latissimus dorsi and thoracodorsal nerve) or thigh (gracilis muscle and obturator nerve branch). Motor defects in the upper extremity, where precision is of the utmost concern, can similarly be reconstructed by (1) nerve grafts (e.g., using the sural nerve, which supplies sensation to the lateral foot); (2) tendon transfers, whereby expendable muscles are rerouted and reconnected so that they assume functions of the critical muscles that have been irretrievably traumatized; or (3) muscle transplantation (free flaps) using muscle such as the gracilis.

Neural deficits may be corrected immediately if the wound is not contaminated and is not associated with a

broad zone of injury. If the zone of injury is not clear, then watchful waiting to determine if injured tissues remain viable or not is the *modus operandi*. Once the extent of the neural deficit is determined, reconstruction can be performed with primary nerve repair or, if the gap is too large, by interpositional nerve grafts harvested from expendable nerves such as the antebrachial cutaneous nerve, which supplies sensation to the proximal forearm, or the sural nerve.

Especially in upper extremity reconstruction, but applicable elsewhere, it is important to make good use of "spare parts." In the case of an amputation, for example, bone, nerves, or blood vessels may be harvested from the nonsalvageable part to facilitate replant of another amputated part.

## HEMATOMA MANAGEMENT

Whereas small hematomas should absorb spontaneously, large ones should be aspirated or incised and drained. The risks of reaccumulation are minimized with use of a soft compressive dressing. An organizing hematoma is not amenable to large-bore needle aspiration. Early reports indicate that a liposuction cannula can be used to successfully remove a hematoma.<sup>45</sup> Large hematomas left in situ have a risk of getting infected or causing pressure necrosis of surrounding tissues.

## CRITICAL CARE PHASE

Management during the critical care phase focuses on promoting graft and flap survival; optimizing wound healing; and preventing, recognizing, and appropriately treating potential complications. Maintenance of airway patency, breathing, and circulation, which still may be threatened in this phase, continues to be critical not only for the survival of the patient but also to ensure sufficient supply of oxygen-rich blood to damaged soft tissues. Adequate perfusion and oxygen supply to wounded tissue is extremely important for healing and resistance to infection.<sup>17,26</sup> In addition to adequate tissue perfusion and oxygenation, sufficient nutrition, balance of fluid and electrolytes, and avoidance of infection are also important for wound healing.<sup>17,22,26</sup> Meticulous wound assessment and care are essential to achieve optimal outcomes from soft tissue injury.

## TISSUE PERFUSION

Adequate tissue perfusion depends in large part on ample intravascular volume and sufficient blood pressure to drive blood into the tissues. Hypovolemia eventually causes hypotension, but initially the body compensates for decreased intravascular volume by shunting blood from the periphery to more vital organs to sustain adequate blood pressure. Therefore it is essential that adequate intravascular fluid volume be maintained to promote tissue perfusion.<sup>26</sup> The nurse should closely monitor the patient's hemodynamic parameters (e.g., heart rate, blood pressure, central venous pressure, pulmonary artery pressures) and tissue perfusion indicators (e.g., capillary refill time, urine output, mentation, lactate levels, acid-base balance, gastric intramu-

cosal pH) for evidence of hypovolemia or compromised tissue perfusion. Abnormal findings should be reported promptly to the physician so that appropriate therapy can be rendered to replete intravascular volume and improve blood flow to the tissues. Once adequate intravascular fluid volume is provided, vasoactive or inotropic agents may be considered to support the patient's blood pressure and improve oxygen delivery. Normal blood pressure in the setting of vasopressor use (e.g., epinephrine, norepinephrine) can also lead to peripheral vasoconstriction and reduced perfusion so that blood is shunted to the vital organs.<sup>17</sup> Patients with a flaps or skin grafts, where perfusion is dependent on the peripheral vasculature, are particularly intolerant of hypotension, hypovolemia, and vasopressor use because circulation to the flap or graft may be compromised. The plastic surgeon of record must be informed immediately if vasopressors are being used in a patient with flaps. Caution must also be taken when administering sedation, analgesics, diuretics, or other agents that may reduce blood pressure, which could be deleterious to flap survival and wound outcome.

Maintaining systemic normothermia and pain control remain important during the critical care phase to avoid vasoconstrictive-induced tissue hypoxia.<sup>17,26</sup> Body temperature should be monitored frequently, and warming interventions should be employed if hypothermia becomes evident. Likewise, the presence of pain should be regularly evaluated and treated with prescribed analgesics to achieve patient comfort.

Anticoagulants are typically used to keep the vascular anastomosis patent in a free flap. Agents commonly prescribed by microsurgeons include aspirin, heparin, warfarin, or dextran. Because the microvascular anastomosis usually reendothelializes within 5 days, anticoagulants are used for 3 to 5 days to prevent occlusion. During this time the nurse should closely monitor coagulation studies to ensure appropriate levels, employ bleeding precautions, and frequently assess the flap site for evidence of inadequate perfusion.

## TISSUE OXYGENATION

Maintaining peripheral perfusion with well-oxygenated blood optimizes oxygen delivery to the healing tissues. The patient's oxygenation status must be monitored closely with a device such as a pulse oximeter so that hypoxia can be readily detected and remedied. Supplemental oxygen is administered to increase the partial pressure of dissolved oxygen in the blood and thus deliver more oxygen to a healing wound. Data suggest that oxygen supplementation, even in a patient with normal arterial oxygen saturation at room air, is beneficial.<sup>46</sup> Adequate tissue oxygenation reduces wound infection, hastens collagen synthesis, and accelerates the rate of healing.<sup>17,19,24,26,46</sup>

If the pectoralis major muscle from the chest wall or the rectus abdominis from the abdomen is used for a flap, splinting during respiration as a result of pain on the side of the flap donor site may cause atelectasis. This complication can cause or exacerbate problems with the oxygenation status of the patient. It is essential that pain be controlled so

that the patient can fully participate in deep breathing exercises to prevent or resolve the atelectasis.

Regardless of the modality used for wound closure, hyperbaric oxygen may have a role in fostering healing of soft tissue injury. Hyperbaric oxygen may accelerate the clinical course of wound healing by increasing oxygen tension in wound beds, which prevents certain adverse inflammatory reactions, reduces tissue ischemia, protects from reperfusion injury, promotes neoangiogenesis and collagen production, and acts against infection.<sup>47-51</sup> Hyperbaric oxygenation acts against bacteria by inhibiting toxin formation of certain anaerobes, directly killing the anaerobic organisms and enhancing the activity of polymorphonuclear leukocytes to expedite bacterial clearance.<sup>48,51,52</sup>

## WOUND CARE

Astute assessment of wounds at regularly scheduled intervals is essential to evaluate progression of healing and to detect onset of potential complications (e.g., infection, tissue necrosis). Size and depth of the wound should be measured and recorded at least daily. Wound appearance, including color, odor, approximation of closed wound edges, and drainage characteristics, are also noted. Specific assessment parameters evaluated with grafts and flaps must also be monitored meticulously (as described later in this chapter).

Abrasions, incision lines, and wounds should be cleaned as prescribed to remove exudate and nonviable tissue. Occasionally a thin layer of antibiotic ointment (e.g., bacitracin) is prescribed for application after wound or incision cleansing to help prevent infection.<sup>53</sup> Because most antibiotic ointments are irritative to the eyes, ophthalmic antibiotic ointments are generally ordered for patients with head and neck wounds so that if they enter into the eye, no harm is done. After cleansing, an incision may be left open to air or a prescribed wound dressing is applied. Numerous wound-dressing products are now available, and the wound characteristics should determine the best dressing for optimal wound healing.<sup>54</sup> An effective dressing should protect the wound and create an environment that promotes wound healing. It is desirable to have a dressing that maintains a moist but not macerated wound surface and allows surrounding tissues to remain dry.<sup>8,54,55</sup> Pain at the wound site is likely to increase during dressing changes and irrigations, necessitating administration of analgesics or sedatives before the procedure.

Factors that may compromise a skin graft include hematoma or seroma formation beneath the graft, shear factors, desiccation, and infection.<sup>27,31</sup> If a hematoma or seroma develops, it can raise the skin graft off the wound bed, thus cutting off its nutrient supply, which the skin graft obtains initially by diffusion. Nurses should remain vigilant for evidence of a fluid collection beneath the graft and, if present, should notify the physician immediately. A hematoma or seroma must be evacuated to allow the skin graft to "take." Shear forces can also disrupt the skin graft and prevent its initial adherence to the wound bed. Thus the patient's skin graft site must be immobilized appropriately and protected with a dressing or splint. It is important not to

rub the graft site while repositioning or providing other care to the patient. It is also important to keep the grafted area elevated when possible to minimize edema at the site.<sup>27</sup> Because skin grafts may dry out, a dressing is applied with mineral oil, saline, or oxychlorosene sodium (Clorpectin). Many surgeons, particularly in burn units, recommend wet downs of the skin grafts. This involves pouring 30 ml of oxychlorosene onto the dressings placed over a skin graft. Oxychlorosene is a potent antimicrobial that protects the skin graft from bacterial degradation, in addition to preventing graft desiccation in the early phase. Early after placement, when a skin graft has not yet revascularized, it is susceptible to infection because it is essentially dead tissue and consequently a great medium for bacteria. Care must be taken to avoid contamination of the graft site and to monitor closely for evidence of infection during this period.

After 5 days, when the skin graft has "taken," it changes from pale to pink as capillary buds from the wound bed reach and join the dermal vascular architecture. Seven to ten days

after grafting, the patient begins application of a topical antimicrobial lubricant, such as bacitracin, to the skin-grafted area to help prevent infection as the site continues to reepithelize through its small raw surfaces. Two weeks after grafting, the patient starts to apply regular skin emollients such as vitamin E oil or cocoa butter to keep the skin graft lubricated because it contains no functional sebaceous glands.<sup>31</sup>

Skin grafts require frequent assessment of color, which should be pink once the graft has taken<sup>27,31</sup> (Table 27-3). Next in order of importance during assessment, turgor of the site is evaluated. Evidence of excessive edema or bulging may indicate the presence of fluid collection beneath the graft. The graft should be warm to touch, and drainage from the site should appear unremarkable. Grafts should adhere to the wound. If a skin graft appears to be falling off the wound or if any other abnormal findings are evident, the physician should be notified immediately.

Condition of the skin graft donor site should also be assessed regularly to determine if healing is occurring or if

**TABLE 27-3 Plastic Surgery Skin Grafts and Flaps**

	<b>Skin Grafts</b>	<b>Local Flaps/Rotational Flaps</b>	<b>Free Flaps</b>
<b>Description</b>	Transfer of full- or partial-thickness skin for wound coverage; requires an intact vascular bed	Transfer of local skin or muscle tissue, maintaining the native blood supply	Transfer of distant skin, muscle, or bone tissue with microscopic reconnection of the blood supply
<b>Most Important Issues</b>	Type of dressing to avoid graft displacement from wound bed and bacterial overgrowth	Checking flap viability via color, edema, turgor, and temperature Checking native blood supply via Doppler not usually required Nothing compressing graft; dressing should be loose and moist	Checking flap viability via color, edema, turgor, and temperature Assessing Doppler arterial and venous signals (critical) Nothing compressing graft; dressing should be loose and moist
<b>Mobility with Leg Grafts*</b>	POD 1-4: OOB to chair/wheelchair with leg up unless otherwise specified POD 5 (if interstices are epithelized): Dangle 5 minutes BID POD 6 (if tolerated POD 5 dangling): Dangle once for 10 minutes Continue to dangle leg once/day increasing dangle time 5 minutes/session as tolerated	POD 3-4: OOB to chair/wheelchair with leg up unless otherwise specified POD 5-6 (if interstices are epithelized): Dangle 5 minutes BID POD 6-7 (if tolerated 5 minute BID dangle): Dangle once for 10 minutes Continue to dangle leg once/day increasing dangle time 5 minutes/session as tolerated	POD 6: OOB to chair/wheelchair with leg up unless otherwise specified POD 6-7 (with interstices epithelized): Dangle 5 minutes BID Stop if there is excessive pain POD 7-8 (if tolerated 5 minute BID dangle): Dangle once for 10 minutes Continue to dangle leg once/day increasing dangle time 5 minutes/session as tolerated
<b>Diet and Medication</b>		No caffeine, nicotine, or vasoconstrictive drugs If dopamine, epinephrine, norepinephrine, or other vasoactive drugs are required, notify plastic surgeon	No caffeine, nicotine, or vasoconstrictive drugs If dopamine, epinephrine, norepinephrine, or other vasoactive drugs are required, notify plastic surgeon

Modified from an unpublished table developed by Gena Stanek and Bradley Robertson.

POD, Postoperative day; OOB, Out of bed; BID, Twice a day.

\*This is a sample protocol. Preferences for when and how to get the patient OOB or dangle the extremity with a graft or flap vary between institutions and among surgeons and should consider the individual patient needs.

*Continued*

any complications (e.g., infection) are present. Petroleum jelly gauze dressings applied to the split-thickness skin graft harvest site intraoperatively should be allowed to dry and spontaneously fall off the site. Another way to manage the donor site for a split-thickness skin graft is using a closed technique, whereby a semipermeable occlusive dressing

(e.g., Opsite) is placed over the site. This technique decreases pain and provides a moist environment that shortens healing time.<sup>31</sup>

Flaps require greater and closer monitoring than skin grafts because they are vascularized viable tissues that bring their own blood supply. Local or rotational flaps should be

**TABLE 27-3 Plastic Surgery Skin Grafts and Flaps—cont'd**

	<b>Skin Grafts</b>	<b>Local Flaps/Rotational Flaps</b>	<b>Free Flaps</b>
Room Temperature Standard	To the patient's comfort	Avoid cold temperature	Avoid cold temperature
Assessment	In order of importance:	In order of importance:	In order of importance:
Parameters	color (pink)	color (pink)	color (pink)
	edema/flap turgor	edema/flap turgor	edema/flap turgor
	temperature	temperature	temperature
	drainage	drainage	drainage
		flap "sweat" (open muscle should look moist)	flap "sweat" (open muscle should look moist)
		Doppler (not usually required)	Doppler—listen to both arterial and venous signals (nurse must know exact location to check signal)
Frequency of Checks (as Designated by Physician)	Every 8 to 12 hours.	Every 4 hour checks of above parameters	Every 30 minutes for first 4 hours Every hour from 4-24 hours Every 2-4 hours for next 24 hours
When to Call Physician with a Concern	Graft discoloration Fluid collection noted beneath graft Appearance of graft falling off the wound Any other abnormal change from baseline graft condition	Acute changes in vital signs, especially hypotension Any change from baseline flap condition Infection/sepsis	Acute changes in vital signs, especially hypotension Any change from baseline flap condition Infection/sepsis Difficulty obtaining Doppler signal Venous problems (swelling, purple color; classic reason for losing flap is the result of venous outflow problems at site of anastomosis) Arterial problems (graft shrinkage, pale color) (Flaps can be salvaged 40% of the time within the first 72 hours postop if insult identified and surgical intervention obtained within 2 hours)
Communication on Patient Transfer	RN to RN transfer should include status of skin graft and any special care	On patient transfer, attending/fellow should review necessary monitoring parameters with RN and write specific orders addressing required parameters and frequency of monitoring RN to RN transfer should include the same specifics related to appropriate graft care	On patient transfer, attending/fellow should review necessary monitoring parameters with RN and write specific orders addressing required parameters and frequency of monitoring RN to RN transfer should include the same specifics related to appropriate graft care

assessed every 4 hours to evaluate the flap color, pulse, edema, turgor, temperature, drainage, and moisture (see Table 27-3). The flap should appear pink and moist (flap sweat) and should have a palpable or audible pulse. Flap sweat is cellular exudate, which is absent in the presence of flap necrosis. There should be no excessive edema or atrophy of the flap, and drainage from the site should be unremarkable. Skin graft adherence to the flap is also noted because early nonadherence is a sensitive indicator of poor flap condition. Local flaps may become ischemic from arterial insufficiency or congested from venous insufficiency caused by postoperative edema or kinking of blood vessels that perfuse the flap. Hematoma formation beneath the flap may also compromise flap perfusion by compressing the vascular pedicle. The patency of the lower pressure venous circuit is particularly threatened. Any evidence of flap ischemia must be reported immediately to the physician. If such a complication develops, the patient may have to return to the operating room to evacuate any hematoma or to reposition the flap so that the vascular pedicle is unkinked or no longer under tension.

Free flaps require extremely close monitoring, particularly for onset of vascular thrombosis, the most common cause of flap failure (see Table 27-3). Early recognition and communication to the surgeon of symptoms pathognomonic of vascular thrombosis is important so that corrective interventions (e.g., operative flap revision) can be initiated to attempt salvage of the compromised flap.<sup>42</sup> If the reconstructed artery supplying perfusion to the flap clots off, the flap becomes pale, loses its turgor, and fails to make flap sweat. In addition to these symptoms, the flap becomes cool to the touch compared with normal body temperature. It takes on a limp appearance, and the overlying skin graft is no longer adherent. If the venous anastomosis clots off, venous blood backs up into the flap, creating venous congestion; the flap becomes swollen and takes on a deep blue hue. The exact locations to evaluate venous and arterial Doppler signals should be marked clearly or well communicated between care providers. Doppler signal monitoring has only a limited role in flap assessment. Loss of an arterial Doppler signal signifies arterial occlusion; however, the presence of a Doppler signal does not pacify the surgeon when the clinical appearance of the flap is not satisfactory.

Other techniques for monitoring the condition of free flaps are available and are regularly used in some institutions. Implantable Doppler probes and probes to monitor tissue oxygenation are available. Transcutaneous oxygen tension ( $P_{TCO_2}$ ) monitoring can alert the nurse if perfusion is inadequate ( $P_{TCO_2}$  below 20 mm Hg). A rapid decline in  $P_{TCO_2}$  below 20 mm Hg that is unresponsive to increased supplemental oxygen suggests occlusion of the artery supplying the flap.<sup>27</sup> Measures of tissue pH also provide a reliable index of flap perfusion. A sustained decline in tissue pH signals vascular occlusion. An arterial occlusion causes a more rapid drop in tissue pH than venous occlusion.<sup>27</sup> Because ischemic muscle loses its contractility, evaluation of muscle contraction in response to applied electrical

stimulation also provides information about muscle flap perfusion. Photophethmography uses an infrared light to measure pulsatile changes in blood flow of the free flap. Pulse oximetry can effectively monitor oxygen saturation in digital free flaps. A decline in oxygen saturation below 85% suggests venous occlusion, and a loss of pulsatile flow indicates arterial obstruction.<sup>27</sup> Although these monitoring techniques may prove to be helpful adjuncts in evaluating flaps, there is agreement that physical assessment of the flap remains the best method for determining flap condition. Adverse clinical findings should never be ignored, even if adjunctive monitoring parameters are normal.

Manipulation and external compression of any flap must be avoided to prevent impairment of perfusion or injury to the tissue. When caring for a patient with a flap in the head and neck region, the nurse must ensure that tracheostomy ties are not secured too tight and that no face mask elastic band is placed around the neck. These bands can occlude the artery or vein that is perfusing the flap. Other intravenous lines, tubings, monitoring wires, cables, and bed linens also should be kept away from the flap site to prevent external compression. The patient needs to be reminded not to touch the flap. If the patient is uncooperative, restraints may be needed. Dressings should be kept moist and applied loosely to the flap site. Any drains placed around the flap should be emptied regularly to prevent excessive pressure beneath the flap.

Positioning a patient with a flap should be carried out with the intention of minimizing postoperative edema, promoting venous outflow, and avoiding interference with arterial supply. The extremity with a flap should be elevated to promote venous return as long as arterial flow is not impaired.<sup>27</sup> Patients with a flap in the head or neck region should have the head of the bed elevated to expedite venous drainage from the flap. The surgeon typically indicates how to position the flapped area (e.g., whether the patient's head is to be kept neutral, to the left side, or to the right side). It is important to position the patient as prescribed to avoid putting the vascular pedicle or anastomosed vessels under tension or kinking them. Splints may be used to help immobilize an area with a flap. When positioning the patient, care must be taken to prevent compression of the flap. Positioning restrictions should be posted clearly so that all health care providers caring for the patient can readily visualize them.

Early intervention with medicinal leeches may effectively reduce postoperative venous congestion that can impair flap perfusion and threaten flap survival.<sup>56,57</sup> Leeches applied directly to the flap consume blood until full and then detach spontaneously. Because leech saliva has anticoagulant properties, the bite wound continues to ooze blood even after the leech has detached, further reducing flap engorgement.<sup>56,57</sup>

In addition to preventing systemic hypothermia that might threaten flap perfusion, the flap itself should be protected from exposure to cold. The room should be kept warm, and cool air from an air-conditioning vent should not be directed onto the wound. Sometimes the surgeon

prescribes an air-warming device to be placed loosely around the flap to encourage blood flow to the area.

## PREVENTION OF INFECTION

Prevention of infection is paramount for successful wound healing and graft or flap survival.<sup>21,22,40</sup> Measures to prevent wound contamination, such as frequent hand washing and sterile dressing changes, must be used regularly by health care team members. Close assessment for evidence of local wound infection, as evidenced by erythema, purulent drainage, or malodor at the site, should be performed with each dressing change. Wound infection can also cause systemic symptoms, such as fever and increased white blood cell count, and should always be considered when performing a fever workup.

Antibiotics to treat contaminated wounds or identified wound infections should be administered as prescribed. Debridement of necrotic tissue remains important because antibiotics cannot perfuse nonviable tissue to effectively reduce or eliminate pathogens harbored there.<sup>17,22</sup> Abrasions may be treated with topical antimicrobials. Just as in burn management, bacitracin provides some antimicrobial coverage but not deep penetration into an eschar. Silver sulfadiazine (Silvadene) provides broader coverage and is more effective in managing a larger partial-thickness abrasive injury. Leukopenia is a potential side effect of silver sulfadiazine use, so blood counts should be monitored in patients receiving this drug. Mafenide acetate cream (Sulfamylon) provides even broader coverage and is particularly useful over cartilaginous injuries such as abrasions of the ear or nose.<sup>58</sup>

## NUTRITION

Adequate nutrition is imperative for optimal healing of soft tissue injuries. Intake of adequate protein, carbohydrates, fats, vitamins, and minerals is essential.<sup>17,26,59</sup> Referred to Chapter 16 for a more in-depth review of metabolic and nutritional management. A registered dietitian can be consulted to determine the patient's individualized nutritional needs.

## INTERMEDIATE AND REHABILITATION PHASES

Hospitalization may be prolonged for the patient with soft tissue injury because of associated injuries, onset of complications, or need for repeated surgical intervention to repair the injured site. During the intermediate and rehabilitation phases of trauma care, the focus continues to be on optimizing conditions for wound healing and prevention of complications that may impair the healing process. More intense focus on increasing the patient's independence and preparation for discharge occurs. In addition to the physical healing of the wound, the psychologic impact of the injury also requires care.

## CONTINUED WOUND CARE

Wound healing may require a lengthy period of time, depending on the severity of the wound, the condition of the patient, and the presence or absence of factors that

promote wound healing. Wound care should continue to be provided as prescribed. Measures that foster perfusion and oxygen delivery to the wound site and prevent infection remain imperative as healing continues.

Subatmospheric pressure, applied with a specialized sponge dressing that attaches to a vacuum-assisted closure (VAC) device (Kinetic Concepts Inc., San Antonio, Texas), may be used on open wounds to assist with wound healing and closure. This device removes interstitial fluid from the wound, which improves localized blood flow and decreases local inflammatory mediators that may inhibit granulation tissue formation. These improvements in the local wound environment increase the rate of granulation tissue formation and accelerate wound healing.<sup>60-63</sup> Exposure to negative pressure also encourages wound contracture.<sup>61</sup> Nurses working with this device need to ensure that the wound dressing remains occlusive to retain the vacuum effect and should know how to troubleshoot the system.

Caffeine, a vasoconstrictive agent, must be avoided in the diet of a patient with a flap. Smoking is forbidden outright because of its deleterious effect on wound healing and also because of the explosive hazards it presents if oxygen is in use. Even a nicotine patch, which is often applied to patients who smoke to prevent cravings, can be deleterious because it delivers nicotine, a powerful vasoconstrictive agent that compromises peripheral tissue perfusion.<sup>17,27</sup>

## INCREASED MOBILITY AND SELF-CARE

Once the skin graft or flap of the lower extremity has taken, the leg needs to be dangled by a physical therapist (sample dangling protocol in Table 27-3). Procedures for how and when to mobilize the leg with a graft or flap can vary according to the physician or institution preference or patient-specific requirements. The surgeon specifies when the patient can get out of bed to a chair with the leg elevated. On the postoperative day prescribed the extremity can be dangled cautiously using the following procedure: A compressive dressing is applied to the lower extremity over the graft or flap, and the lower extremity is allowed to dangle off the side of the bed for 5 minutes. At 5 minutes the leg is elevated, the dressing is taken down, and the graft or flap is evaluated. The graft or flap site may take on a bluish hue as it develops venous congestion when dependent because its venous drainage system has not matured completely. Once the patient is returned to the recumbent position and the leg is elevated, the bluish hue resolves and the pinkish vascular color returns. Dangling an extremity with a graft or flap acclimates the graft to its new position and to its relative venous insufficiency. A graft or flap that becomes venous congested from dangling for too long may necrose, just as a venous stasis ulcer necroses in patients with insufficiency in their native tissue. Once the graft or flap is able to tolerate longer periods of dependent positioning, the length of time the leg can dangle can be increased as prescribed by the plastic surgeon.

Wounds, grafts, and flaps may restrict movement during the healing phase. A physical therapist should be consulted to assist the patient in movement after activity is permitted

by the plastic surgeon. Prescribed range-of-motion exercises as tolerated by the patient can be initiated. Range-of-motion exercises are particularly beneficial when a wound, graft, or flap extends over a joint. The condition of the wound should be monitored closely as movement is increased to detect any adverse effects on the healing process. An occupational therapist can help to establish alternative means of accomplishing activities of daily living while the soft tissue is healing and grafts and flaps are immobilized.

### ALTERED BODY IMAGE

After a soft tissue injury has healed, patients literally carry battle scars. In the past a scar was worn proudly as a symbol of chivalry, heraldry, or bravery. In modern society an obvious scar may be perceived as a symbol of a criminal or violent past. This can lead to stereotyping, resulting in fewer employment opportunities, and social outcasting. Although patients' reactions to soft tissue injury vary, soft tissue wounds can significantly affect self-esteem, role performance, and interpersonal relationships. Individuals often respond to such alterations in body image by grieving, and some experience depression.<sup>64</sup>

Nurses need to be sensitive to the patient's psychologic responses to injury and should implement strategies that assist patients in dealing with their altered body image. Patients should be encouraged to ask questions and ventilate feelings about their injury. They should be allowed to visualize their wound as desired.<sup>27</sup> Nurses should demonstrate an accepting and positive attitude when caring for the wound, taking care not to send negative nonverbal messages.<sup>64</sup> Choices about personal care (e.g., when to get out of bed or bathe) should be offered when possible to increase the patient's sense of control. Reinforcing the patient's positive attributes and accomplishments can help foster self-worth. Consultation with a crisis counselor or psychiatric liaison may assist the patient and family in coping with the injury and altered body image. Refer to Chapter 18 for more in-depth content on the psychologic aspects of trauma care.

Sudden changes in body image can cause anxiety, which may trigger use of defense mechanisms such as denial, withdrawal, repression, suppression, avoidance, and regression.<sup>64</sup> Desire for isolation from others and refusal of treatment for the wound may become evident. Discussion about feelings that foster these behaviors should be encouraged. Prescribed analgesics and anxiolytics should be provided as needed during dressing changes. Only desired visitors should be allowed to see the patient, and no one should force the patient into unwanted social interactions. A supportive significant other may prove helpful in reducing anxiety and apprehension about the wound and socialization.

### REINTEGRATION INTO THE COMMUNITY

Ultimately the goal is to reintegrate the traumatized patient back into society. Wound healing usually continues for some time after the patient's hospital discharge, necessitating

continued care of the wound and of the psychologic aspects of the injury while at home. Clear, comprehensive patient and family education and assurance of adequate home health resources foster successful reintegration back into society after soft tissue injury.

### PATIENT AND FAMILY EDUCATION

Patients and their families should be kept apprised by the surgeon of the anticipated course for wound healing and likely outcomes. This information can be reiterated and reinforced by the nursing staff. The patient should be encouraged to ask questions and solicit information. The Internet is a new medium for gaining information and also misinformation. Patients and families should be directed to a reputable site for information on wound care, such as the American Society of Plastic Surgeons web site ([www.plasticsurgery.org](http://www.plasticsurgery.org)). This learning process is also important for concerned family members who must make decisions in proxy for a disabled patient. Gaining knowledge and information can be empowering and helps decrease fears of uncertainty.

Care of the wound should be demonstrated for the patient and family. Then the individual who will be performing the wound care after discharge should demonstrate the procedure to validate accurate learning. Patients and family members should be instructed to wash their hands frequently and avoid touching the wound. For several months after reepithelialization the skin graft harvest site requires twice-daily external lubrication with emollients such as vitamin E oil or cocoa butter because the sebaceous glands have been transected and fail to provide normal lubrication to the skin. In some patients, because of the depth of harvest, sebaceous glands may never regain function.

Patients should also be instructed to avoid exposure of wounds, incisions, grafts, and flaps to direct sunlight and ultraviolet rays. The wound may develop hyperpigmentation if exposed to the sun.<sup>31</sup> If sunlight exposure is anticipated, the wound should be covered or strong sunscreen should be applied.

Measures for fostering graft and flap survival that were initiated in the hospital setting must be taught to the patient and family so that they are continued after hospital discharge. The interventions include avoiding caffeine in the diet, not smoking, preventing compression or manipulation of the graft or flap site, restricting movement or positioning as prescribed, elevating the affected area, and avoiding extreme cold. The patient should practice the range-of-motion exercises prescribed by the surgeon with the physical therapy staff before discharge. The importance of maintaining a healthy diet to foster wound healing should also be emphasized.

Patients and families also require education on potential wound healing complications and their symptoms, such as wound infection or impaired wound healing. Symptoms of graft or flap failure must also be well described to patients. Other long-term wound healing complications, described later in this chapter, should

also be discussed with the patient and their family. The patient and family need to have a clear understanding of what actions should be taken if complications become evident.

Adaptation and psychologic adjustment to soft tissue injury and its subsequent scarring may take several weeks to months. Patients and families should be informed that depression, altered mood, increased anxiety, and nightmares or flashbacks about the injury event are common reactions to traumatic injury.<sup>64</sup> Referral to a counselor or therapy group may be suggested if these symptoms become evident or problematic.

## HOME HEALTH CARE RESOURCES

Home health care resources may be necessary if extensive dressing changes are required, intravenous antibiotics are continued, or the condition of a graft or flap requires follow-up evaluation. The home health nurse can assist with the dressing changes or at least confirm that the patient or family member is performing them correctly. The nurse should ensure that sufficient supplies and necessary home health resources are available before discharge from the hospital.

## POTENTIAL FOR LONG-TERM WOUND HEALING COMPLICATIONS

**SCARS AND KELOIDS.** Not all wounds heal optimally. There are many factors that can interfere with one or more of the three wound healing phases, resulting in excessive scarring<sup>6</sup> (Table 27-4). For example, wounds that have been abraded or healed with minor degrees of infection in the patient with a propensity toward abnormal wound healing may develop hypertrophic scars or keloids. A hypertrophic scar is excessive or exuberant and appears indurated and raised from the wound edges but remains within the boundaries of the original injury. It represents an abnormal amount of collagen deposition.<sup>17</sup> Keloids, on the other hand, exceed the bounds of the original injury.<sup>65,66</sup> Risk of keloid formation is higher in African-Americans and Asians and lowest among Caucasians. Individuals who develop keloids are believed to have genetically abnormal wound healing.<sup>6</sup> Microscopically keloids also have an abnormal amount of disorganized collagen.<sup>6,66</sup> Pathologically there is

little difference between the two entities, and only a clinical distinction is made.

Hypertrophic and keloid scars are managed similarly. Initial early management includes the application of compression stockings. Silicone gel contact sheeting is also recommended.<sup>6,65-67</sup> Silicone gel sheeting reduces scar formation by an unclear mechanism. It has been hypothesized that gel sheeting may exert a beneficial effect by increasing skin temperature, moisturizing the scar, occluding the involved area, increasing pressure, or creating a small electrical current by friction contact across the immature scar.<sup>6,66,68</sup> At approximately 3 months, if evidence of hypertrophic scarring or keloid is present, steroid injections, typically of triamcinolone acetonide (Kenalog), may be administered. Steroid injections are not without complications. They may cause hypopigmentation of the surrounding wound and even of the normal skin, the development of telangiectasis, and weakening of the wound.<sup>66</sup> Scars that remain unsuitable at 1 year may be considered for surgical revision. However, before undertaking revision of a scar, it must be determined what is to be done differently this time as opposed to the initial repair. If the cause of the initial dissatisfactory scar is related to contusion or contamination, for example, then a new surgical wound may achieve the desired results. If the dissatisfactory scar is felt to arise as a result of the patient's biology, then scar revision will not achieve a satisfactory result and recurrence of excessive scarring is likely.<sup>6</sup> When surgery is combined with other therapies, such as intradermal corticosteroids, compression treatment, or radiation, results may be improved and the likelihood of recurrence is reduced.<sup>6,69</sup>

Certain lasers (e.g., Er:YAG or CO<sub>2</sub>) have been shown beneficial for resurfacing posttraumatic scars.<sup>65,70</sup> The mechanism of action for laser surfacing is to produce a photothermal injury to the dermis, which enhances new collagen production, remodeling, and reepithelization.

Contractures occur when scars shrink and restrict mobility or cause cosmetic deformity. Initially pressure dressings, range-of-motion exercises, braces, and serial casting or splinting are used to prevent and treat contractures.<sup>17,66</sup> Established contractures that resist stretching or that recur may require surgical intervention.<sup>17</sup> Z-plasty may be entertained to release a linear contracture (Figure 27-12). Simi-

**TABLE 27-4 Factors That Predispose to Excessive Scarring in Each Phase of Wound Healing**

Inflammatory Phase	Transitional Repair Phase	Remodeling Phase
<ul style="list-style-type: none"> <li>• Hematoma or foreign body</li> <li>• Infection or allergic reactions</li> <li>• Repetitive trauma (e.g., scratching)</li> <li>• Edema</li> <li>• Chronic open wound</li> <li>• Poorly aligned wound edges</li> <li>• Deep partial-thickness burn wound</li> <li>• Crush injury</li> </ul>	<ul style="list-style-type: none"> <li>• Physical or chemical irritants</li> <li>• Infection or allergic reactions</li> <li>• Genetic factors</li> <li>• Adolescence</li> <li>• Pregnancy</li> <li>• Endocrine disorders</li> <li>• Neurofibromatosis</li> </ul>	<ul style="list-style-type: none"> <li>• Mechanical tension</li> <li>• Anatomic location</li> </ul>

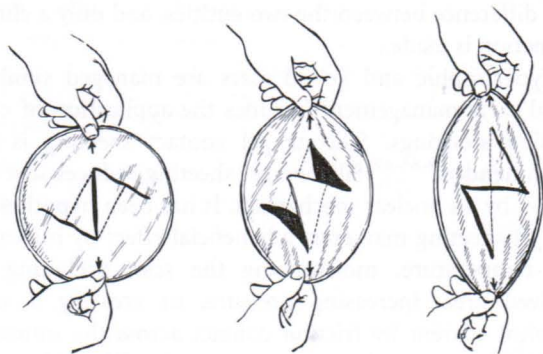


FIGURE 27-12. Z-plasty. (From McCarthy JG: Introduction to plastic surgery. In McCarthy JG editor: *Plastic surgery*, vol 1, *General principles*, Philadelphia, 1990, WB Saunders, 56.)

larly a double opposing z-plasty,<sup>71</sup> running z-plasty, or w-plasty may be required across linear contractures.<sup>65</sup> Larger contractures may require full-thickness skin grafting.

Trauma patients often require multiple procedures to achieve satisfactory scar revision. What may be satisfactory at one point in the patient's life may become dissatisfactory later on. Camouflage and makeup techniques can make wounds essentially imperceptible and scars entirely acceptable. For larger defects, such as an ear or nose defect, a bioprosthesis may be indicated.

**TRAUMATIC TATTOOING.** Traumatic tattooing from foreign debris (e.g., gravel, metallic substances) embedded into the skin can also present an aesthetic challenge. Because pigments are buried in the deep dermis, they are visible and typically not amenable to dermabrasion (skin sanding). Tattooing can be minimized by meticulous debridement of the wound at initial presentation. However, absent that, these deformities may be managed with laser resurfacing.<sup>4,72</sup> Lasers with various frequencies, each suitable to a particular pigment, are available. For example, yellow-light lasers may be employed for red-pigmented tattoos. Some caution must be exercised when using lasers because red tattoos containing iron may be turned black by oxidation and thereby worsened. Similarly, titanium-containing tattoos turn from white to black by laser oxidation. Results of laser therapy to repair traumatic tattooing remain somewhat unpredictable.

## SUMMARY

Optimizing outcomes from soft tissue injuries provides numerous opportunities for research. Further investigation into which interventions and techniques optimize wound healing and prevent infectious and long-term healing complications is necessary. How to best deal with the psychologic aspect of these injuries also requires further study. Additional research exploring the efficacy of alternative skin replacements and determining the usefulness of emerging technologies such as lasers and microdermabrasion is also under way.

Nurses work in collaboration with other health care team members to create and implement a plan of care that allows optimal outcomes to be achieved. Nurses caring for trauma

patients must be knowledgeable about soft tissue trauma and the techniques used to repair and reconstruct these injuries. Astute nursing assessment and meticulous care of soft tissue injuries can have a tremendous impact on the outcome of graft or flap survival and wound healing.

## REFERENCES

1. Johnson TM, Nelson BR: Anatomy of the skin. In Baker SR, Swanson NA, editors: *Local flaps in facial reconstruction*, St. Louis, 1995, Mosby, 3-14.
2. Stotts NA: Integumentary clinical physiology. In Kinney MR, Dunbar SB, Brooks-Brunn JA et al, editors: *AACN's clinical reference for critical care nursing*, ed 4, St. Louis, 1998, Mosby, 1055-1059.
3. Sunderland S: The anatomy and physiology of nerve injury, *Muscle Nerve* 13:771-784, 1990.
4. Troilius AM: Effective treatment of traumatic tattoos with a Q-switched Nd: YAG laser, *Lasers Surg Med* 22:103-108, 1998.
5. Lee RH, Gamble WB, Mayer MH et al: Patterns of facial laceration from blunt trauma, *Plast Reconstr Surg* 99: 1544-1554, 1997.
6. Su CW, Alizadeh K, Boddie A et al: The problem scar, *Clin Plast Surg* 25:451-465, 1998.
7. Cook TA, Brownlee RE: Rotation flaps. In Baker SR, Swanson NA, editors: *Local flaps in facial reconstruction*, St. Louis, 1995, Mosby, 75-90.
8. Stewart RM, Page CP: Wounds, bites, and stings. In Mattox KL, Feliciano DV, Moore EE, editors: *Trauma*, New York, 2000, McGraw-Hill, 1115-1135.
9. Wolff K-D: Management of animal bite injuries of the face: experience with 94 patients, *J Oral Maxillofac Surg* 56:838-843, 1998.
10. Robson MC, Duke WF, Krizek TJ: Rapid bacterial screening in the treatment of civilian wounds, *J Surg Res* 14:426-430, 1973.
11. Hoover TJ, Siefert JA: Soft tissue complications of orthopedic emergencies, *Emerg Med Clin North Am* 18:115-139, 2000.
12. American College of Surgeons' Committee on Trauma: *Advanced trauma life support for doctors student course manual*, ed 6, Chicago, 1997, American College of Surgeons.
13. Modrall JG, Weaver FA, Yellin AE: Diagnosis and management of penetrating vascular trauma and the injured extremity, *Emerg Med Clin North Am* 16:129-144, 1998.
14. Swain R, Ross D: Lower extremity compartment syndrome: when to suspect acute or chronic pressure buildup, *Postgrad Med* 105:159-168, 1999.
15. Chisholm CD, Wood CO, Chua G et al: Radiographic detection of gravel in soft tissue, *Ann Emerg Med* 29:725-730, 1997.
16. Manthey DE, Storrow AB, Milbourn JM et al: Ultrasound versus radiography in the detection of soft-tissue foreign bodies, *Ann Emerg Med* 28:7-9, 1996.
17. Hunt TK, Hopf HW: Wound healing and wound infection: what surgeons and anesthesiologists can do, *Surg Clin North Am* 77:587-606, 1997.
18. Kurz A, Sessler DI, Lenhardt R: Perioperative normothermia to reduce the incidence of surgical-wound infection and shorten hospitalization, *N Engl J Med* 334:1209-1215, 1996.
19. Hopf HW, Hunt TK, West JM et al: Wound tissue oxygen tension predicts the risk of wound infection in surgical patients, *Arch Surg* 132:997-1004, 1997.

20. Kirkpatrick AW, Chun R, Brown R et al: Hypothermia and the trauma patient, *Can J Surg* 42:333-343, 1999.
21. Ramasastry SS: Chronic problem wounds, *Clin Plast Surg* 25:367-396, 1998.
22. Robson MC: Wound infection: a failure of wound healing caused by an imbalance of bacteria, *Surg Clin North Am* 77:637-650, 1997.
23. Masem M, Greenberg BM, Hoffman C et al: Comparative bacterial clearances of muscle and skin/subcutaneous tissues with and without dead bone: a laboratory study, *Plast Reconstr Surg* 85:773-781, 1990.
24. Knighton DR, Halliday B, Hunt TK: Oxygen as an antibiotic: a comparison of the effects of inspired oxygen concentration and antibiotic administration on in vivo clearance, *Arch Surg* 121:191-195, 1986.
25. Rabinowitz RP, Caplan ES: Management of infections in the trauma patient, *Surg Clin North Am* 79:1373-1383, 1999.
26. Whitney JD, Heitkemper MM: Modifying perfusion, nutrition, and stress to promote wound healing in patients with acute wounds, *Heart Lung* 28:123-133, 1999.
27. Black JM: Surgical options in wound healing, *Crit Care Nurs Clin North Am* 8:169-182, 1996.
28. Stotts NA: Promoting wound healing. In Kinney MR, Dunbar SB, Brooks-Brunn JA et al, editors: *AACN's clinical reference for critical care nursing*, ed 4, St. Louis, 1998, Mosby, 237-245.
29. Caruso DM, King TJ, Tsujimura RB et al: Primary closure of fasciotomy incisions with a skin-stretching device in patients with burn and trauma, *J Burn Care Rehabil* 18:125-132, 1997.
30. Hirshowitz B, Lindenbaum E, Har-Shai Y: A skin-stretching device for the harnessing of the viscoelastic properties of skin, *Plast Reconstr Surg* 92:260-270, 1993.
31. Ratner D: Skin grafting: from here to there, *Dermatol Clin* 16:75-90, 1998.
32. Converse JM, Smahel J, Ballantyne DL et al: Inosculation of vessels of skin graft and host bed: a fortuitous encounter, *Br J Plast Surg* 28:274-282, 1975.
33. Argenta LC: Controlled tissue expansion in facial reconstruction. In Baker SR, Swanson NA, editors: *Local flaps in facial reconstruction*, St. Louis, 1995, Mosby, 517-544.
34. Hansbrough JF, Franco ES: Skin replacements, *Clin Plast Surg* 25:407-423, 1998.
35. Spence RJ, Wong L: The enhancement of wound healing with human skin allograft, *Surg Clin North Am* 77:731-745, 1997.
36. Winfrey ME, Cochran M, Hegarty MT: A new technology in burn therapy: Integra artificial skin, *Dimens Crit Care Nurs* 18:14-20, 1999.
37. Choucair MM, Phillips T: What is new in clinical research in wound healing, *Dermatol Clin* 15:45-58, 1997.
38. Gosain A, Chang N, Mathes S et al: A study of the relationship between blood flow and bacterial inoculation in musculocutaneous and fasciocutaneous flaps, *Plast Reconstr Surg* 86:1152-1162, 1990.
39. Calderon W, Chang N, Mathes SJ: Comparison of the effect of bacterial inoculation in musculocutaneous and fasciocutaneous flaps, *Plast Reconstr Surg* 77:785-794, 1986.
40. Murphy RC, Robson MC, Hegggers JP et al: The effect of microbial contamination on musculocutaneous and random flaps, *J Surg Res* 41:75-80, 1986.
41. Heniford BW, Bailin PL, Marsico RE: Field guide to local flaps, *Dermatol Clin* 16:65-74, 1998.
42. Khouri RK, Cooley BC, Kunselman AR et al: A prospective study of microvascular free-flap surgery and outcome, *Plast Reconstr Surg* 102:711-721, 1998.
43. O'Brien CJ, Lee KK, Stern HS et al: Evaluation of 250 free-flap reconstructions after resection of tumors of the head and neck, *Aust N Z J Surg* 68:698-701, 1998.
44. Hallock GG: "Microleaps" in the progression of flaps and grafts, *Clin Plast Surg* 23:117-138, 1996.
45. Ascari-Raccagni A, Baldari U: Liposuction surgery for the treatment of large hematomas on the leg, *Dermatol Surg* 26:263-264, 2000.
46. Grief R, Akca O, Horn E-P et al: Supplemental oxygen to reduce the incidence of surgical-wound infection, *N Engl J Med* 342:161-167, 2000.
47. Fulton JE: The use of hyperbaric oxygen (HBO) to accelerate wound healing, *Dermatol Surg* 26:1170-1172, 2000.
48. Clark LA, Moon RE: Hyperbaric oxygen in the treatment of life-threatening soft-tissue infections, *Respir Care Clin N Am* 5:203-219, 1999.
49. Zhang F, Cheng C, Gerlach T et al: Effect of hyperbaric oxygen on survival of the composite ear graft in rats, *Ann Plast Surg* 41:530-534, 1998.
50. Niezgoda JA, Cianci P, Folden BW et al: The effect of hyperbaric oxygen therapy on a burn wound model in human volunteers, *Plast Reconstr Surg* 99:1620-1625, 1997.
51. Bouachour G, Cronier P, Gouello JP et al: Hyperbaric oxygen therapy in the management of crush injuries: a randomized double-blind placebo-controlled clinical trial, *J Trauma* 41:333-339, 1996.
52. Jain KK: *Textbook of hyperbaric medicine*, ed 3, Seattle, 1999, Hogrefe & Huber, 189-210.
53. Kaye ET: Topical antibacterial agents, *Infect Dis Clin North Am* 14:321-339, 2000.
54. Ladin DA: Understanding dressings, *Clin Plast Surg* 25:433-441, 1998.
55. Winter GD: Formation of the scab and the rate of epithelization of superficial wounds in the skin of the young domestic pig, *Nature* 193:293-294, 1962.
56. Mortenson BW, Dawson KH, Murakami C: Medicinal leeches used to salvage a traumatic nasal flap, *Br J Oral Maxillofac Surg* 36:462-464, 1998.
57. Utley DS, Koch RJ, Goode RL: The failing flap in facial plastic and reconstructive surgery: Role of the medicinal leech, *Laryngoscope* 108:1129-1135, 1998.
58. Greenfield E: Integumentary disorders. In Kinney MR, Dunbar SB, Brooks-Brunn JA et al, editors: *AACN's clinical reference for critical care nursing*, ed 4, St. Louis, 1998, Mosby, 1065-1087.
59. Flanagan KH: Nutritional aspects of wound healing, *Adv Wound Care* 10:48-52, 1997.
60. Fabian TS, Kaufman HJ, Lett ED et al: The evaluation of subatmospheric pressure and hyperbaric oxygen in ischemic full-thickness wound healing, *Am Surg* 66:1136-1143, 2000.
61. Mooney JF, Argenta LC, Marks MW et al: Treatment of soft tissue defects in pediatric patients using the V.A.C.<sup>TM</sup> system, *Clin Orthop Rel Res* 376:26-31, 2000.
62. Argenta LC, Morykwas MJ: Vacuum-assisted closure: a new method for wound control and treatment: clinical experience, *Ann Plast Surg* 38:563-576, 1997.
63. Morykwas MJ, Argenta LC, Shelton-Brown EI et al: Vacuum-assisted closure: a new method for wound control and treatment: animal studies and basic foundation, *Ann Plast Surg* 38:553-562, 1997.

64. Magnan MA: Psychological considerations for patients with acute wounds, *Crit Care Nurs Clin North Am* 8:183-193, 1996.
65. McGillis ST, Lucas AR: Scar revision: the cellular and molecular basis for therapy, *Dermatol Clin* 16:165-180, 1998.
66. Tredget EE, Nedelec B, Scott PG et al: Hypertrophic scars, keloids, and contractures The cellular and molecular basis for therapy, *Surg Clin North Am* 77:701-729, 1997.
67. Berman B, Flores F: Comparison of a silicone gel-filled cushion and silicon gel sheeting for the treatment of hypertrophic or keloid scars, *Dermatol Surg* 25:484-486, 1999.
68. Hirshowitz B, Lindenbaum E, Har-shai Y et al: Static-electric field induction by a silicone cushion for the treatment of hypertrophic and keloid scars, *Plast Reconstr Surg* 101: 1173-1183, 1998.
69. Berman B, Bieleley HC: Adjunct therapies to surgical management of keloids, *Dermatol Surg* 22:126-130, 1996.
70. Jacobson D, Bass LS, VanderKam V et al: Carbon dioxide and ER:YAG laser resurfacing, *Clin Plast Surg* 27:241-250, 2000.
71. Gahhos FN, Cuono CB: Double-Z rhombic technique for reconstruction of facial wounds, *Plast Reconstr Surg* 85: 869-873, 1990.
72. Chang S-E, Choi J-H, Moon K-C et al: Successful removal of traumatic tattoos in Asian skin with a Q-switched Alexandrite laser, *Dermatol Surg* 24:1308-1311, 1998.