

Recipient Vessel Analysis for Microvascular Reconstruction of the Head and Neck

Maurice Y. Nahabedian, MD, FACS,* Navin Singh, MD, FACS,* E. Gene Deune, MD,*
Ronald Silverman, MD,† and Anthony P. Tufaro, DDS, MD*

Abstract: The selection of recipient vessels that are suitable for microvascular anastomosis in the head and neck region is one of many components that is essential for successful free tissue transfer. The purpose of this study was to evaluate a set of factors that are related to the recipient artery and vein and to determine how these factors influence flap survival. A retrospective review of 102 patients over a 5-year consecutive period was completed. Indications for microvascular reconstruction included tumor ablation (n = 76), trauma (n = 13), and chronic wounds or facial paralysis (n = 13). The most frequently used recipient artery and vein included the facial, superficial temporal, superior thyroid, carotid, and jugular. Various factors that were related to the recipient vessels were analyzed and included patient age, recipient artery and vein, diabetes mellitus, tobacco use, the timing of reconstruction, the method of anastomosis, previous radiation therapy, creation of an arteriovenous loop, and use of an interposition vein graft. Successful free tissue transfer was obtained in 97 of 102 flaps (95%). Flap failure was the result of venous thrombosis in 4 and arterial thrombosis in 1. Statistical analysis demonstrated that anastomotic failure was associated with an arteriovenous loop (2 of 5, $P = 0.03$) and tobacco use (3 of 5, $P = 0.03$). Flap failure was not related to patient age, choice of recipient vessel, diabetes mellitus, previous irradiation, the method of arterial or venous anastomosis, use of an interposition vein graft, or the timing of reconstruction.

(*Ann Plast Surg* 2004;52: 148–155)

The selection of recipient vessels that are suitable for microvascular anastomosis within the head and neck is an important component affecting patency. The vascular anatomy of the head and neck is complex with numerous arteries and veins from which to choose.^{1,2} The decision is usually based on the location of the defect and the proximity of a recipient artery and vein. Recipient vessels that are in close proximity to the defect are usually anastomosed to the donor vessels in an end-to-end or end-to-side fashion. However, in circumstances in which the local vascular access is not available or when the quality of the local vasculature is inadequate, remote vascular access could be required.^{3–5}

There are a variety of factors that can influence the access and quality of recipient vessels. These can include patient age,^{6–8} tobacco use,^{9–11} diabetes mellitus,^{12–15} prior radiation therapy,^{1,16–18} and prior operative procedures.^{3,19–21} Other factors such as the timing of reconstruction,²² method of anastomosis,^{23–25} and the length of the vascular pedicle^{26–29} are also important considerations. The effects of these factors on the patency of a vascular anastomosis have been previously studied; however, most of these studies were designed to evaluate each factor as an isolated variable. A multifactorial analysis has not been performed. Thus, it was the intent of this study to review a set of factors related to the recipient artery and vein, and to determine how these factors influence the anastomotic patency and survival of free tissue transfer in the head and neck.

MATERIALS AND METHODS

This is a retrospective review of 102 patients over a 5-year consecutive period. Included were 73 men and 29 women with a mean age of 53 years (range, 10–85 years). Indications for microvascular reconstruction included tumor ablation in 76 patients, trauma in 13 patients, and chronic wounds or facial paralysis in 13 patients. The location of the defects, types of flaps, recipient arteries, and recipient veins are listed in Figures 1, 2, 3, and 4. Factors that were considered relevant to the recipient artery and vein were analyzed and included patient age, diabetes mellitus, the specific artery and vein, tobacco use (>10 cigarettes per day), prior radia-

Received March 25, 2003, and Accepted for publication June 21, 2003. in revised form June 9, 2003.

From the *Division of Plastic and Reconstructive Surgery, Johns Hopkins University, Baltimore, Maryland; and the †Division of Plastic and Reconstructive Surgery, University of Maryland, Baltimore, Maryland.

Presented at the annual meeting of the American Society for Reconstructive Microsurgery, Kauai, Hawaii, January 11–14, 2003.

Reprints: Maurice Nahabedian, MD, FACS, Johns Hopkins Hospital, 601 North Caroline Street 8152C, Baltimore, MD 21287. E-mail: mnahabed@jhmi.edu

Copyright © 2004 by Lippincott Williams & Wilkins

ISSN: 0148-7043/04/5202-0148

DOI: 10.1097/01.sap.0000095409.32437.d4

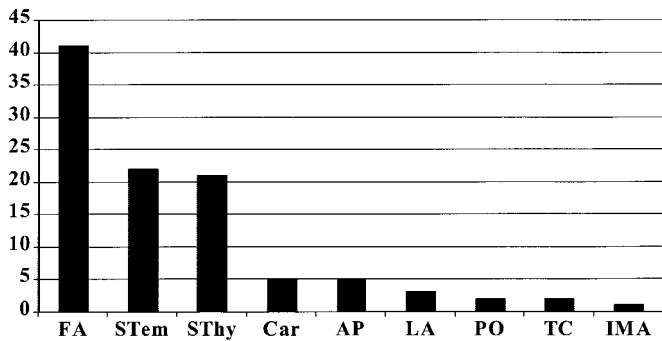


FIGURE 1. The recipient arteries are tabulated. FA = facial artery; Stem = superficial temporal artery; Sthy = superior thyroid artery; Car = carotid artery; AP = ascending pharyngeal artery; LA = lingual artery; PO = posterior occipital artery; TC = transverse cervical artery; IMA = internal mammary artery.

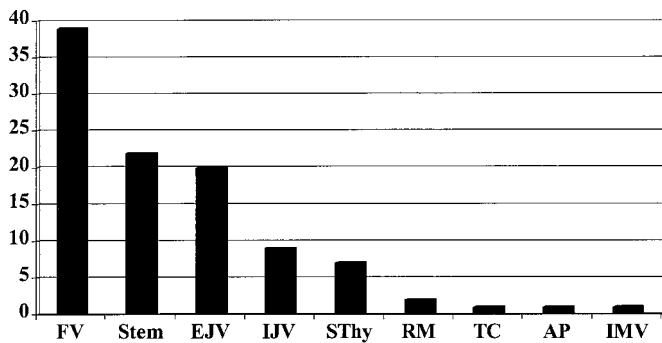


FIGURE 2. The recipient veins are tabulated. FV = facial vein; Stem = superficial temporal vein; EJV = external jugular vein; IJV = internal jugular vein; Sthy = superior thyroid vein; RM = retromandibular vein; TC = transverse cervical vein; AP = ascending pharyngeal vein; IMA = internal mammary artery.

tion therapy, timing of the reconstruction (immediate or delayed), creation of an arteriovenous loop, use of an interposition vein graft, and type of vascular anastomosis (end-to-end or end-to-side). Statistical analysis was performed with logistic regression analysis using Chi-squared and Fisher exact test.

Selection of Recipient Vessels

The algorithm for selection of the recipient vessels is based on the location of the acquired defect and the proximity of the recipient vessels. In general, for defects located in the upper third of the head, the superficial temporal artery and vein were usually selected. For defects located in the mid and lower third of the face, the facial as well as superior thyroid artery and vein were usually used. For defects located in the neck, the carotid and jugular vessels as well as their various branches were frequently used. In all regions, an end-to-end anastomosis was performed when possible. However, when

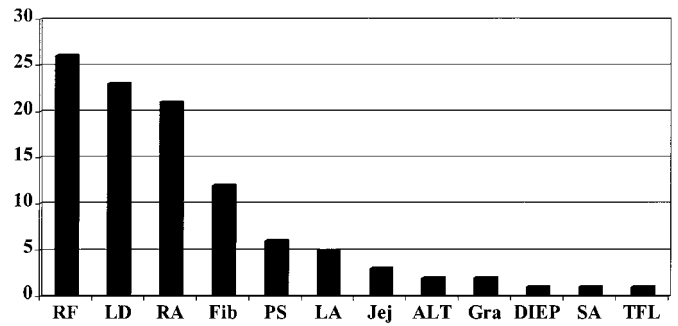


FIGURE 3. The number of each flap used is tabulated. RF = radial forearm; LD = latissimus dorsi; RA = rectus abdominus; Fib = fibula; PS = parascapular; LA = lateral arm; Jej = jejunum; ALT = anterolateral thigh; Gra = gracilis; DIEP = deep inferior epigastric perforator; SA = serratus anterior; TFL = tensor fascia lata.

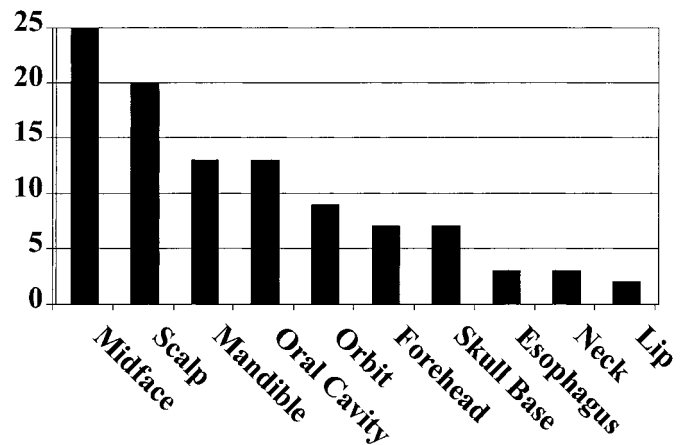


FIGURE 4. The locations of the defects or deformities are tabulated.

an end-to-end anastomosis was not possible as a result of a significant difference in the diameter of the lumen or because of poor-quality vessels, an end-to-side anastomosis was performed.

In situations in which the primary recipient vessel was no longer available as a result of previous ablation, prior free tissue transfer, or poor quality or caliber, selection of alternative recipient vessels was necessary. These alternative vessels were often at a greater distance from the primary defect that resulted in the length of the vascular pedicle becoming a limiting factor. Options to increase the length of the vascular pedicle included selection of an alternative flap with a longer vascular pedicle, use of an interposition vein graft, or creation of an arteriovenous loop.^{5,27,30}

The decision to use an interposition vein graft or arteriovenous loop was based on the distance between the recipient and flap vessels. The conduit material for grafts and

loops was saphenous vein in all cases. In general, when the gap was less than 10 cm, a reversed interposition vein graft was used; when the anticipated gap was greater than 10 cm, a reversed arteriovenous loop was created. Acquired defects requiring an arteriovenous loop were usually located on the scalp or forehead when the principal recipient vessel was no longer available or because alternative recipient vessels in the local vicinity were inadequate. The arteriovenous loops were created using a 20- to 40-cm segment of saphenous vein and anastomosed to the recipient artery and vein with the aid of a microscope. The anastomotic technique between the graft and the recipient vessel was end-to-end unless there was a greater than 2:1 size discrepancy. In these cases, an end-to-side anastomosis was performed. The arteriovenous loop was positioned under a preauricular skin flap with the tip of the loop usually extending to the zygomatic arch (Fig. 5). The loop was divided at its midpoint before microvascular anastomosis to the flap artery and vein. Reconstructions using arteriovenous loops were performed as a 1-stage operation in which the loop was created and divided at the time of flap reconstruction as well as a 2-stage operation in which the loop was created followed by division and anastomosis to the flap 1 week later. An arteriovenous loop was used in 6 patients, which included 3 1-stage and 3 2-stage operations.

Preparation of Recipient Vessels

Recipient vessels were prepared using 2.5- to 3.5-power loupe magnification. In general, a 2- to 3-cm segment of the artery and vein was isolated. The recipient vessels were assessed for caliber, quality, and compatibility with the flap vessels. In general, the minimum diameter of arteries and veins selected for microvascular anastomosis was 1 mm. The diameter of each vessel was assessed to ensure that an

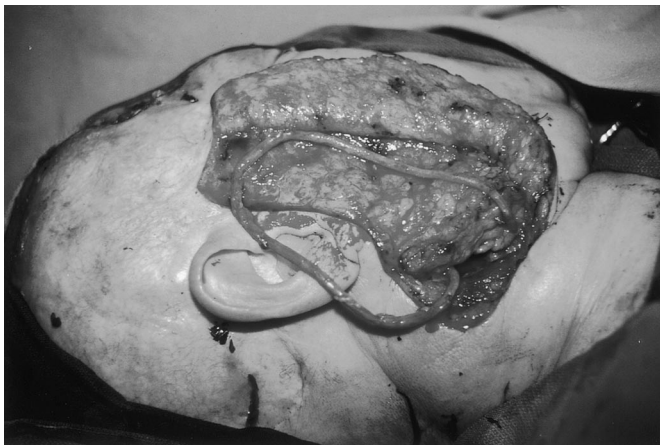

FIGURE 5. A 40-cm saphenous vein graft is used to create an arteriovenous loop. The arteriovenous loop is positioned under a preauricular skin flap and divided at its distal aspect at the time of flap reconstruction.

end-to-end anastomosis would be possible. When the vascular mismatch was significant (greater than 2:1), an end-to-side anastomosis was performed. Mild to moderate perivascular fibrosis after radiation therapy or previous surgery was not a contraindication for use; however, severe perivascular fibrosis was a contraindication. Most anastomoses were performed using 8-0 or 9-0 nylon sutures placed in an interrupted fashion. The anastomotic coupler was used in 10 patients (MCA, Birmingham, AL). All arterial and venous anastomoses were end-to-end.

Pharmacologic regimens were used to facilitate patency of the microvascular anastomosis. These included an intravenous administration of 5000 IU of heparin (Wyeth Ayerst, Philadelphia, PA) 5 minutes before transecting the artery and vein of the flap. Four percent Xylocaine (AstraZeneca, Wilmington, DE) was used as a topical vasodilator before division of the recipient vessels. A dilute heparin solution (100 units per mL) was used as an intraluminal irrigant before the anastomosis. Postoperatively, some patients received Dextran 40 at 30 mL per hour for 3 days and some patients received subcutaneous injections of heparin while in the hospital. This decision was based on the surgeons' preference. In addition, 325 mg Ecotrin (GlaxoSmithKline, Pittsburgh, PA) per day was begun on postoperative day 1 and continued for 1 month.

Flap monitoring consisted of visual and auditory assessment. Visual evaluation included capillary refill, flap color, change in the volume of the flap (edema or congestion), and adherence of the skin grafts when used. Auditory evaluation included demonstration of an arterial and venous Doppler signal. Another method included evaluation of temperature using surface probes or the back of the hand. The implantable Doppler was not used. All flaps were monitored on an hourly basis for the first 48 hours and then every 4 hours while in the hospital. On recognition of impaired circulation, the patient was immediately transported to the operating room for exploration.

RESULTS

Risk factor review of the 102 patients demonstrated diabetes mellitus in 7 patients (6.8%), tobacco use in 28 (27.4%), immediate reconstruction in 79 (77%), delayed reconstruction in 23 (23%), radiation therapy in 24 (23.5%), arteriovenous loop in 6 (5.9%), and vein graft in 2 (2.0%). The specific recipient artery and veins selected are listed in Figures 1 and 2. The arterial anastomosis was end-to-end in 97 patients (95%) and end-to-side in 5 (5%). The venous anastomosis was end-to-end in 91 patients (89%) and end-to-side in 11 (11%). Thrombosis at the anastomosis occurred in 9 patients and required operative exploration. The thrombosis was venous in 8 patients and arterial in 1 patient. Of these, the recipient veins included the superficial temporal in 2 patients, facial in 2 patients, external jugular in 2 patients,

retromandibular in 1 patient, and superior thyroid in 1 patient. The recipient artery was the superficial temporal.

Total survival was obtained in 97 of 102 flaps (95%) with successful salvage in 4 of 9 flaps (44%) that required reoperation for thrombosis. Of the 5 flap failures, the etiology was venous thrombosis in 4 and arterial thrombosis in 1. Of these, the recipient veins included the superficial temporal, facial, and in 2 patients the external jugular, whereas the recipient artery included the superficial temporal. A significant association was demonstrated between flap failure and tobacco use ($P = 0.03$) and use of an arteriovenous loop ($P = 0.03$). No significant association was demonstrated between flap failure and prior radiation, the artery or vein selected, diabetes mellitus, interposition vein grafts, method of arterial or venous anastomosis, patient age, and timing of reconstruction. Tables 1 and 2 include the various factors and their association with anastomotic and flap failure.

Tobacco Use

Tobacco use was reported in 28 of 102 patients (28.4%). Of these, patency of the anastomosis was observed in 25 of 28 patients (89.3% good outcome). In the patients who did not report tobacco use, patency of the anastomosis was observed in 72 of 74 patients (97.3% good outcome). Flap failure was associated with tobacco use in 3 of 5 patients (60%, $P = 0.03$). Odds ratio analysis demonstrated that tobacco use decreased the odds of success by 9.4 times when controlling for the other risk factors.

Arteriovenous Loop

An arteriovenous loop was used in 6 patients using the saphenous vein. The timing of the reconstruction was immediate in 1 patient and delayed in 5 patients. The recipient arteries for the loop included the superior thyroid ($n = 2$), facial ($n = 2$), posterior occipital ($n = 1$), and superficial temporal ($n = 1$). The recipient veins for the loop included the external jugular ($n = 2$), superior thyroid ($n = 1$), retromandibular ($n = 1$), superficial temporal ($n = 1$), and facial ($n = 1$). The method of anastomosis was end-to-end for the 6 arteries, end-to-end for 4 veins, and end-to-side for 2 veins. The arteriovenous loop was created and divided in 1

TABLE 1. Association Between Flap Failure and Factors Unrelated to the Anastomosis

Flap Failure and...	Rate	Percent of Failures	Percent of Total
Radiation therapy	0 of 5	0	0
Diabetes mellitus	0 of 5	0	0
Tobacco use	3 of 5	60	17
Arteriovenous loop	2 of 5	40	33
Interposition graft	0 of 5	0	0

TABLE 2. Association Between Factors Related to the Anastomosis and Flap Failure

Factor	Rate	Percent
Total flap failure	5 of 102	4.9
Venous thrombosis	4 of 102	3.9
Arterial thrombosis	1 of 102	1.0
Arterial end-to-end	5 of 97	5.2
Arterial end-to-side	0 of 5	0
Venous end-to-end	4 of 91	4.4
Venous end-to-side	1 of 11	9

stage in 3 patients and in 2 stages in 3 patients. Patency of the anastomosis was demonstrated in 4 of 6 patients (67% good outcome) using an arteriovenous loop. The 2 failures occurred in patients who had a delayed reconstruction in which the arteriovenous loop was performed as a 1-stage procedure for 1 patient and as a 2-stage procedure for the other. The etiology was thrombosis of the venous limb in both failures. When no vein loop was used, flap failure occurred in 3 of 96 patients (96.9% good outcome). The length of the arteriovenous loop did not affect patency. Statistical analysis demonstrated the use of an arteriovenous loop increased the odds of flap failure by 22 times ($P = 0.03$) when controlling for the other risk factors.

Method of Anastomosis

The venous anastomosis was end-to-end in 91 patients and end-to-side in 11 patients, whereas the arterial anastomosis was end-to-end in 97 patients and end-to-side in 5 patients. An association between flap failure and the method of venous anastomosis was observed in 1 of 11 patients after end-to-side anastomosis (90.9% good outcome) and in 4 of 91 patients after end-to-end anastomosis (95.6% good outcome). An association between flap failure and the method of arterial anastomosis was observed in 0 of 5 patients after end-to-side anastomosis (100% good outcome) and in 5 of 97 patients after end-to-end anastomosis (94.8% good outcome). The anastomotic coupling device was used in 10 patients with no observed failures. Statistical analysis demonstrated that a venous end-to-end anastomosis increases the odds of success by 3.4 times; however, this was not a significant difference when compared with end-to-side. There were no significant differences in patency when comparing methods of arterial anastomosis.

Prior Radiation

Radiation treatment before reconstruction was completed in 24 patients (23.5%). Patency of the anastomosis was demonstrated in all patients who had prior radiation (100% good outcome). Of the 78 patients who did not have radiation, patency of the anastomosis was maintained in 73 (93.6%)

good outcome). This difference was not statistically significant.

Diabetes Mellitus

Diabetes mellitus was documented in 7 patients. Patency of the anastomosis was observed in all 7 patients (100% good outcome) after microvascular reconstruction. Of the patients who were not diabetic, patency of the anastomosis was observed in 90 of 95 patients (94.7% good outcome). These differences were not statistically significant.

Interposition Vein Grafts

Interposition vein grafts were used in 2 patients. These grafts were 6 and 10 cm in length and were used for both the artery and vein. Patency of the anastomosis was observed for all patients (100% good outcome). When no vein grafts were used, patency of the anastomosis was observed in 95 of 100 patients (95% good outcome). These differences were not statistically significant.

Patient Age and Indications for Surgery

Patient age and indication for surgery was analyzed. Within the subpopulation of patients who had a free tissue transfer after tumor resection, the mean age was 58.3 years (range, 10–85 years) with an overall success rate of 96.1%. Within the subpopulation of patients who had a free tissue transfer after trauma, the mean age was 35.7 years (range, 14–49 years) with an overall success rate of 92.3%. Within the subpopulation of patients who had a free tissue transfer chronic wounds or facial paralysis, the mean age was 38.5 years (range, 13–76 years) with an overall success rate of 92.3%. The mean age of the 5 patients with flap loss was 53 years (range, 32–74 years). These differences were not statistically significant.

Timing of Reconstruction

The timing of the reconstruction was immediate in 79 patients (77%) and delayed in 23 patients (23%). Patency of the anastomosis was maintained in 77 of 79 patients (97.5% good outcome) after immediate reconstruction and in 20 of 23 patients (87% good outcome) after delayed reconstruction. Statistical analysis demonstrates that immediate reconstruction increases the odds of success by 1.6 times; however, no significant difference was demonstrated.

DISCUSSION

Successful outcome after microvascular reconstruction of the head and neck has been reported to range from 93% to 99%.^{19–21,31,32} This success rate is dependent on 3 basic components that include the preoperative evaluation of the patient, technical aspect of the operation, and postoperative management.^{33,34} Although this article is focused on the selection of recipient vessels, the authors acknowledge that maintaining patency of a vascular anastomosis is not depen-

dent solely on the selection of recipient vessels, but rather a comprehensive understanding of all factors and their interactions. Preoperatively, these can include proper patient selection and assessment of comorbidities. Intraoperatively, these can be related to the preparation of the donor and recipient vessels technique of anastomosis and proper inseting of the flap. Postoperatively, it is important to maintain hemodynamic stability and control the external milieu. Although all of these factors merit discussion, it was the intent of this study to analyze only those factors associated with the choice of recipient vessels.

There are a variety of factors that can influence the selection of recipient vessels.^{1,2,17,34–39} The factors that were evaluated in this study included patient age, diabetes mellitus, tobacco use, timing of reconstruction, prior radiation therapy, method of anastomosis, use of accessory venous conduits, and the recipient vessel selected. Of these, the only factors associated with flap failure were use of an arteriovenous loop and tobacco use. Explanations for these observations are based on analysis of the results and review of the literature.

The use of an arteriovenous loop in the head and neck has been previously described.^{40–44} These loops have been performed as 1-stage procedures in which the arteriovenous loop is created and divided at the time of the free tissue transfer and as 2-stage procedures in which the arteriovenous loop is created then followed by the free tissue transfer at a second operation. Angel et al. have reported on 11 patients following single-stage reconstruction using an arteriovenous loop.⁴² In 3 patients, the reconstruction was in the head and neck of whom all had successful free tissue transfer. Sorensen et al. have advocated the 2-stage arteriovenous loop.⁴⁴ The median time from creation to division of the arteriovenous loop was 7 days. Patency of the loop was demonstrated in 7 of 9 patients (78%). Revision of the loop was successful in 1 of the 2 nonpatent loops. Taub et al., in an experimental model evaluating arteriovenous loops made of polytetrafluoroethylene, have evaluated the patency rate as a function of time.⁴¹ The patency rate was 59% after 3 days of loop maturation, 79% after 5 days, and 80% after 7 days.

Specific reasons for failure of the arteriovenous loop in this study are difficult to explain because patency of the loop was not related to the length of the loop, choice of recipient artery or vein, whether the loop was performed in 1 or 2 stages, and method of anastomosis. However, factors that could have contributed to this occurrence include external compression, vascular spasm, and scar. The location of the principle artery and vein was the neck for 5 loops and the temporal region for 1 loop. Arteriovenous loops in the neck region are susceptible to external forces related to head rotation and compression from adjacent structures such as the parotid gland, mandible, or cheek flap. In 5 of the 6 loops, the reconstruction was delayed and the 2 failed loops occurred after delayed reconstruction.

The association between tobacco use and peripheral vascular disease involving the extremities has been well documented.^{9–11} However, an association between tobacco use and vascular disease in the head and neck is not well documented. Previous studies have demonstrated that tobacco use is not a contraindication for free tissue transfer in the head and neck with flap success rates that are similar to patients who do not use tobacco.^{4,30} In this study, tobacco use was associated with anastomotic failure in 3 of 5 flaps ($P = 0.03$). Specific reasons for this observation include vascular spasm and increased thrombogenic potential. However, in 4 of the 5 anastomotic failures, the etiology was venous thrombosis. The possible effects of tobacco use on the venous system have not been well defined and warrant further study.

Factors related to the recipient vessels that were not associated with flap failure included patient age, timing of reconstruction, diabetes mellitus, method of anastomosis, prior radiation therapy, interposition vein grafts, and the specific artery or vein selected. Previous studies have evaluated many of these factors and demonstrated significant findings. Patient age has been demonstrated in most studies not to be a contraindication for free tissue transfer in the head and neck unless associated with multiple comorbidities.^{6–8} Bridger has demonstrated that in patients over 70 years of age who had free tissue transfer after ablative operations in the head and neck, the incidence of postoperative complications was not significantly different from the younger cohort of patients.⁸ Serletti has demonstrated that it is the American Society of Anesthesiologists (ASA) status and the length of the operation that are significant predictors of postoperative morbidity.⁶ Operations exceeding 10 hours were associated with a higher surgical complication rate ($P < 0.05$) and patients with ASA scores of 3 or 4 experienced a higher medical complication rate ($P < 0.05$).

The type of anastomosis (end-to-end vs. end-to-side) in the head and neck has been controversial.^{23–25} Advocates of end-to-end anastomosis state that laminar flow is maintained and the incidence of thrombus formation is reduced. However, more recent reports have implied that end-to-side anastomosis does not increase the incidence of anastomotic failure and that blood flow rate is not significantly altered.^{24,29,45,46} Ueda has demonstrated that the incidence of thrombosis was 1.8% (15 of 835) after end-to-end anastomosis to various veins and 2.7% (3 of 113) after end-to-side anastomosis to the internal jugular vein.²⁴ There was no significant difference in the 2. Advocates of the end-to-side technique site additional benefits.^{23,29,47} These include multiple anastomoses to a single vessel, overcoming discrepancies in vessel size, avoidance of vessel retraction, and that the internal jugular vein acts as a venous siphon through the actions of the respiratory muscles.

The effect of radiation on arteries and veins has been well documented. Perivascular fibrosis, endothelial damage,

and microvascular occlusion can impair the quality of recipient vessels.^{48–51} However, clinical studies have demonstrated that prior radiotherapy in the head and neck does not adversely affect flap survival and anastomotic patency.^{1,16,30,52} More recent studies have further elucidated the anatomic and physiologic changes associated with effect of radiation on arteries and veins. Schultze-Mosgau demonstrated that the histologic changes of the vasculature after radiation are dose-dependent.⁵¹ After radiation with 60 to 70 Gy, the histologic changes included intimal dehiscence, hyalinosis, and a decrease in the media area-to-total-vessel-area ratio. These changes were observed in the artery but not in the vein. When no radiation was administered or at a radiation dose of 40 to 50 Gy, these changes were not observed. Beckman et al. have demonstrated that external beam radiation impairs endothelial-dependent vasodilation of arteries that can contribute to the development of arterial occlusive disease.⁴⁸ The clinical significance of this phenomenon has not been determined, but could be related to slow recovery from vasospasm.

The use of interposition vein grafts is an effective means of increasing the length of the vascular pedicle.^{26–28,36,52,53} Early studies evaluating the use of interposition vein grafts for microvascular reconstruction in the head and neck demonstrated a 30% failure rate compared with a 5% failure rate when no interposition vein grafts were used.²⁷ More recent studies have demonstrated that there is no difference in survival after free tissue transfer with and without the use of vein grafts.²⁸ In a study of 340 patients, German has demonstrated that the incidence of flap survival with vein grafts (55 patients) and without vein grafts (275 patients) are equal (96.2% and 96.7%, respectively). However, the percentage of flaps requiring revision of the anastomosis is greater for free flaps with vein grafts than without (14.8% and 8.7%, respectively).

The adverse effects of diabetes mellitus are related to the microangiopathic changes that occur within the skin and muscle. Experimental studies using rats have demonstrated that the degree of intimal repair and endothelialization is lower in poorly controlled patients with diabetes that can lead to anastomotic failure.¹³ However, when glycemic levels are well controlled, patency of the anastomosis is less affected.¹² Indeed, clinical studies have demonstrated that patients with diabetes mellitus are not at increased risk for flap failure, abnormal healing of the anastomosis, or intolerance to an ischemic challenge as long as normal glycemia is maintained.^{14,15} However, other studies have demonstrated that the combination of diabetes mellitus and tobacco use appears to result in increased morbidity.¹¹ The incidence of coronary artery disease and cerebrovascular accidents are increased; however, the effects on the vascularity in the head and neck are undetermined. In this study, 4 patients with diabetes

mellitus and 3 patients with diabetes who also used tobacco exhibited no adverse sequelae related to anastomosis or flap.

The results of this study have demonstrated that all vessels in the head and neck are potentially suitable for microvascular anastomoses. The only factors that were associated with flap failure included the use of arteriovenous loops and tobacco use. The authors recognize that these conclusions are based on 2 of 5 failures associated with arteriovenous loops and in 3 of 5 failures associated with tobacco use, and that these findings might be contrary to previously published reports.^{4,30,42,44} However, based on our population of patients, statistical significance was demonstrated. Our current practice is to use interposition vein grafts when pedicle length is insufficient and to restrict tobacco use before microvascular reconstruction in the head and neck.

REFERENCES

- Mulholland S, Boyd JB, McCabe S, et al. Recipient vessels in head and neck microsurgery: radiation effect and vessel access. *Plast Reconstr Surg.* 1993;92:628–632.
- Chalian AA, Anderson TD, Weinstein GS, et al. Internal jugular vein versus external jugular vein anastomosis: implications for successful free tissue transfer. *Head Neck.* 2001;23:475–478.
- Head C, Sercarz JA, Abelmayer E, et al. Microvascular reconstruction after previous neck dissection. *Arch Otolaryngol Head Neck Surg.* 2002;128:328–331.
- Schusterman MA, Miller MJ, Reece GP, et al. A single center's experience with 308 free flaps for repair of head and neck cancer defects. *Plast Reconstr Surg.* 1994;93:472–480.
- Nakayama B, Kamei Y, Toriyama K, et al. Usefulness of a first transferred free flap vascular pedicle for secondary microvascular reconstruction in the head and neck. *Plast Reconstr Surg.* 2002;109:1246–1253.
- Serletti JM, Higgins JP, Moran S, et al. Factors affecting outcome in free tissue transfer in the elderly. *Plast Reconstr Surg.* 2000;106:66–70.
- Pompei S, Tedesco M, Pozzi M, et al. Age as a risk factor in cervicofacial reconstruction. *J Exp Clin Cancer Res.* 1999;18:209–212.
- Bridger AG, O'Brien CJ, Lee KK. Advanced patient age should not preclude the use of free flap reconstruction for head and neck cancer. *Am J Surg.* 1994;168:425–428.
- Cole CW, Hill GB, Farzad E. Cigarette smoking and peripheral arterial occlusive disease. *Surgery.* 1993;114:756–757.
- Fagerstrom K. The epidemiology of smoking: health consequences and benefits of cessation. *Drugs.* 2002;62:1–9.
- Haire-Joshu D, Glasgow RE, Tibbs TL. Smoking and diabetes. *Diabetes Care.* 1999;22:1887–1898.
- Colen LB, Stevenson A, Siderov V, et al. Microvascular anastomotic thrombosis in experimental diabetes mellitus. *Plast Reconstr Surg.* 1997;99:156–162.
- Barr LC, Joyce AD. Microvascular anastomoses in diabetes and experimental study. *Br J Plast Surg.* 1989;42:50–53.
- Cooley BC, Hanel DP, Anderson RB, et al. The influence of diabetes on free flap transfer: I. Flap survival and microvascular healing. *Ann Plast Surg.* 1992;29:58–64.
- Cooley BC, Hanel DP, Lan M, et al. The influence of diabetes on free flap transfer: II. The effect of ischemia on flap survival. *Ann Plast Surg.* 1992;29:65–69.
- Bengstrom BP, Schusterman MA, Baldwin BJ, et al. Influence of prior radiotherapy on the development of postoperative complications and success of free tissue transfers in the head and neck. *Am J Surg.* 1993;166:326–330.
- Aitasalo K, Relander M, Virolainen E. Microvascular free tissue transfers after preoperative irradiation in head and neck reconstruction. *Acta Otolaryngol Suppl.* 1997;529:247–250.
- Jose B, Banis J, Flynn M, et al. Irradiation and free tissue transfer in head and neck cancer. *Head Neck.* 1991;13:213–216.
- Wei FC, Demirkan F, Chen HC, et al. The outcome of failed free flaps in head and neck and extremity reconstruction: what is next in the reconstructive ladder. *Plast Reconstr Surg.* 2001;108:1154–1160.
- Urken ML, Weinberg H, Buchbinder D, et al. Microvascular free flaps in head and neck reconstruction: report of 200 cases and review of literature. *Arch Otolaryngol Head Neck Surg.* 1994;120:633–640.
- Hidalgo DA, Disa JJ, Cordeiro PG, et al. A review of 716 consecutive free flaps for oncologic surgical defects: refinement in donor-site selection and technique. *Plast Reconstr Surg.* 1998;102:722–732.
- Finical SJ, Doubek WG, Yogueros P, et al. The fate of free flaps used to reconstruct defects in recurrent head and neck cancers. *Plast Reconstr Surg.* 2001;107:1363–1366.
- Yamamoto Y, Nohira K, Kuwahara H, et al. Superiority of end-to-side anastomosis with the internal jugular vein: the experience of 80 cases in head and neck microsurgical reconstruction. *Br J Plast Surg.* 1999;52:88–91.
- Ueda K, Harii K, Nakasuka T, et al. Comparison of end-to-end and end-to-side venous anastomosis in free-tissue transfer following resection of head and neck tumors. *Microsurgery.* 1996;17:146–149.
- Delacure MD, Kuriakose MA, Spies AL. Clinical experience in end to side venous anastomoses with a microvascular anastomotic coupling device in head and neck reconstruction. *Arch Otolaryngol Head Neck Surg.* 1999;125:869–872.
- Zhang F, Ho PO, Chin BT, et al. Effect of vein grafting on the survival of microvascularly transplanted muscle. *Microsurgery.* 1996;17:512–516.
- Miller ML, Schusterman MA, Reece GP, et al. Interposition vein grafting in head and neck reconstructive microsurgery. *J Reconstr Microsurg.* 1993;9:245–252.
- German G, Steinau HU. The clinical reliability of vein grafts in free flap transfer. *J Reconstr Microsurg.* 1996;12:11–17.
- Albertengo JB, Rodriguez A, Buncke HJ, et al. A comparative study of flap survival rates in end-to-end and end-to-side microvascular anastomosis. *Plast Reconstr Surg.* 1981;67:194–199.
- Kroll SS, Schusterman MA, Reece GP, et al. Choice of flap and incidence of free flap success. *Plast Reconstr Surg.* 1996;98:459–463.
- Nahabedian MY, Tufaro A, Manson PN. Improved mandible function after hemimandibulectomy, condylar head preservation, and vascularized fibular reconstruction. *Ann Plast Surg.* 2001;46:506–510.
- Khouri RK, Cooley BC, Kunselman AR, et al. A prospective study of microvascular free-flap surgery and outcome. *Plast Reconstr Surg.* 1998;702:711–721.
- Khouri RK. Avoiding free flap failure. *Clin Plast Surg.* 1992;19:773–781.
- Kanoh N, Dai CF, Ikeda N, et al. Parameters for the preoperative evaluation of arteriosclerosis for free flap transfers in head and neck surgery. *Clin Otolaryngol.* 2000;25:135–138.
- Nagler RM, Braun J, Daitzman M, et al. Spiral CT angiography: an alternative vascular evaluation technique for head and neck microvascular reconstruction. *Plast Reconstr Surg.* 1997;100:1697–1701.
- Harris JR, Seikaly H, Calhoun K, et al. Effect of diameter of microvascular interposition vein grafts on vessel patency and free flap survival in the rat model. *J Otolaryngol.* 1999;28:152–157.
- Lopez-Monjardin H, de la Pena-Salcedo JA. Techniques for management of size discrepancies in microvascular anastomosis. *Microsurgery.* 2000;20:162–166.
- Hopewell JW, Calvo W, Campling D, et al. Effects of radiation on the microvasculature: implications for normal tissue damage. In: Vaeth JM, Meyer JL, eds. *Frontiers in Radiation Therapy and Oncology.* Basel: Karger; 1989;23:85–95.
- Hopewell JW, Calvo W, Jaenke R, et al. Microvasculature and radiation damage. *Recent Results Cancer Res.* 1993;130:1–16.
- Hallok GG. The interposition arteriovenous loop revisited. *J Reconstr Microsurg.* 1988;4:155–159.
- Taub PJ, Chun JK, Zhang WX, et al. Staging arteriovenous fistula loops for lengthening of free-flap pedicles. *J Reconstr Microsurg.* 1999;15:123–125.
- Angel MF, Chang B, Clark N, et al. Further clinical use of the

- interposition arteriovenous loop graft in free tissue transfers. *Microsurgery*. 1993;14:479–481.
43. Rand RP, Gruss JB. The saphenous arteriovenous fistula in microsurgical head and neck reconstruction. *Am J Otolaryngol*. 1994;15:215–218.
 44. Sorensen JL, Muchardt O, Reumert T. Temporary arteriovenous shunt prior to free flap transfer. *Scand J Plast Reconstr Hand Surg*. 1990;24:43–46.
 45. Yenidunya MO, Yenidunya S, Suse T, et al. Different types of arteriovenous anastomoses between femoral artery and vein distal to the island groin flap. *J Reconstr Microsurg*. 2002;18:301–307.
 46. Fillinger MF, Kerns DB, Bruch D, et al. Does the end-to-end venous anastomosis offer a functional advantage over the end-to-side venous anastomosis in high-output arteriovenous grafts. *J Vasc Surg*. 1990;12:676–688.
 47. Bas L, May JW, Handren J, et al. End-to-end versus end-to-side microvascular anastomosis patency in experimental venous repairs. *Plast Reconstr Surg*. 1986;77:442–450.
 48. Beckman JA, Thakore A, Kalinowski BH, et al. Radiation therapy impairs endothelium-dependent vasodilation in humans. *J Am Coll Cardiol*. 2001;37:761–765.
 49. Bernstein EF, Sullivan FJ, Mitchell JB, et al. Biology of chronic radiation effect on tissues and wound healing. *Clin Plast Surg*. 1993;20:435–451.
 50. Drake DB, Oishi SN. Wound healing considerations in chemotherapy and radiation therapy. *Clin Plast Surg*. 1995;22:31–37.
 51. Schultz-Mosgau S, Grabenbauer GG, Wehrhan F, et al. Histomorphological structural changes of head and neck blood vessels after pre- or postoperative radiotherapy. *Strahlenther Onkol*. 2002;178:299–306.
 52. Aitasalo K, Relander M, Virolainen E. The success rate of free tissue transfer after preoperative irradiation in head and neck reconstruction. *Ann Chir Gynaecol*. 1997;86:311–317.
 53. Nahabedian MY, Deune EG, Manson PN. Utility of the lateral arm flap in head and neck reconstruction. *Ann Plast Surg*. 2001;46:501–505.