

Oncoplastic Breast Surgery and the Effects of Radiation Therapy

Navin K Singh • Anu M Singh

Background

Breast cancer is one of the most common cancers and the second leading cause of cancer mortality in US women. Breast malignancy accounts for nearly one in three cancers diagnosed in women in the United States. Hence much attention and resources have been directed at this disease – from attempts at prevention, to screening, treatment, and cure. Approaches range from the infinitesimal to the global, analyzing molecular markers of gene expression such as HER-2/neu, genetic-based testing and screening such as BRCA 1 and 2, familial analyses, hormonal assays, population studies, and vaccine trials.

While the incidence of breast cancer continues to increase, fortunately mortality is starting to decline because of earlier detection prior to distant spread, attributable to the unequivocal success of mammographic screening efforts, as well as advances in management. With approximately 182 000 cases expected in 2008, the public health impact estimates are between \$5 and \$8.1 billion dollars annually spent on managing breast cancer. This expansive clinical volume has created a body of evidence that has been gathered, reviewed, published, and disseminated, leading to a decline in mortality from breast cancer over the last few decades.

Owing to research efforts directed at breast cancer, breast management has undergone significant evolutions in management – from the Halsted radical mastectomy to the modified radical mastectomy to breast conservation therapy combined with radiation. Paralleling these paradigmatic changes in oncologic management have been shifts and changes in the reconstructive algorithms to reconstruct breast cancer defects, whether they be mastectomy or partial defects.

To maximally benefit the patient with breast cancer seeking treatment, the complex interplay of radiation and plastic surgery must be thoroughly understood to offer the most appropriate treatments in the most appropriate sequence with the best anticipation of the likely outcomes. This requires an understanding of the physics, mechanisms of actions of radiobiology, and pathophysiology associated with radiation and with wound healing.

The goals for oncoplastic breast surgery and radiation are (1) tumor eradication, (2) prolonging survival, and (3) maximizing quality of life via cosmetically acceptable breast preservation, or breast reconstruction to a close facsimile of the original. Data from the Early Breast Cancer Trialists' Collaborative Group (EBCTCG) indicates that not only is there improvement in local control, but also an absolute survival benefit of approximately 5% in women who receive radiation.

Oncoplastic breast management exists at the nexus of four disciplines – surgical oncology, plastic surgery, radiation oncology, and medical oncology – and the timing, efficacy, and role of each of these modalities must be

considered concomitantly. Often a tumor board or multidisciplinary breast center is a good forum to brainstorm and create a management plan which resonates with the expertise that is brought to bear from each specialty and with the patient's goals, expectations, lifestyle, and particular tumor grade, histopathology, stage, genetics, and oncotype in mind.

Role of radiation

Radiation therapy has two principal roles in the management of breast carcinoma. It can be combined with lumpectomy as part of breast-conserving therapy (lumpectomy + XRT) or be utilized as adjuvant treatment for post-mastectomy treatment (PMRT). The specific removal of a breast tumor with an adequate margin is interchangeably called lumpectomy, quadrantectomy, or tumorectomy. The discussion in this chapter is limited to these two roles, although radiation might be used for palliation to mitigate symptomatology from an incurable lesion such as ulceration, bleeding, or pain either in the breast or at a metastatic site.

Basic science and biology

Radiation therapy is the use of ionizing energy to control malignancy. The energy (interpretable as high-speed particles or electro-magnetic waves) is targeted to the tumor and a surrounding zone of normal tissue to kill cancer cells preferentially.

The unit of measurement in radiation is the gray (Gy), the absorbed dose of 1 joule of radiation energy by 1 kilogram of matter, and may be used to denote any type of radiation. It does not describe the biological effect of that 1 joule in that 1 kilogram. The sievert (Sv) describes the biologically equivalent dose by a multiplier Q for the quality of radiation. For gamma and X-radiation, both of which are types of photons, $Q = 1$ and a sievert is equivalent to a gray:

One gray [$1 \text{ Gy} = 1 (\text{J/kg}) = 1 \text{ m}^2 \text{ s}^{-2}$] is equivalent to 100 rads

Radiation is administered for adjuvant purposes (that is, when all known detectable disease has been resected) in breast cancer, and occasionally in palliation as well. It is not used with curative intent as the sole modality. Gamma rays and electrons are used commonly, but X-rays are never utilized in therapeutic radiation oncology.

Radiation fields include a surrounding zone of normal tissue to control for tumor motion such as respiration or shift of skin marker alignment, variation in motion, and daily set-up. The ionizing injury from radiation serves to cause irreparable damage to the DNA of rapidly dividing cells – typically malignant cells since they lack an intact repair mechanism. Some collateral damage is suffered by other rapidly dividing cells such as

epithelial structures. During the simulation phase of treatment planning, relatively fixed points of skin are tattooed to help align the radiation portal. A significant proportion of women may want these excised after XRT is completed, but they should be encouraged to retain these so that overlapping fields of XRT can be avoided should future contralateral radiotherapy be needed.

A typical treatment course is 5 days a week for 5–6 weeks for a total radiation dose of 5000 cGy (50 Gy) to the entire breast by tangential beams to eradicate microscopic disease, with a boost to the tumor bed of approximately 1000–2000 cGy (10–20 Gy). There is fairly solid consensus about the utility of the local boost, and the European Organization for Research and Treatment of Cancer (EORTC) has reported on improved local control with a boost since most recurrences are seen at the primary site. This fractionation, called postoperative fractionated radiotherapy, remains the standard method for conservative treatment of breast carcinomas.

Typical results in breast radiation are mild signs of skin changes and mild volume asymmetry related to atrophy and lumpectomy resection, as seen in **Figure 12.1**.

The collateral damage to non-cancer dividing cells causes both the acute sequelae and the long-term sequelae of radiation. Short-term sequelae include skin edema, which typically disappears in 12–24 months. Skin adnexal structures such as sebaceous glands and hair follicles may be irreversibly lost, causing dry skin and fissuring. The incidence of radiation dermatitis is as high as 90%, although the majority of instances are relatively mild and well tolerated. Treatment is supportive via the use of antibiotics, emollients, and analgesics. Dry desquamation arises from XRT damaging the basal stem cells in the deep layer of the epidermis, which create the cornified layer of the epidermis. It is shedding of the cornified layer. If the

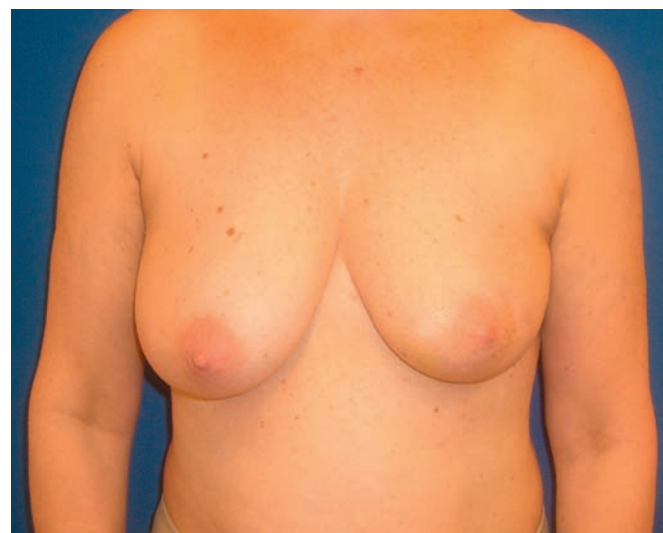


Figure 12.1 Patient underwent left BCT with radiation therapy and had a cosmetically salutary result with only subtle differences from the contralateral breast. She developed a recurrence, years later.

basal layer is further destroyed and the dermis is exposed, then moist desquamation develops.

Morbidity is exacerbated in obese patients, diabetics, smokers, and those with previous radiation.

Long-term sequelae are progressive atrophy, telangiectasias, hyperpigmentation, impeded wound healing because of loss of precursor cells in a radiated field, fibrosis, and loss of volume (**Fig. 12.2**). Lymphedema may occur from either axillary dissection or from fibrosis of lymphatic channels post radiation (**Fig. 12.3**). It may involve the chest wall or arm. Higher at risk are the obese and those with full axillary clearance. The incidence of lymphedema approaches approximately 9–14%. Treatment is compression garments and avoiding procedures

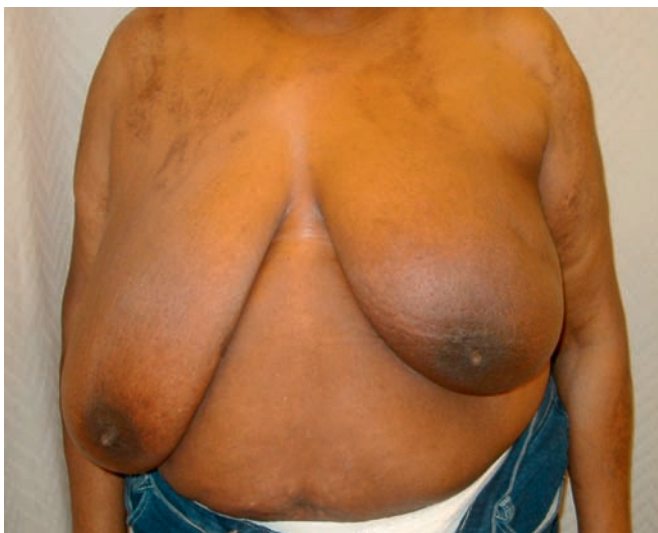

Figure 12.2 This woman was likely not an ideal candidate for BCT and would have benefited from an oncoplastic breast reduction with lumpectomy initially. She presented after lumpectomy and radiation therapy on her left breast, with complaints of asymmetry.

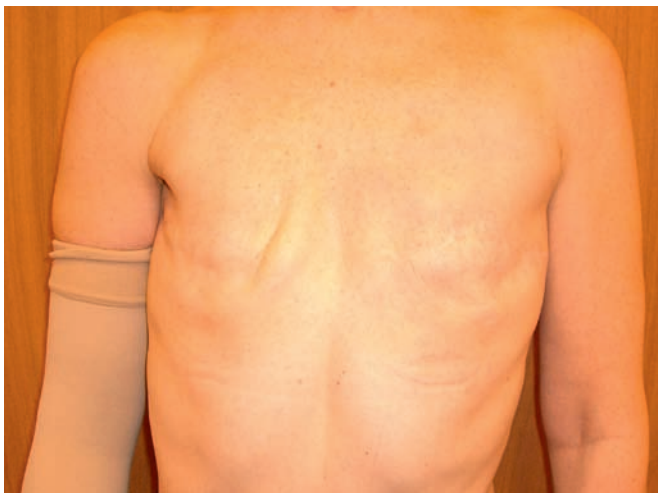

Figure 12.3 Patient is s/p bilateral mastectomy and right sided radiation. Right-sided lymphedema related to radiation and lymph node dissection is managed conservatively with compression garments.

in the affected arm such as blood pressure measurements and phlebotomy. Conservative measures such as compression stockings, and manual lymphatic drainage, suffice. Rarely, lymphatic reconstruction or bypasses can be done using microvascular techniques.

Skin hyperpigmentation arises from superficial migration of melanocytes and may be permanent after a few years. Fatigue is common. Rib weakening or fractures may occur, especially with tissue expanders being constrained by indurated skin. Fractures can be diagnosed by plain film or bone scan. A pathologic fracture related to bony metastasis must be ruled out. Treatment is conservative, allowing the bone to heal with rest and supportive measures.

Pain and limitation in range of motion at the shoulder may be related both to the surgical resection, axillary dissection, and radiation. Physical therapy is routinely prescribed and most patients regain the full range of their routine motions.

Induced malignancy may develop post radiation, and may occur as frequently as 7–8%. Studies indicate a 1% absolute increase in second non-breast malignancies associated with XRT, such as lymphangiosarcoma, lung cancer, and sarcomas.

Radiation pneumonitis may develop in 1–7% of patients and is manifested as a dry cough and/or low-grade pyrexia. Pericarditis and coronary damage remain largely theoretical concerns. There are concerns that radiotherapeutic treatment of the left breast (and left-sided breast cancer is slightly more common than right-sided breast cancer) can cause coronary fibrosis and sclerosis. This was seen with older technologies, and current planning techniques minimize the coronary risk of radiation. The risk bears mentioning, especially since many chemotherapeutic regimens used to manage breast cancer deliver cardiotoxic medications as well (e.g., adriamycin and herceptin). Further, breast reconstruction with a free flap may harvest the internal mammary vessels as donor vessels, and render them inaccessible for future coronary revascularization – a theoretical limitation since much coronary artery disease is treated via angioplasty, stents, or vein grafts. While breast cancer is the most common cancer in women, the leading cause of mortality in US women is still coronary artery disease.

Breast-conserving treatment

Indications

Overall, 65% of breast cancers are classified as early stage (1 and 2) and three-quarters are eligible for BCT, or about half of all breast cancers. Of those that are eligible for BCT, about 20% choose to have a mastectomy.

In 1985, NSABP-B06 (The National Surgical Adjuvant Breast and Bowel Project) demonstrated that BCT provides equivalent 5-year survival rates when compared with modified radical mastectomy for the treatment of early breast cancer. BCT rates range from 10% to 50% of

eligible patients, and depend on a plethora of factors such as referral patterns, presence of a multidisciplinary team, education level of patients, and prevailing cultural norms. Patient satisfaction rates range from 75% to 95% but many women note significant asymmetries. Up to 30% may benefit from corrective surgery. In addition to randomized control trials comparing lumpectomy + XRT with mastectomy, there are good randomized trials comparing lumpectomy alone with lumpectomy and radiation. Lumpectomy has a local recurrence rate of 30–40% at 5 years, which drops to 10% when combined with radiation. A recent meta-analysis of 10 randomized trials showed an absolute reduction in recurrence rates of approximately 17% with radiation. The cultural zeitgeist now is overwhelmingly breast preservation.

- *Early-stage tumor.* Randomized controlled trials have demonstrated the safety for Stage 1 and 2 tumors. Even certain Stage 3 tumors, depending largely on tumor size, are candidates for BCT.
- *Small tumor.* There is theoretically no upper limit on size, so long as negative margins can be obtained through a non-deforming excision. However, larger tumor volumes may be considered unsuitable because of concerns for margins. Further imaging is indicated to rule out other foci of disease, and additional image-guided biopsies may be needed to address the matter conclusively before proceeding with BCT.
- *Unifocal disease.* Previously, an extensive intraductal component (EIC) was felt to be a poor prognosticator for the success of BCT; however, so long as margin control is obtained during lumpectomy, unifocal disease, even with an EIC, is an indication for BCT. EIC was first described by the Joint Center for Radiation Therapy as DCIS with an invasive component or DCIS comprising 25% of an invasive tumor with DCIS in surrounding parenchyma. It no longer precludes BCT.
- *Patient preference.* The patient must be motivated to preserve the breast. Most patients who are candidates for BCT do opt for it; however, a fifth of the eligible patients opt for a mastectomy.
- *Previous cosmetic breast augmentation.* Prior augmentation mammoplasty is not a contraindication, and the implants do not have to be removed. This applies equally to whether the implants are submuscular or subglandular.

Contraindications

Certain conditions make BCT untenable because of unacceptable consequences associated with radiation. While every rule has its exception, there is broad consensus in the following contraindications. Some of these are relative contraindications in view of the caveats mentioned.

- *Inability to obtain uninvolved margins.* Certain tumors may be extensive enough or close enough to the

chest wall that adequate clearance with negative margins is not feasible with a lumpectomy. When all detectable disease cannot be eradicated, then BCT is not offered.

- *Inadequate cosmesis.* The goal of BCT is breast conservation, and so if the likely outcome of a lumpectomy is going to be distortion and poor cosmesis, patient dissatisfaction is likely (Fig. 12.4). Particularly when a small breast with a proportionately large resection is anticipated, mastectomy might be a more palatable alternative. Other situations where disappointing appearance is likely are subareolar position of the tumor or where the excision will create a poor scar orientation. A recent study shows that approximately 25% of women who have undergone BCT + XRT will be sufficiently displeased with the aesthetic outcome as to warrant a plastic surgery referral. Axillary dissection did not impact the cosmetic outcome.
- *Prior radiation.* If portions of the chest or breast have been previously radiated for breast cancer or received mantle radiation (e.g., for Hodgkin's lymphoma), then the woman is ineligible for BCT + XRT. If total body dose is likely to be exceeded, then the patient is also ineligible for BCT. Should the total tolerable dose of the breast, skin, and chest wall be exceeded, skin breakdown, ulceration, and irreversible radiation injury may result. Additional, focal radiation might be considered in certain specific scenarios nevertheless.
- *Locally advanced tumors or inflammatory breast cancer.* These processes are not felt to be treatable with BCT because of their aggressive nature and high likelihood of failure of local control.
- *Logistics.* Patient preference and autonomy must be respected. In medicine, the ossified model of

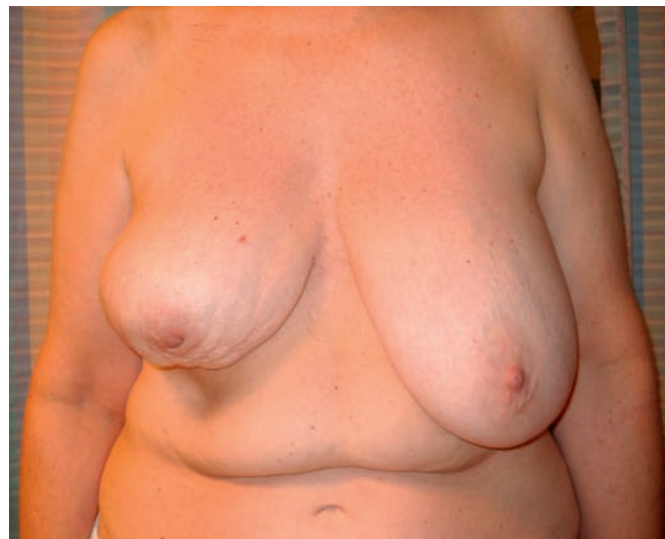

Figure 12.4 This woman had right BCT and over time greater asymmetries have developed. A recurrence was discovered warranting right mastectomy.

paternalism is giving way to joint decision making. Some patients will have sound reasons to prefer BCT or mastectomy, and even when the reasons do not appear so sound to the physicians involved, the competent patient must be the master of her course. Socioeconomic situations including lack of resources to travel to a radiation center, inability to get transportation, and/or competing obligations may lead a woman to choose mastectomy rather than BCT. Interestingly, inability to tolerate lying on a radiation table due to arthritis, injury, or spinal deformities (e.g., kyphoscoliosis) may similarly make a patient a non-candidate for BCT.

- *Collagen vascular disorders.* Active scleroderma or lupus creates concerns for adverse skin and soft tissue toxicity if irradiated. Typically, such a patient should be excluded from BCT and offered mastectomy for disease management. The patient with rheumatoid arthritis is not a contraindication.
- *BRCA status.* Women from strong familial disease lines and/or those tested positive for the BRCA genes should be counseled regarding risk-reducing strategies. If they will consider a contralateral prophylactic mastectomy at some point in the future, it may not be appropriate to receive BCT and accept the side effects of XRT only to have the breast removed in the future. This remains a controversial topic and studies about the efficacy of BCT in women with germline mutations in BRCA 1 or BRCA 2 are equivocal because, although in-breast recurrence is unlikely, new spontaneous tumors in the same or contralateral breast are likely.
- *Pregnancy.* Radiation is to be avoided in the gravid woman because of the significant risks to the developing embryo, which has a low tolerance to the mutagenic effects of radiation, despite the radiation scatter being expected to be low. The risks of radiation-induced malignancy are increased in the fetus exposed to intrauterine radiation.
 - *Caveat.* Nonetheless, if the mother is far enough along in the gestation that she can have a lumpectomy and nodal dissection and commence radiotherapy post partum, it may be feasible to offer BCT + XRT to a pregnant patient. Data indicate that starting radiotherapy up to 10 weeks post surgery is still effective at local control.
- *Multicentric disease.* When two or more separate foci are present, then this may represent a challenge for resecting the lesions without unacceptably deforming the breast or leading to a high-proportion excision of a small-volume breast.
 - *Caveat.* However, if all the tumor(s) are in the same quadrant and are resectable through the same incision with negative margins, then BCT may be offered.

- *Large breasts.* Radiation oncologists have maintained that large pendulous breasts are not suitable for radiation because of the great inhomogeneity in dosage, inconsistent positioning because of skin variability and motion, and poor penetrance through the parenchyma. Furthermore, the large contralateral breast may actually interfere in the beam angles and approaches to deliver radiation to the involved breast. Often these women have been steered towards mastectomy. Figure 12.2 represents a patient who is not an ideal candidate for BCT.
 - *Caveat.* However, bearing in mind oncologic principles, these women might be converted into candidates if tumorectomy can be performed through a breast reduction pattern and a contralateral symmetry reduction performed concomitantly. When a breast reduction pattern is utilized, as described elsewhere in this book, one must adhere to oncologic principles of leaving radio-opaque clips in the tumor bed, individualizing the resection pattern to ensure tumor removal, choosing an appropriate flap pedicle to ensure vascularity of the remaining parenchymal tissues, and obtaining a preoperative contralateral screening mammogram. Additional oncologic concepts include centralizing the nipple–areola complex, closing the glandular defect by undermining the skin, opposite breast shaping, use of incisions along the junction of aesthetic units such as in the inframammary crease, periareolar region, or the breast meridian.

Predictors of recurrence

The goal of BCT + XRT is to control the risk of local recurrence of breast carcinoma. While late recurrences may occur, 75% of recurrences will occur within 5 years. Late local recurrence has been reported even decades after original BCT. Radiation is a local therapy, and does not provide systemic control, only local control. Certain features of the original tumor enhance the risk of recurrence.

- *Multifocal disease.* Cancer encompassing more than one quadrant of the breast does increase the risk of recurrence. However, it is not an absolute contraindication.
- *Lymphovascular invasion.* Histologically, lymphovascular invasion indicates a tumor biology which is at higher risk for recurrence.
- *Positive or close margin.* The role for radiation as adjuvant therapy is to control recurrence once all detectable disease is excised. Hence, a positive margin should be surgically addressed whenever feasible. A close margin should be considered for further excision if this can be accomplished surgically without distortion of the breast.

- *Extensive intraductal component.* This may be a marker for in-duct spread of tumor and, so long as margins are negative, EIS is not an absolute contraindication for BCT. It does place the patient at higher risk for local failure.

Factors that are not predictors of recurrence include estrogen receptor status, histologic grade, nodal status, and HER2/neu expression. Women with BRCA 1 or BRCA 2 are not at high risk for local in-breast recurrence, so long as they are otherwise good candidates for BCT. However, those preferring a contralateral prophylactic mastectomy as a risk reduction strategy would be better served with a mastectomy. **Figure 12.5** depicts the same patient as in Figure 12.1, who had a good outcome with left BCT and now does have a recurrence. Although not BRCA positive by testing but with a not insignificant family history of cancer, she elected for right prophylactic mastectomy and left mastectomy for recurrent disease. Interestingly, the previously radiated side did not need a mastopexy because of skin tightening from radiation, but the right prophylactic side did need a vertical pattern mastopexy.

Post-mastectomy radiation therapy

Indications

A survival benefit is conferred by administering radiation to those women undergoing a mastectomy who have greater than three lymph node involvement. There is significant survival benefit and local control benefit conferred by PMRT for advanced disease. The criteria are being broadened, emboldened by the increasing safety of radiation therapy, and in certain situations PMRT is utilized in women with only one to three positive axillary nodes. A survival benefit is shown from the EBCTCG meta-analysis data, and the fields of radiation should include chest wall, supraclavicular, and internal mammary nodes. There are increasing data to suggest that internal

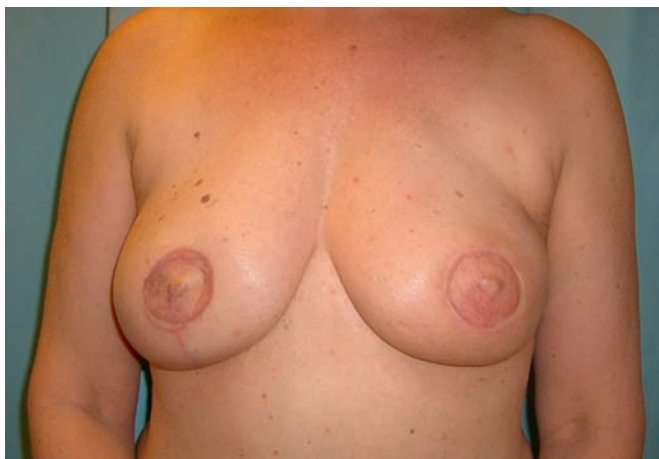

Figure 12.5 Patient shown in Figure 12.1 now undergoes a left therapeutic mastectomy, right prophylactic mastectomy, and bilateral immediate free DIEP flap reconstruction.

mammary lymph node irradiation is important in those with clinically negative axillae, and even more so in those with clinically positive axillae, although some practitioners include the internal mammary nodes only for medial tumors.

Contraindications

Certain overall patient characteristics make them unsuitable for PMRT.

- *Prior radiation.* Exceeding the total allowable dose can create injurious results such as osteoradionecrosis, ulceration, rib fractures, and secondary malignancies.
- *Patient unwillingness.* Even when evidence-based guidelines indicate an absolute survival benefit associated with PMRT, a patient may decline treatment for a variety of factors, rational or irrational. Some patients have great fear about radiation and its effects on the lung or heart, its ability to induce secondary tumors, and its potential effects on the cosmesis of the reconstruction. The patient and her family have to assess their risk aversion in the context of the data available as it applies to their particular scenario.
- *Collagen vascular disorders.* The patient with active lupus or scleroderma is susceptible to accelerated damage from radiation and should be extensively counseled regarding the role of radiation in the overall management of the breast cancer.
- *Pregnancy.* As previously discussed for BCT, post-mastectomy radiation can be initiated up to 10 weeks after surgery with equal efficaciousness. It should not be delivered until the patient is post partum.

Treatment modalities

Over the last 20 years, dramatic improvements in technique and technology have delivered better oncologic endpoints and outcomes. While in BCT whole breast irradiation is the norm, there are some other alternatives that are being trialed and gaining acceptance. Partial breast irradiation (PBI) and accelerated partial breast irradiation (APBI) are being advanced as a way to minimize the 5- to 7-week commitment of the patient to the radiation center, while delivering a biologically effective dose. They deliver radiation into the tumor bed and immediate surrounding tissues, since this is the at-risk zone for tumor reappearance.

PBI methods may be teletherapy or brachytherapy. PBI may be 5 days of twice daily for 15 once-daily fractions, depending on the modality.

Teletherapy

- *Intraoperative tele-radiation therapy.* At the time of lumpectomy, the patient can be treated with a single large fraction of radiation via photons or electrons

prior to wound closure. Intraoperative RT has been reported on with 4-year follow-up with no major side effects and an in-field recurrence rate of 0.5%, from the European Institute of Oncology. It was reported in a retrospective study of 355 patients who were not suitable candidates for traditional postoperative XRT and were treated instead with the use of full-dose intraoperative radiotherapy with electrons (ELIOT) in advance of long-term results of ongoing clinical trials, as the sole radiotherapy for patients with unifocal invasive carcinoma who were candidates for BCT. The typical dose was 21 Gy intraoperatively, biologically equivalent to 58–60 Gy in standard fractionation.

ELIOT may be an emerging option for those women who cannot tolerate traditional fractions because of increased susceptibility of their skin, subcutaneous tissue, and contralateral breast and lung from pre-existing morbidities.

- *Postoperative tele-radiation therapy*
 - *Intensity-modulated radiation therapy (IMRT)* has shown improved dose homogeneity and local control equivalent to traditional therapy in the setting of BCT. Static multileaf collimator (sMLC) IMRT technique has been reported in a trial of 281 patients where 56% experienced Radiation Therapy Oncology Group Grade 0 or I acute skin toxicity; 43% developed Grade II acute skin toxicity and only 1% experienced Grade III toxicity. The cosmetic results at 12 months were excellent/good in 99% of the patients. No skin telangiectasias, significant fibrosis, or persistent breast pain was noted. This greater uniformity helps with potential reduction in acute and chronic toxicities while maintaining the efficacy of breast irradiation.
 - *3D conformal methods* show promising results in Phase I and II trials. The planned target volume is the tumor bed plus a 1–2 cm margin defined at post-mastectomy CT. A regimen of five fractions over 10 days is typically performed with total dose range of 25–30 Gy. Cosmesis and tumor control results appear encouraging from early reports.

Brachytherapy

- *Interstitial brachytherapy.* Hollow catheters are inserted through the parenchyma at the time of the lumpectomy, and after simulation these are loaded with a radioactive source, usually iridium-192, via a remote loader. Currently in Phase I/II protocol at Tufts, dose was prescribed to the tumor bed plus a 2 cm margin and a total of 3400 cGy was delivered in 10 fractions twice daily over 5 days. Toxicities (skin, subcutaneous tissue, pain, fat necrosis) were evaluated by Radiation Therapy Oncology Group

criteria; cosmesis was assessed using a previously published scale. The actuarial local recurrence rate was 6.1% at 5 years. Fat necrosis was not seen in the first 6 months after treatment, and then plateaued at 18%. Moderate to severe subcutaneous toxicity was seen in 35.7% of patients. The percentage of patients with less than excellent cosmetic outcomes was about 20%. Other trials have used cesium-137 as the radioactive seed instead of iridium-192.

- *Intracavitary brachytherapy.* An example is Mammosite (Cytec Corporation, Marlborough, MA) whereby a double-lumen balloon catheter is placed at the time of surgery. For a period of 5 days, a computer-controlled high-dose rate HDR machine inserts a radiation ‘seed’ (iridium-192) to deliver the brachytherapy, and the seed is withdrawn between treatments. On the fifth day, the balloon is removed through the same incision.

A recent study from Rush Medical Center of 70 patients with at least 6 months follow-up showed a crude failure rate of about 7%. Another study reported on 5-year results of 70 prospective enrollees, of whom only 43 patients completed accelerated partial breast irradiation with Mammosite brachytherapy. A dose of 34 Gy was delivered in 10 fractions over 5 days. In some patients cavity size was not amenable to balloon placement or for skin spacing. The infection rate was 9.3% and the seroma rate 32.6%. Good–excellent cosmetic outcomes were achieved in 83.3% of the 36 patients with more than 5 years of follow-up. There were two serious infections. No contralateral cancers developed.

In a subsequent report with 1400 patients, breast seromas were reported in 23.9% of cases (symptomatic in 10.6% of cases), and 1.5% of cases developed fat necrosis. With a median follow-up of 37.5 months, the 3-year actuarial rate of in-breast tumor recurrence was 1.79%.

These early reports highlight the importance of proper patient selection for this evolving technique.

Timing and types of reconstruction

Breast reconstruction is a challenging art because the reconstruction must simultaneously be sensual, soft, a commensurate size to the patient, and symmetric with the opposite breast in unilateral cases. These goals are routinely realizable by tailoring the method to the patient’s lifestyle, preferences, and donor site availability. The two broad categories of reconstruction are autologous or implant based. Both of these become yet more nuanced once radiation – either previous or anticipated – enters the picture.

Operating on radiated structures is predictably unpredictable. We can anticipate longer time to ultimate healing, beyond the usual 6 weeks, since every step of the healing cascade is retarded. Flap undermining should be

limited since the conventional length:width ratios will be altered. The skin and underlying musculofascial layers are typically woodier, indurated, and have diminution of their viscoelastic properties such as stress relaxation and creep. Telangiectasias, even if not appreciated on the skin prior to incision, will become manifest, and prolonged erythema may present, often confused and treated as cellulitis. There will be variable degrees of fat necrosis in undermined and elevated tissues as well. Because of great variability in patient response to radiation, while these changes can be foreseen, the magnitude of the changes is not predictable, hence caution is advised.

Unfortunately, the aesthetic results are variable as well. Radiated tissue, because it will not be as pliant as non-radiated tissue, throws plans and predictions out of the well-worn grooves of plastic surgery. For instance, in a typical breast reduction the plastic surgeon would anticipate and compensate for 'bottoming-out' and for scars and shape to 'settle-out'. In a post-radiation breast reduction, 'bottoming-out' occurs to a much lesser degree and the aesthetic result of a unilateral breast reduction can be quite stellar. However, the non-radiated breast will experience 'settling-out', thus creating ongoing asymmetry since the two breasts will take dramatically different healing trajectories and paths. **Figure 12.6** demonstrates a patient with a bilateral reduction and their different healing patterns, and is the same patient shown in Figure 12.2. This experience is further amplified in vertical pattern mastopexies and reductions because the subtle challenges of this relatively novel technique are further exacerbated.

So challenging can be the sequelae of radiation injury that sometimes an appropriate method is to 're-create the defect'. Research from Institut Curie in Paris, France, indicated that for unacceptable cosmetic outcomes in up to 5% of their patients, they would perform a completion

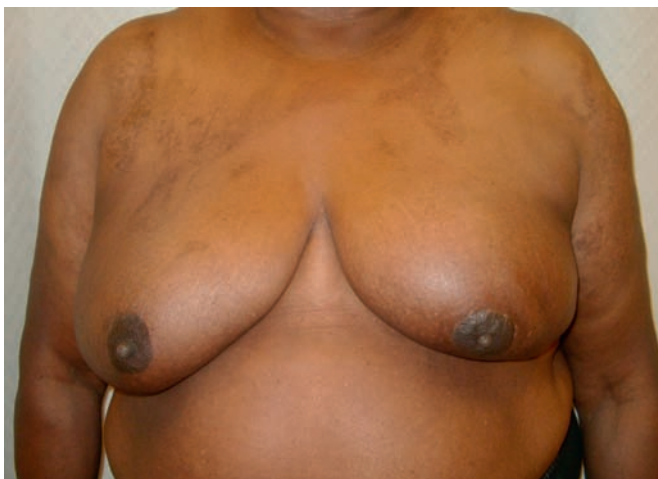

Figure 12.6 Patient shown in Figure 12.2 underwent bilateral breast reduction. The left side pedicle design was modified because of her history of radiation and lumpectomy.

mastectomy and immediate reconstruction for a hostile BCT outcome.

There is no consensus on how long to wait after the conclusion of radiotherapy before attempting an operation. Certainly one should wait until the visible signs of injury such as induration and edema are abating. The timeline has to be tailored to the patient and operation may be performed anywhere from 3 months post XRT to 12–24 months post XRT. This may frustrate the patient's calendar since patients are keen to complete their care.

Whenever feasible, immediate reconstruction delivers a superior cosmetic outcome to delayed reconstruction because the full potential of a skin-sparing mastectomy can be exploited in the reconstruction, independent of whether or not there will be or has been radiation. There will likely be a single scar when immediate reconstruction is used with tissue expanders or with autologous flap reconstruction, whereas in delayed reconstruction using flaps a large patch of skin is added creating more than one visible scar. Whenever possible, these additional scars are placed at the junction of aesthetic units such as periareolar or in the inframammary crease.

The two categories of reconstruction methodologies employed are implants and flaps.

Expander/implant reconstruction

Prior radiation

In the patient who has had a past attempt at BCT and had lumpectomy + XRT, the radiation injury will confound attempts at reconstruction when the patient has a recurrence. The well-established dogma in plastic surgery is that implant-based reconstruction in a previously irradiated chest is going to have a higher complication rate. The incidence of infection will be elevated, as will the incidence of capsular contracture, erosion/exposure of the implant, pain, and asymmetry. **Figures 12.7** and **12.8** show a patient with an initial good outcome with implant reconstruction and PMRT, and then loss of the implant on the left due to infection. **Figure 12.9** shows a patient with severe capsular contracture, and is the same patient shown preoperatively in Figure 12.3 with unilateral lymphedema.

There is immense variability in how patients respond to radiotherapy, and that coupled with the specifics of their mastectomy – such as how thick the skin flaps are, how close the tumor was to the skin, if the patient has other co-morbidities such as diabetes or smoking – will impact on the success or failure of the reconstruction.

Skin margin viability must be assiduously checked because it is notoriously difficult to ascertain from gross inspection. Some surgeons use fluorescein and a Wood's lamp to check perfusion, while others rely on clinical inspection. The pectoralis major muscle may have become atrophic and/or woody and firm from the radiation, and may not mobilize without tearing, and will probably lack the pliability that it ordinarily has. Lower initial volumes

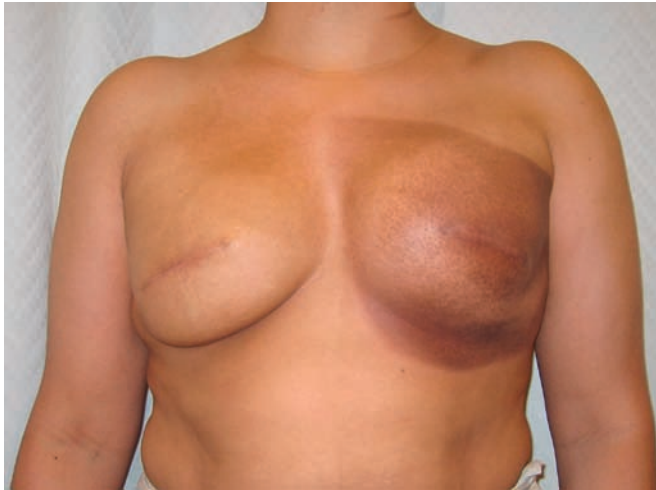

Figure 12.7 This patient underwent left modified radical mastectomy and radiation therapy with implant placement as well as right prophylactic mastectomy and implant placement. Left-sided hyperpigmentation is visible, but no capsular contracture.

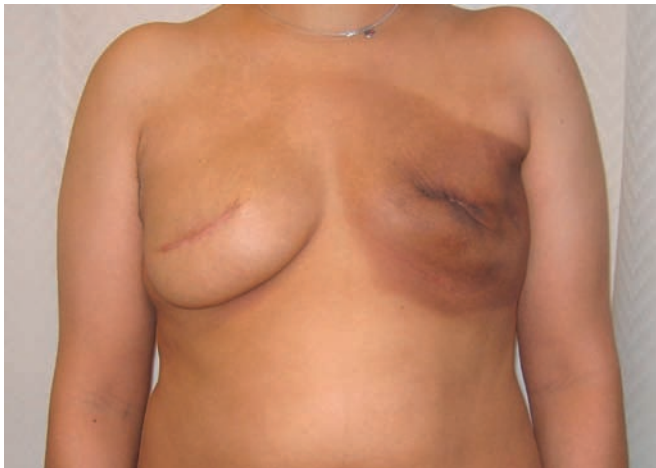

Figure 12.8 In patient shown in Figure 12.7, infection developed in the left breast requiring removal of implant. Implants have higher complication rates in the setting of radiation.

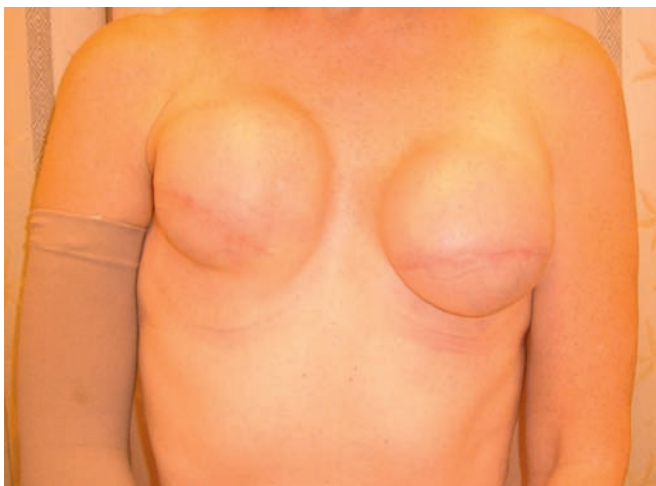

Figure 12.9 Patient shown in Figure 12.3 elected for bilateral implant based reconstruction. Note the right-sided capsular contracture in the setting of prior radiation.

may be placed in the tissue expander, and in-office serial expansions will likely be lower volume and more numerous than in a non-radiated setting.

Planned radiation

Those patients who, based on tumor size, margins, and lymph node status, will proceed with PMRT should be informed that the results obtained with implant-based reconstruction will have limitations in this scenario. Oncoplastic principles dictate that the plastic reconstruction should not delay adjuvant treatments such as chemotherapy and radiotherapy. Hence, the patient will likely proceed with oncologic treatment before she is at full or target expansion. The plan can be placed 'on hold' until those oncologically indicated therapies are complete and the patient has had time to recover. Most expanders have a ferromagnetic integrated port, and so they are not MRI compatible. Any magnetic resonance imaging work-up for the contralateral breast or other body parts should be completed prior to placement of the expander. They do not cause any impediment to radiation therapy, however, since the scatter from the port is clinically insignificant. Rarely, an expander shape interferes with the required vectors to complete radiation planning. In those situations, the expander can be deflated until radiotherapy is completed, and then re-expanded prior to definitive surgery.

Managing complications

The higher incidence of capsular contracture in this situation may have to be managed with over-expansion to retard the constricting effects of the capsule, or with capsulectomies when the expander is exchanged for a permanent implant. There will likely be 'step-offs' where the radiated skin will tend to 'shrink-wrap' down to the underlying chest wall contours, creating a sharp demarcation with the implant in the upper outer pole of the breast. These contour irregularities may be corrected with a biomaterial such as Alloderm acellular human dermis (LifeCell, Branchburg, NJ) or by fat grafts. While autologous fat grafting is gaining acceptance, it remains rife with controversy because of the concerns of fat necrosis causing confusing calcifications in the breast. Local flaps such as a thoracodorsal perforator (TDAP) flap, lateral thoracic flap, or intercostal perforator flaps can be used to recruit vascularized tissue into the defects and ameliorate contour irregularities.

If unyielding complications are present, then the patient may need to be converted to autologous reconstruction.

Autologous flap reconstruction

Prior radiation

If the patient has had prior radiation for an attempt at BCT in the past, reconstruction with autologous tissue, whenever possible, offers the greatest likelihood of a

favorable outcome. Because healthy, well-perfused tissue can be brought into a radiated field, it is likely to heal better and support the radiated tissue. A latissimus dorsi musculocutaneous flap or a thoracodorsal artery perforator flap (based on the same vascularity as the latissimus flap, but sparing the muscle) can utilize some of the tissue laxity along the back. However, one must plan to inspect the source vessels since the patient with a prior mastectomy and/or axillary dissection may no longer have patent thoracodorsal vessels. Secondary retrograde perfusion of the flap from collateral flow from the serratus branch may allow latissimus and TDAP flaps to be used even when the primary pedicle is no longer patent.

Similarly, if a pedicled TRAM flap is performed from the abdomen, it is preferable to base it off the contralateral non-irradiated superior epigastric vessels so that it is not reliant on an irradiated pedicle. In the setting of a free flap (free TRAM, free deep inferior epigastric perforator flap, or free gluteal artery perforator flap) even previously irradiated internal mammary vessels or previously irradiated thoracodorsal vessels are usually sufficient. However, prior radiation does make the dissection more demanding, the vessels slightly more friable, and the success rate of free tissue transfer can be 2–4% lower than when non-irradiated vessels are used. A successful reconstruction, nonetheless, is likely and a skin-sparing mastectomy with immediate free flap reconstruction is demonstrated in **Figure 12.10** and is the same patient demonstrated preoperatively in **Figure 12.4**.

Planned radiation

When autologous tissue reconstruction is planned and the likelihood of the patient receiving PMRT exists (e.g., for multi-node positivity), one can consider either placing

a larger flap to accommodate for future atrophy, or place an expander with planned replacement with flap after completion of XRT. Evidence from the MD Anderson experience indicates that, of those who underwent immediate autologous reconstruction, 24% required an additional flap to correct flap contracture and 22% maintained a normal breast volume. Hyperpigmentation occurred in 37% percent of the patients, 56% were noted to have a firm reconstruction, and loss of symmetry ensued in 78%. The findings were statistically significant when compared with 1443 non-irradiated TRAM patients. At our institution, we most frequently consider a ‘delayed–immediate’ strategy of placing an expander for the duration of the radiation and then, 3–6 months after the conclusion of radiotherapy, removing the expander and performing autologous reconstruction to circumvent the unpredictable volume, contour, and symmetry loss associated with irradiation of flap reconstruction.

Interestingly, at this stage about 15% of our patients will elect to convert the expander to an implant instead of proceeding with a lengthy surgery to perform autologous reconstruction. While the patients are educated about the higher rate of complications in implant-based reconstruction in a radiated bed, they often have favorable outcomes. The remaining 85% do progress to autologous flap reconstruction, and the patient is then treated as someone who has had ‘prior radiation’. In **Figure 12.11** is shown a woman who declined ‘delayed–immediate’ and underwent a mastectomy and PMRT followed by delayed reconstruction. After her reconstruction (**Fig. 12.12**) the flap is warm, soft, and has no fat necrosis, while the surrounding skin remains indurated and telangiectatic. The result is still superior to an immediate flap followed by radiation, but not as good as having an interval ‘space-saving’ expander during PMRT.

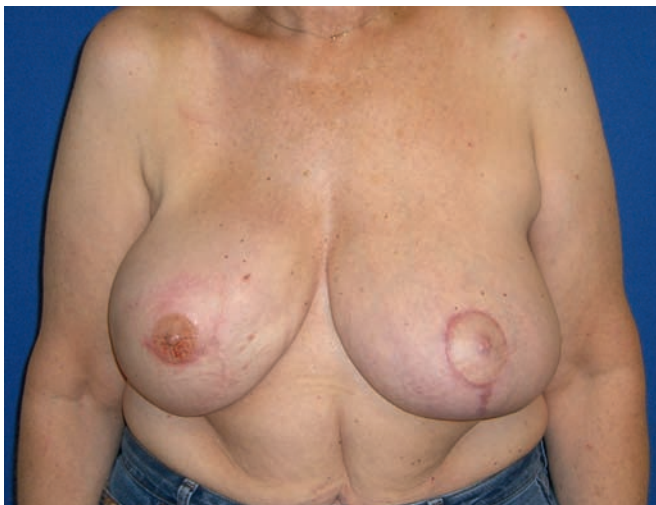

Figure 12.10 Patient shown in **Figure 12.4** underwent right mastectomy with oncoplastic principles to spare the skin envelope and reconstruction with a free DIEP flap. The left breast underwent a reduction for symmetry.

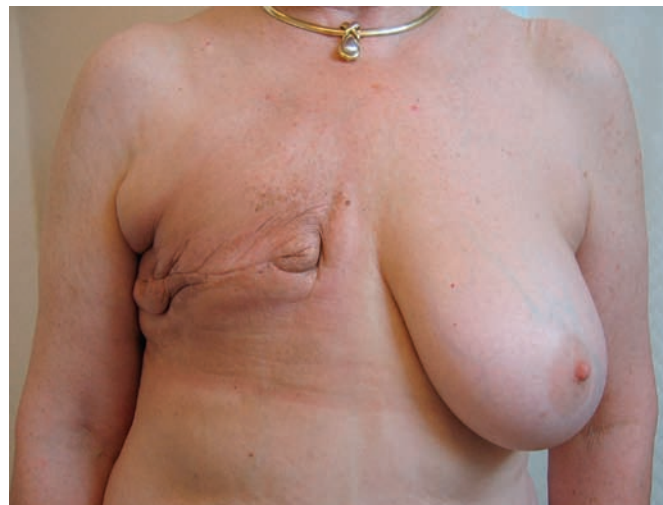

Figure 12.11 Patient shown in **Figure 12.10** underwent right mastectomy and received post-mastectomy radiation. She developed unusual skin toxicity from the treatment.

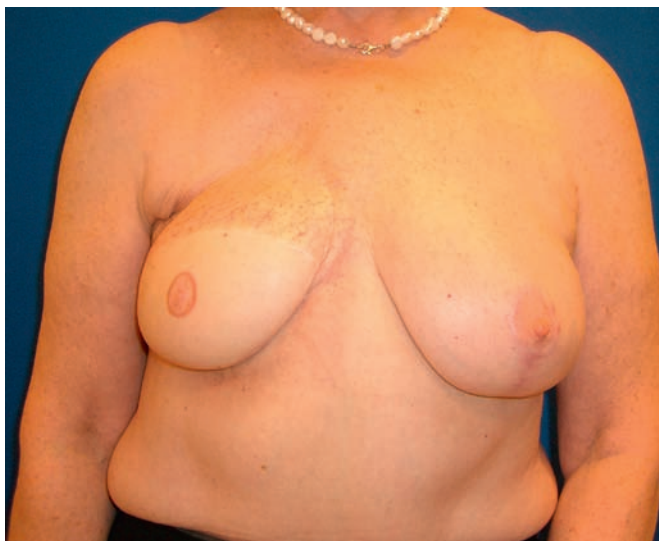

Figure 12.12 Patient shown in Figure 12.11 underwent delayed reconstruction with a free flap to the internal mammary artery and vein, fat grafting to the upper pole and contralateral breast reduction.

Managing complications

Complications of autologous reconstruction are most often related to partial or complete loss of the transported tissues. If this happens, local tissue rearrangement may correct the problem. In instances of total flap loss, a second flap (most often a free flap) will have to be recruited once the underlying cause of flap failure has been understood and resolved. In the instance of free tissue transfer, alternative donor vessels such as thoracodorsal, internal mammary, contralateral mammary vessels, or thoracoacromials may have to be dissected.

Reconstruction options for partial defects are very similar to reconstruction of full defects. Occasionally patients with a lumpectomy defect will wish to camouflage that defect with a small implant. This is possible, but it changes the shape of the breast. Often one has to place an implant in the contralateral breast as well to achieve a similar shape and size. The implants will have to be of different volumes to account for both the volume resected during lumpectomy and the volume of atrophic loss from the secondary effects of XRT.

Alternatively, a woman could select for autologous repair of a BCT defect. Because the reconstructive effort should be proportionate to the defect, a woman may not want the drawbacks of both lumpectomy + XRT and reconstruction. However, if the outcome after BCT is not cosmetically acceptable, then reconstruction of the partial defect is warranted. Local flaps would include an intercostal perforator flap, TDAP flap, lateral thoracic flap, latissimus flap, TRAM flap, or free TRAM or DIEP flap, depending on the magnitude of the defect. Rarely, a completion mastectomy may be warranted if the outcome of BCT is poor enough and a complete autologous reconstruction undertaken.

An interesting socioeconomic challenge faced by breast cancer survivors seeking repair of BCT defects is the possibility that it may not be covered by their insurance company. The Women's Health and Cancer Rights Act of 1998 (WHCRA) is a federal mandate obligating coverage of benefits for breast reconstruction after mastectomy and symmetry operations on the normal breast. It does not apply to a woman who has had BCT, although broadly third-party payers have covered plastic surgical reconstruction of BCT related defects.

Summary

Breast cancer is a common disease that is being approached in a multidisciplinary fashion via a concerted effort of medical oncologists, radiation oncologists, surgical oncologists, and plastic surgeons to yield progress in patient care.

The adjuvant use of radiation has been a game-changer in the management of breast cancer and has created the ability to offer breast conservation therapy, which is equi-efficacious to mastectomy in terms of local recurrence and overall survival. Advances in the delivery of radiation include

accelerated treatments and partial breast irradiation techniques, which are in their ascendancy.

Some of the challenges created by breast conservation approaches are how to manage the recurrence requiring mastectomy in a previously radiated field or how to solve the cosmetic limitations and complications that might arise from lumpectomy and radiation. Plastic surgery is able to rise to this challenge via implant-based reconstructions or autologous vascularized flaps to repair the defects.

Further reading

Intra M, Leonardi C, Luini A, et al. Full-dose intraoperative radiotherapy with electrons in breast surgery: broadening the indications. *Arch Surg* 2005; 140(10):936–939.

Veronesi U, Orecchia R, Luini A, et al. Full-dose intraoperative radiotherapy with electrons during breast-conserving surgery: experience

with 590 cases. *Ann Surg* 2005; 242(1):101–106.

Veronesi U, Gatti G, Luini A, et al. Full-dose intraoperative radiotherapy with electrons during breast-conserving surgery. *Arch Surg* 2003; 138(11): 1253–1256.

Clough KB, Thomas SS, Fitoussi AD, et al. Reconstruction after conservative

treatment for breast cancer: cosmetic sequelae classification revisited. *Plast Reconstr Surg* 2004; 114(7):1743–1753.

Clough KB, Cuminet J, Fitoussi A, et al. Cosmetic sequelae after conservative treatment for breast cancer: classification and results of surgical correction. *Ann Plast Surg* 1998; 41(5):471–481.

- Clough KB, Kroll SS, Audretsch W. An approach to the repair of partial mastectomy defects. *Plast Reconstr Surg* 1999; 104(2):409–420.
- Fisher B, Redmond C, Fisher ER, et al. Ten-year results of a randomized clinical trial comparing radical mastectomy and total mastectomy with or without radiation. *N Engl J Med* 1985; 312(11):674–681.
- Tran NV, Evans GR, Kroll SS, et al. Postoperative adjuvant irradiation: effects on transverse rectus abdominis muscle flap breast reconstruction. *Plast Reconstr Surg* 2000; 106(2):313–317; discussion 318–320.
- Kronowitz SJ, Hunt KK, Kuerer HM, et al. Practical guidelines for repair of partial mastectomy defects using the breast reduction technique in patients undergoing breast conservation therapy. *Plast Reconstr Surg* 2007; 120(7):1755–1768.
- Kronowitz SJ, Hunt KK, Kuerer HM, et al. Delayed-immediate breast reconstruction. *Plast Reconstr Surg* 2004; 113(6):1617–1628.
- Asgeirsson KS, Rasheed T, McCulley SJ, et al. Oncological and cosmetic outcomes of oncoplastic breast conserving surgery. *Eur J Surg Oncol* 2005; 31(8):817–823.
- Formenti SC, Rosenstein B, Skinner KA, et al. T1 stage breast cancer: adjuvant hypofractionated conformal radiation therapy to tumor bed in selected postmenopausal breast cancer patients: pilot feasibility study. *Radiology* 2002; 222(1):171–178.
- Vicini FA, Sharpe M, Kestin L, et al. Optimizing breast cancer treatment efficacy with intensity-modulated radiotherapy. *Int J Radiat Oncol Biol Phys* 2002; 54(5):1336–1344.
- Clough KB, Lewis JS, Couturaud B, et al. Oncoplastic techniques allow extensive resections for breast-conserving therapy of breast carcinomas. *Ann Surg* 2003; 237(1):26–34.
- Swanson TA, Vicini FA. Overview of accelerated partial breast irradiation. *Curr Oncol Rep* 2008; 10(1):54–60.
- Vicini F, Beitsch PD, Quiet CA, et al. Three-year analysis of treatment efficacy, cosmesis, and toxicity by the American Society of Breast Surgeons MammoSite Breast Brachytherapy Registry Trial in patients treated with accelerated partial breast irradiation (APBI). *Cancer* 2008; 112(4):758–766.
- Benitez PR, Keisch ME, Vicini F, et al. Five-year results: the initial clinical trial of MammoSite balloon brachytherapy for partial breast irradiation in early-stage breast cancer. *Am J Surg* 2007; 194(4):456–462.
- Bovi J, Qi XS, White J, et al. Comparison of three accelerated partial breast irradiation techniques: treatment effectiveness based upon biological models. *Radiother Oncol* 2007; 84(3):226–232.
- Kaufman SA, DiPetrillo TA, Price LL, et al. Long-term outcome and toxicity in a Phase I/II trial using high-dose-rate multicatheter interstitial brachytherapy for T1/T2 breast cancer. *Brachytherapy* 2007; 6(4):286–292.
- Spear SL, Onyewu C. Staged breast reconstruction with saline-filled implants in the irradiated breast: recent trends and therapeutic implications. *Plast Reconstr Surg* 2000; 105(3):930–942.