Microsurgical Reconstruction of Posttraumatic High-Energy Maxillary Defects: Establishing the Effectiveness of Early Reconstruction

Eduardo D. Rodriguez, M.D., D.D.S.
Mark Martin, M.D., D.M.D.
Rachel Bluebond-Langner, M.D.
Marwan Khalifeh, M.D.
Navin Singh, M.D.
Paul N. Manson, M.D.

Baltimore, Md.

Background: Posttraumatic, high-energy defects of the midface can be challenging to reconstruct because they involve extensive composite tissue loss and result in significant permanent functional and cosmetic deformity. These injuries require replacement of the bony framework, external soft tissue, and intraoral mucosa. Local skin flaps and nonvascularized bone grafts have been used for reconstruction, but bony resorption and the associated soft-tissue collapse limit long-term viability. The authors present a classification of maxillary defects following high-energy trauma and a treatment algorithm using vascularized bone flaps.

Methods: Fourteen patients with significant maxillary loss from high-energy trauma underwent reconstruction with composite vascularized bone flaps. Eight patients had fibula flaps and six had iliac crest flaps. There were five women and nine men, with a mean age of 36.3 years (range, 21 to 48 years) and a mean follow-up of 18 months (range, 5 to 54 months).

Results: Thirteen of the 14 flaps survived. Nine patients had additional procedures. Nine patients had oronasal fistulas and eight were dependent on gastrostomy tubes preoperatively. All patients were able to feed orally without nasal regurgitation postoperatively. All patients achieved stable restoration of the midfacial architecture.

Conclusions: The classification scheme presented centers on the missing maxillary subunits. The reconstructive algorithm is based on the type of defect, tissue requirement, and donor tissues necessary to restore facial projection and prosthodontic rehabilitation. Iliac crest and fibula bone free flaps are ideal for restoring a variety of traumatic maxillary defects. The authors advocate early reconstructive intervention using vascularized bone flaps to achieve superior functional and cosmetic outcomes. (*Plast. Reconstr. Surg.* 120 (Suppl. 2): 103S, 2007.)

The majority of high-energy maxillary defects are composite, involving the skin, skeleton, and mucosa. Successful reconstruction restores facial projection and lays the foundation for endosseous dental rehabilitation by replacing the buttresses, resurfacing the external and internal soft-tissue lining, eliminating oronasal fistulas, and restoring the alveolus. Strict adherence to these principles limits unfavorable outcomes, including gross deformity, poor facial projection, incoherent speech, and oral incompetence.

The history of maxillary reconstruction closely parallels advances made in the field of plastic surgery. Prosthetic obturation is one of the earliest

From the Division of Plastic, Reconstructive, and Maxillofacial Surgery, R Adams Cowley Shock Trauma Center/University of Maryland School of Medicine, and the Johns Hopkins University School of Medicine.
Received for publication May 5, 2006; accepted September 28, 2006.
Presented in part at the 85th Annual Meeting of the American Association of Plastic Surgeons, in Hilton Head, South Carolina, May 6 through 9, 2006.
Copyright ©2007 by the American Society of Plastic Surgeons
DOI: 10.1097/01.prs.0000260728.60178.de

Disclosure: *None of the authors has a financial interest in any of the products, devices, or drugs mentioned in this article.*

Copyright © American Society of Plastic Surgeons. Unauthorized reproduction of this article is prohibited.

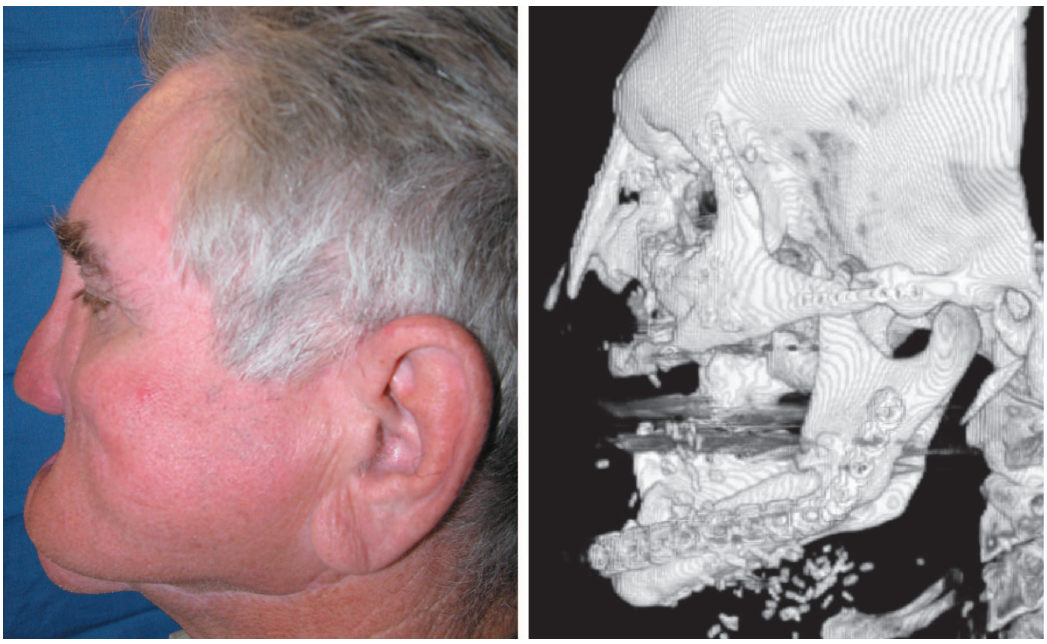

Fig. 1. Ten years before presentation, the patient's maxilla was reconstructed with a nonvascularized rib graft. The bone has resorbed, resulting in hard- and soft-tissue collapse.

reconstructive tools and is still used today.[1] Local flaps including cervical, forehead, temporalis, and distant tubed flaps combined with interposed nonvascularized autologous bone grafts (i.e., rib, cranium, and ilium)[2] allow restoration of the skeleton and soft-tissue envelope.[3–5] This technique, however, is plagued by gradual bone graft resorption and thus creates the need for additional reconstruction (Fig. 1). The introduction of free tissue transfer techniques in the 1970s—specifically, composite vascularized bone flaps—addressed this problem and provided a more enduring solution for composite maxillary defects. In addition, vascularized bone flaps provide a sound foundation for the final component of maxillary rehabilitation, the osseointegrated implant.[6] There is extensive literature on maxillary reconstruction using vascularized bone flaps following tumor extirpation; however, there are few reports on the use of composite free tissue transfer for high-energy posttraumatic maxillary defects, and there are no current classification schemes or treatment algorithms for traumatic maxillary defects.

PATIENTS AND METHODS

We reviewed 14 patients who underwent maxillary reconstruction with either a fibula or an iliac crest flap following high-energy traumatic injuries at the R Adams Cowley Shock Trauma Center from April of 2001 to October of 2005. Data including age, sex, mechanism of injury, type of defect, types of procedures, diet, speech, and outcome were collected (Table 1). Five patients were women and nine patients were men, with an average age of 36.3 years (range, 21 to 48 years). Six patients had iliac crest flaps and eight had fibula flaps. The recipient vessels were the facial artery and vein in 11 patients, the superficial temporal artery in two patients, and the superior thyroid artery and facial vein in one patient. Four patients underwent immediate reconstruction of the maxillary defect (class I) after the initial injury, and the remaining 10 patients underwent secondary reconstruction of their defects (four class I, four class II, and two class III). Two of the patients had bilateral maxillary defects (class III) and the remaining 12 patients sustained unilateral injuries (eight class I and four class II). Average follow-up was 18 months (range, 5 to 54 months).

Classification

The choice of osseous flap for maxillary reconstruction depends on tissue and pedicle length requirement and the donor tissues available. A well-designed fibula or iliac crest flap is ideal. A classification of maxillary defects has been devised that focuses on the essential maxillary functional subunits that require replacement and is purposely related to the selection of either the fibula or iliac crest free flaps for reconstruction (Figs. 2 and 3). When the maxilla is missing, the inferior orbital rim and contiguous malar prominence

Copyright © American Society of Plastic Surgeons. Unauthorized reproduction of this article is prohibited.

Table 1. Patient Summary

Patient	Sex	Age (yr)	Injury Date	Timing of Reconstruction	MOI	Location of Maxillary Defect	Type of Maxillary Defect	PEG	Fistula	Second Procedure	Dental Implants	DOS	Flap Type	Location	Recipient Vessels
1	M	33	9/19/1998	Delayed	Land mine	Left	IIb(+)	No	No			4/25/2001	Fibula	Left	Superior thyroid artery, facial vein
2	M	22	5/12/2000	Delayed	GSW	Right	IIa(–)	Yes	Yes	1. Ulnar flap 2. ALT		8/11/2003	Fibula	Right	Facial artery, facial vein
3	M	26	8/27/2003	Immediate	GSW	Right	Ia(+)	Yes	Yes	Osseous contour		8/29/2003	Iliac	Right	Facial artery, facial vein
4	F	44	9/10/2001	Delayed	GSW	Bilateral	IIIa(+)	Yes	Yes	1. Osseous contour 2. Nose	Yes	9/22/2003	Iliac	Right	Facial artery, EJ vein
5	F	41	9/1/1998	Delayed	MVC	Right	Ia(+)	Yes	Yes	Osseous contour	Yes	10/6/2003	Iliac	Right	Facial artery, facial vein
6	M	44	5/31/2004	Immediate	GSW	Right	Ia(+)	Yes	Yes			6/11/2004	Iliac	Right	Superficial temporal artery and vein
7	M	29	1997	Delayed	MVC	Right	Ia(+)	No	No	Distraction		7/26/2004	Fibula	Left	Facial artery, facial vein
8	M	21	8/17/2004	Immediate	GSW	Left	Ia(+)	No	No			8/27/2004	Fibula	Left	Facial artery, facial vein
9	M	47	6/21/2004	Delayed	MVC	Left	Ia(+)	Yes	Yes	Soft-tissue debulk		10/15/2004	Iliac	Left	Facial artery, facial vein
10	F	48	1992	Delayed	MVC	Bilateral	IIa(+)	Yes	Yes	1. Distract 2. Osseous contour	Yes	10/18/2004	Fibula	Left	Facial artery, facial vein
11	F	39	12/21/2004	Immediate	GSW	Left	Ib(+)	Yes	Yes	Soft-tissue debulk		1/3/2005	Iliac	Left	Superficial temporal artery and vein
12	M	42	1/1/1997	Delayed	Cancer/MVC	Right	IIIb(+)	No	Yes	ALT		3/7/2005	Fibula	Left	Facial artery, facial vein
13	M	38	1983	Delayed	GSW	Anterior	Ia(+)	No	No			5/23/2005	Fibula	Anterior	Facial artery, facial vein
14	F	58	1983	Delayed	GSW	Right	IIb(+)	No	No			5/31/2005	Fibula	Right	Facial artery, EJ vein

MOI, mechanism of injury; PEG, percutaneous endoscopic gastrostomy; DOS, date of surgery; GSW, gunshot wound; MVC, motor vehicle crash; ALT, anterolateral thigh; EJ, external jugular; M, male; F, female.

Copyright © American Society of Plastic Surgeons. Unauthorized reproduction of this article is prohibited.

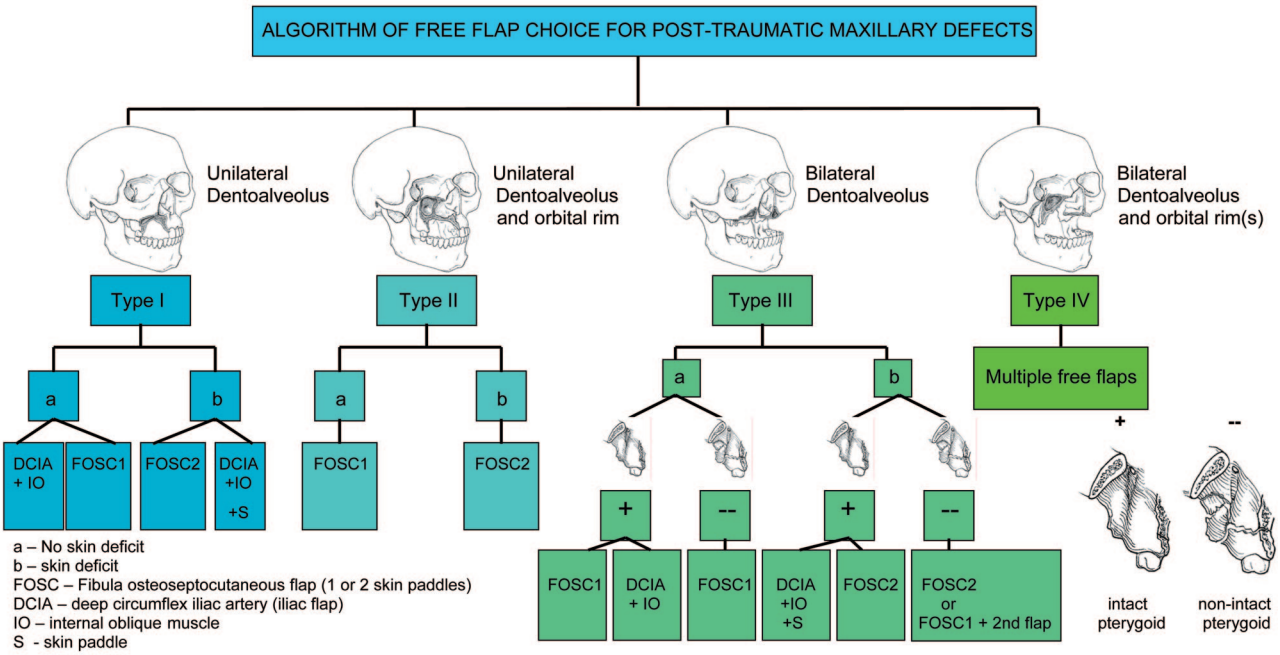

Fig. 2. Algorithm of free flap choice for posttraumatic maxillary defects.

must also be replaced for several reasons. First, autogenous bone is necessary for eventual stabilization of the orbital floor defect. Second, in cases where both the nasomaxillary and zygomaticomaxillary buttresses are damaged or absent, the newly reconstructed rim will provide a site of fixation for the neoalveolus. Third, the malar prominence defines the width and projection of the midface and is essential for optimal aesthetic outcomes.

An ascending order of reconstructive complexity is therefore outlined in which a type I defect has a unilateral dentoalveolar defect, a type II defect is missing the inferior orbital rim in addition to the ipsilateral maxilla, a type III defect involves bilateral maxillary dentoalveolar loss, and a type IV defect involves bilateral maxillary dentoalveolar loss and at least one orbital rim. The presence or absence of facial skin is denoted by the letters a and b, respectively. A modifier is included in the classification that indicates the presence (+) or absence (–) of a posterior point of fixation (pterygomaxillary buttress) that affects the choice and complexity of fixation. Mucosal lining defects are intentionally not included in the classification because they are assumed to be present in essentially all cases. The presence or absence of the globe is not included in the algorithm because we feel that optimal restoration of the periorbital area, whether provided by soft-tissue reconstruction or prosthetic replacement, requires reconstruction of normal facial dimensions and a circumferential orbital rim.

This algorithm is different from prior algorithms because it is based on functional and aesthetic structures rather than patterns of defects following tumor ablation. This algorithm advocates vascularized composite tissue with either fibula or iliac crest flaps for all reconstructions. These flaps are tailored based on the missing subunits—alveolus, orbital rim, and/or malar prominence.

Operative Technique

It is difficult to complete reconstruction in a single stage in patients with acute high-energy traumatic injuries because the effects of tissue crush, ischemia, and cavitation may not be immediately obvious.[7] These patients require early skeletal and soft-tissue stabilization followed by serial debridements of nonviable tissue before pursuing microsurgical reconstruction. When embarking on microsurgical reconstruction, either the fibula or the iliac crest flap (deep circumflex iliac artery) can be harvested, depending on the type of bony defect, pedicle length required, and donor sites available.

Extensive preoperative planning is critical to achieve intraoperative success. To determine the operative plan, facial anthropometrics are assessed, including facial thirds, facial fifths, facial and dental midlines, and upper and lower incisor

Copyright © American Society of Plastic Surgeons. Unauthorized reproduction of this article is prohibited.

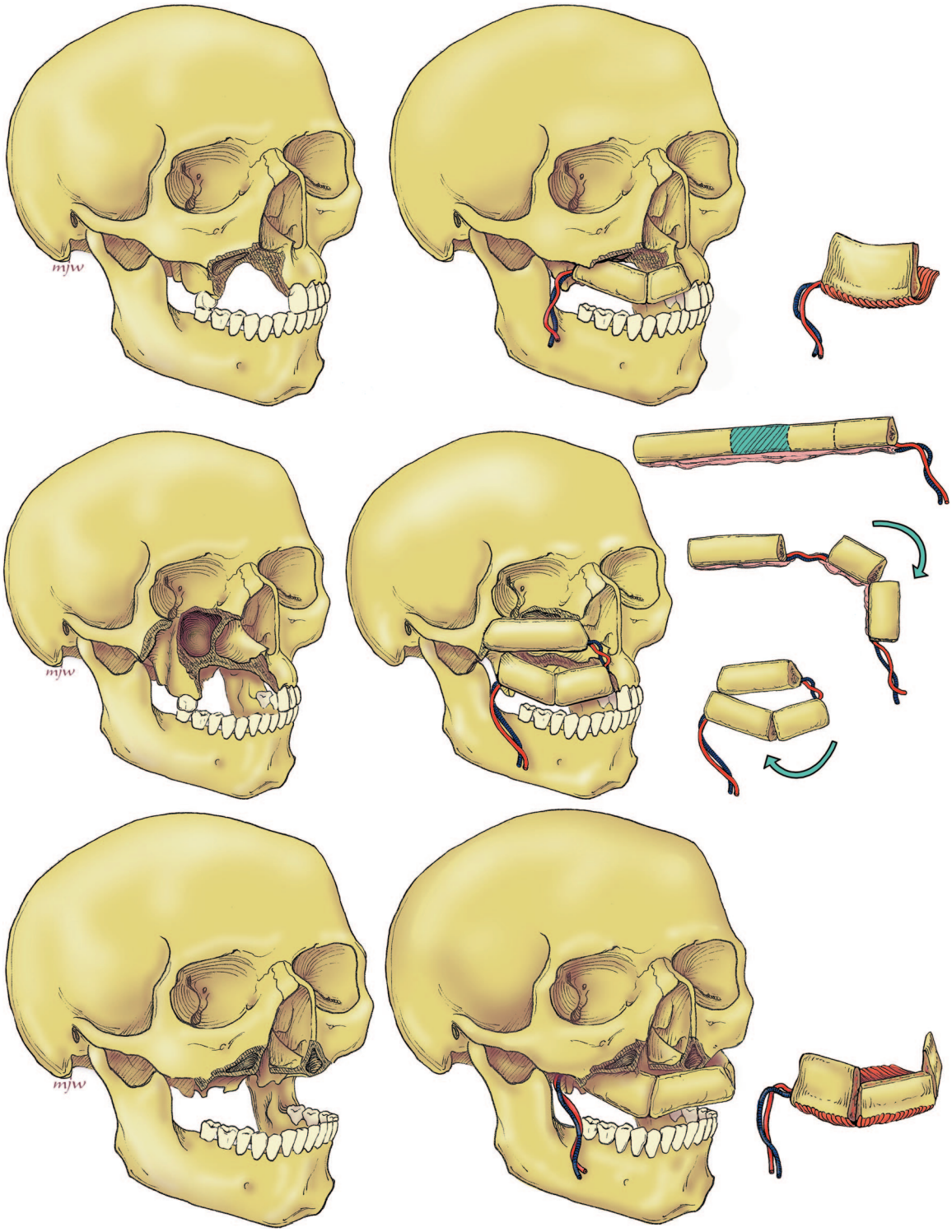

Fig. 3. Illustrations of reconstructed defects. (*Above*) Class I defect reconstruction with either a fibula or iliac crest flap. (*Center*) Class II defect reconstruction with a fibula flap. (*Below*) Class III defect reconstruction with either a fibula or iliac flap.

show at rest and while smiling. Precise analysis of dimensions can be obtained using current clinical photographs, preinjury clinical photographs, dental impressions, and three-dimensional computed tomography. If maxillofacial osteotomies are to be performed, bite registration, facebow transfer, and lateral and posteroanterior cephalograms are helpful in guiding the position of the skeletal pil-

Copyright © American Society of Plastic Surgeons. Unauthorized reproduction of this article is prohibited.

lars and occlusion. The relationship of the maxilla to the mandible in centric occlusion should be recorded and mounted on an articulator. Dental models and a three-dimensional computed tomographic scan provide information regarding dimensions of the soft- and hard-tissue defects, location of fistulas, and deficient alveolar dimensions.

Preoperative assessment of the donor vessels (i.e., superficial temporal, facial, and external carotid vessels) may be performed clinically by observation and palpation, paying close attention to lacerations, incisions, contusions, hematomas, edema, and scarring. Potential tissue donor regions must also be evaluated. Preoperative lower extremity angiography is not routinely indicated before harvesting a fibula flap.[8]

We prefer to dissect the donor vessels first, followed by exploration of the defect, and finally free flap harvest. This allows precise determination of the types and quantity of tissue and the pedicle length required. If external skin coverage is not required, the maxillary defect may be exposed by means of an intraoral approach, avoiding facial degloving incisions. Defining the defect can be demanding in the patient presenting for secondary reconstruction, given dense scar tissue, debris, and obscured tissue planes. After precisely defining the composite tissue requirements and the location of the recipient vessels, a second team may proceed with final flap design and flap harvest. It is at this time that corrective maxillofacial osteotomies and fixation may be executed simultaneously during flap harvest. A coronoidectomy is routinely performed to prevent flap interference and pedicle obstruction during mandibular excursion.

When embarking on microsurgical reconstruction, the fibula osteoseptocutaneous flap is ideal for bilateral maxillary defects, given its long pedicle length. Although the iliac crest flap has been used for bilateral defects, it is best suited for unilateral defects requiring a shorter pedicle length. The fibula flap may be harvested with a generous skin paddle for both internal and external lining. In the case of the iliac crest flap, a skin paddle is less ideal, given its moderate thickness. Instead, a portion of the internal oblique muscle is incorporated for intraoral lining. A 2.0-mm titanium miniplate template is contoured preoperatively based on dental models of remaining dentoalveolus and three-dimensional stereolithographic models of the facial skeleton. It is sterilized and used intraoperatively to design flap dimensions and facilitate flap inset (Fig. 4). This method minimizes warm ischemia time by guiding the location of osteotomies and allows for in situ semirigid stabilization. The pterygoid plates serve as the posterior stops for the neomaxilla. This method ensures a proper interarch relationship between the maxilla and mandible for eventual dental rehabilitation. Ostectomies are routinely limited to the region of the canine because it serves as the pivot point for the dentoalveolus. Watertight, layered repair of tissue planes is crucial to avoid fistula formation, flap dehiscence, and infection.

RESULTS

Thirteen of the 14 free flaps (92.8 percent) were successful. The one flap failure was the result of a hematoma that compressed the pedicle. Thirteen patients achieved stable restoration of the midfacial architecture. Globe position in all patients was not affected by the maxillary reconstruction; however, three patients who presented for delayed reconstruction had existing ectropion of their lower eyelids. Four of the patients underwent immediate reconstruction (within 13 days of the

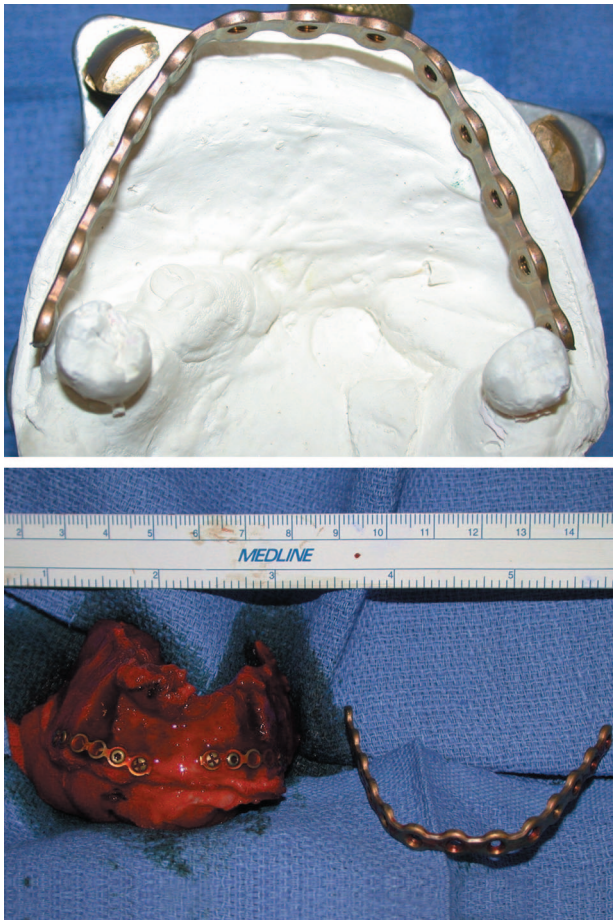

Fig. 4. A 2.0-mm template is used to facilitate a bilateral maxillary reconstruction.

Copyright © American Society of Plastic Surgeons. Unauthorized reproduction of this article is prohibited.

initial injury) and 10 patients underwent delayed reconstruction (between 4 months and 22 years after the initial injury). All patients who underwent delayed reconstruction had prior attempts at reconstruction using local, distant, or free myofascial flaps combined with nonvascularized bone grafts. Collapse of the bony architecture and disfiguring soft-tissue contracture prompted secondary reconstruction in all of these patients. Nine of the 14 patients had oronasal fistulas preoperatively that were obliterated with either the skin paddle of the free fibula or the internal oblique muscle of the deep circumflex iliac artery flap without recurrences. Preoperatively, eight patients were dependent on gastrostomy tube feeds for nutrition because of large oronasal fistulas. Postoperatively, all patients were able to feed orally without nasal regurgitation and able to

Fig. 5. The patient in case 5. (*Above*) Preoperative photograph and computed tomographic scan depicting right maxillary type Ia(+) defect. (*Below*) Postoperative photograph and three-dimensional computed tomographic scan 12 months after right maxillary reconstruction with an iliac crest free flap.

Copyright © American Society of Plastic Surgeons. Unauthorized reproduction of this article is prohibited.

maintain adequate caloric intake, allowing removal of gastrostomy tubes. Three of the patients had successful dental rehabilitation with osseointegrated implants. Nine patients had additional procedures following maxillary reconstruction: two patients underwent additional free tissue transfers for soft-tissue cheek augmentation, two underwent soft-tissue debulking, two underwent distraction and stabilization of the neomaxilla, and three underwent osseous contouring of the neomaxilla following removal of hardware.

CASE REPORTS

Type Ia(+)

The patient in case 5 is a 41-year-old woman who sustained significant craniofacial injuries from a high-velocity motor vehicle collision. She presented to us following multiple operations for repair of the right maxilla and eventual placement of endosteal dental implants. A vascularized iliac crest with internal oblique muscle flap was used to restore the maxilla and eliminate the oronasal fistula (Fig. 5).

Type Ib(+)

The patient in case 11 is a 39-year-old woman who sustained a shotgun wound to the left face and arm. After multiple washouts, there was 9 × 5-cm, full-thickness, soft-tissue defect and a 6 × 3-cm maxillary defect. The maxilla was mobile from the left lateral incisor to the pterygoid plate, with loss of maxillary wall from the alveolus to the orbital rim. She underwent immediate reconstruction (13 days after initial injury) with a free iliac osteocutaneous flap to the left maxilla and cheek. The intraoral mucosa was resurfaced with internal oblique muscle, the skin paddle was used to restore the external envelope, and vascularized iliac bone was used to restore the missing maxilla (Fig. 6).

Type IIa(–)

The patient in case 2 is a 22-year-old man who sustained injuries to the craniofacial region from a self-inflicted submental gunshot wound. The patient was acutely managed at an outside hospital and eventually referred to our center for secondary management of his deformities. He was missing his right eye, maxilla, and palate, with an associated large oronasal fistula. Despite previous efforts to correct the malocclusion with a left Le Fort I maxillary osteotomy, the remaining portion of the left maxilla was poorly aligned, with associated malocclusion. He underwent maxillary and mandibular osteotomies to correct the malocclusion, removal of orbital hardware, and reconstruction of the left maxillary defect with a free fibula osteoseptocutaneous flap (Fig. 7).

Type IIb(+)

The patient in case 12 is a 42-year-old man who initially underwent multiple reconstructive procedures for a right maxillary defect following tumor ablation at an outside hospital. He was subsequently managed at our unit following right midfacial injuries sustained from a motor vehicle collision. On presentation he had severe ectropion with an orbital floor defect and a maxillary defect extending from the central incisor to the pterygoid plate. A free fibula osteoseptocutaneous was harvested to reconstruct the orbital rim (5 cm of bone) and the maxilla (8 cm of bone). The skin paddle measuring 15 × 3 cm was used for intraoral and extraoral lining (Fig. 8).

Type IIIa(+)

The patient in case 4 is a 40-year-old woman who sustained a self-inflicted submental midline gunshot wound. She had bilateral naso-orbito-ethmoid, maxillary, and mandibular fractures. Initial reconstruction included stabilization of the skeletal injuries followed by palatal obturation. The patient had significant difficulty with deglutition and was dependent on a gastrostomy tube to maintain nutrition. She also complained of obturator discomfort and hypernasal speech. A vascularized iliac crest with internal oblique muscle flap was used to reconstruct the maxilla and eliminate the oronasal fistula. She subsequently underwent nasal reconstruction with a calvarial bone graft and a paramedian forehead flap (Fig. 9).

DISCUSSION

The goals of maxillary reconstruction include[9–11] obturation of the underlying defect and repair of oronasal fistulas, support of the horizontal and vertical facial buttresses, restoration of speech and deglutition by establishing palatal competence, and support for implant or tissue-borne dental prosthesis. Although there are six walls to the maxilla, these goals may be met by restoring the superior, anterior, and inferior walls. The superior wall is required for orbital support; the inferior wall is required for prosthodontic restoration, which will accommodate occlusal forces during mastication; and the anterior wall determines cheek projection and thus makes a significant contribution to sagittal facial dimension.

For high-energy wounds of the midface, we advocate aggressive debridement followed by early reconstruction with either plating, local flaps, or microsurgical tissue transfer. Earlier reconstruction (within 2 weeks), before scar contracture, facilitates dissection of anatomical planes, allowing more precise alignment of skeletal structures and maintenance of soft-tissue envelope volume during the acute phase of wound healing[12] (Fig. 10). In our experience, delayed reconstructions are less accurate and more time consuming. The defect must be recreated, scar tissue removed, and multiple osteotomies made to realign the distorted skeleton and reexpand the soft-tissue envelope, ultimately producing suboptimal results (Fig. 11). Case 2 clearly demonstrates the effects of soft-tissue contracture on the remaining left maxilla (Fig. 7, *left*). There is palatal rotation of the maxillary dentition because of lack of a stable contralateral skeletal buttress. The need for early reconstruction becomes more critical in more severe injuries (types II through IV) because there is greater bone loss and potentially more soft-tissue loss. Although the perceived cosmetic result may be comparable in immediate and delayed reconstruction, the operative time and complexity is

Copyright © American Society of Plastic Surgeons. Unauthorized reproduction of this article is prohibited.

Fig. 6. The patient in case 11. (*Left*) Right maxillary type Ib(+) defect from a gunshot wound. (*Right*) Immediate reconstruction with a free iliac crest musculocutaneous flap. There is no contracture of the soft-tissue envelope.

greater in delayed reconstruction, thereby increasing the potential morbidity.

The combination of pedicled flaps with interposed nonvascular bone grafts was considered the standard treatment in the management of acute high-energy midfacial injuries.[2,12] Unfortunately, the long-term durability of this method is unreliable because the bone grafts undergo partial or subtotal resorption and require future augmentation with additional bone.[12] Nonvascularized bone grafts remain an excellent option for the management of small bone defects surrounded by well-vascularized soft tissue.[9] Extensive maxillary trauma, such as injuries produced by high-energy ballistic weapons, is associated with deficient vascularized soft tissue and extensive bone loss and is thus not amenable to a nonvascularized bone graft.[2,13] Free omental, muscle, or fasciocutaneous flaps wrapped around nonvascularized bone were originally advocated because of their ability to obliterate dead space and provide vascularized coverage of nonvascularized bone.[14] In our hands, this technique has also been plagued by partial or subtotal resorption and thus we advocate composite vascularized bone flaps for such severe high-energy injuries (Fig. 12).

Microvascular free tissue transfer techniques are preferred over pedicled flaps in contemporary head and neck reconstruction.[15] The four major sources of vascularized bone routinely used for craniofacial reconstruction include the fibula, ilium, radius, and scapula. Each source of bone has its own set of inherent advantages and limitations. With respect to dental rehabilitation with osseointegrated implants, the final goal in maxillary reconstruction, the fibula and iliac crest reliably provide adequate bone width and height when compared with the scapula and radius.[16]

The fibula can be harvested as an osteoseptocutaneous flap with a large, reliable skin paddle. It has a predictably long vascular pedicle and minimal donor-site morbidity and allows a two-team approach. Up to 26 cm of long straight bone may be harvested, and multiple osteotomies can be performed without embarrassing the vascular supply, allowing the fibula to be accurately shaped to match any contour defect.[17] A portion of flexor hallucis longus or soleus muscle may be included with the flap to obliterate dead space. In addition, the fibula provides excellent bone stock to support osseointegrated implants and is the only bone flap that allows bicortical purchase during implant placement.[16] Approximation of the posterior compartment musculature appears to preserve power of great toe flexion. All these features make the fibula flap a versatile and reliable option in maxillary reconstruction.

The iliac crest free flap was popularized by Urken et al. for mandibular reconstruction[18] and subsequently used by Brown et al. for max-

Copyright © American Society of Plastic Surgeons. Unauthorized reproduction of this article is prohibited.

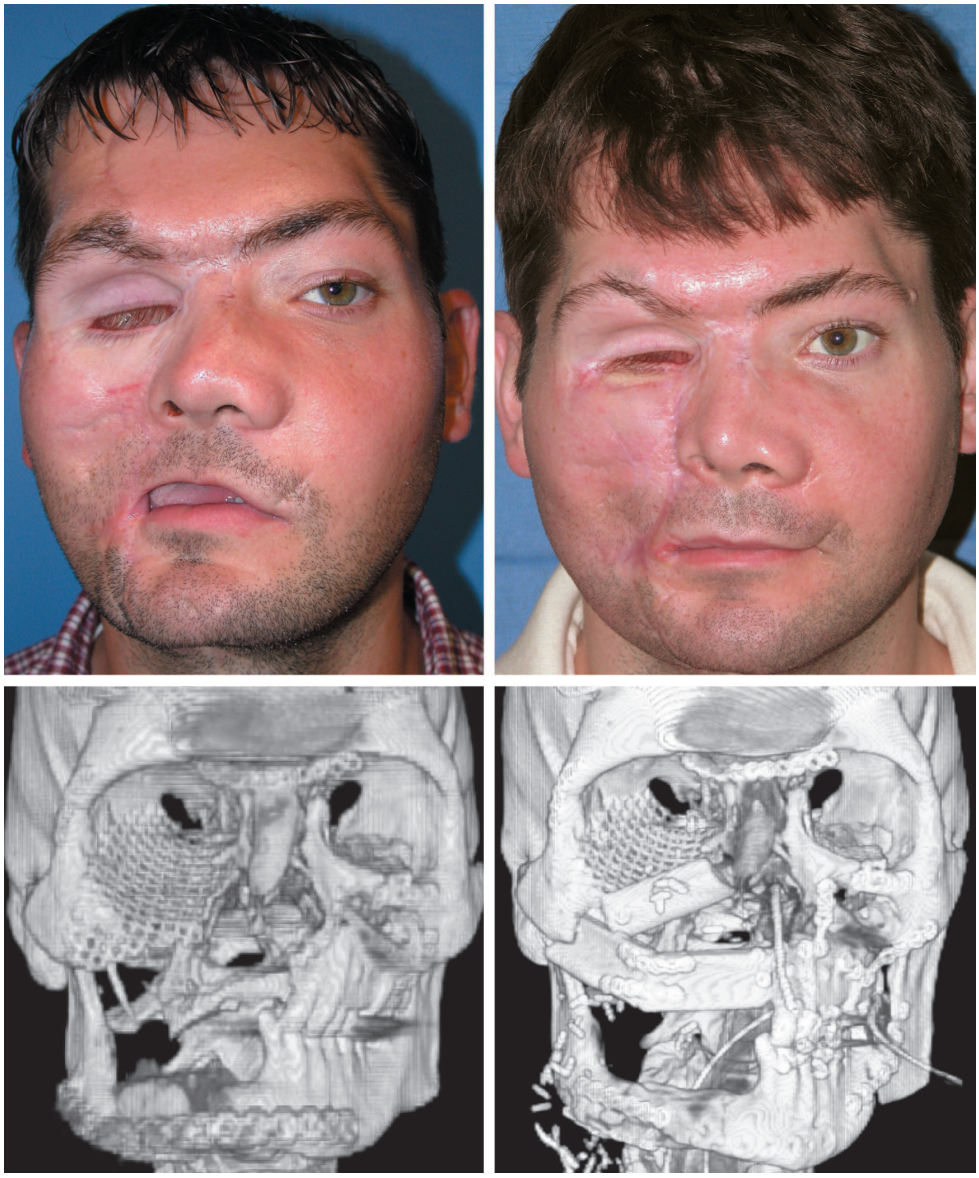

Fig. 7. The patient in case 2. (*Left*) Preoperative clinical photograph and three-dimensional computed tomographic scan of a left type IIa(–) maxillary defect. (*Right*) Clinical photograph and three-dimensional computed tomographic scan 24 months after simultaneous reconstruction with a free fibula osteoseptocutaneous flap and maxillary/mandibular osteotomies.

illary reconstruction, achieving excellent orofacial rehabilitation.[11,19] Ample height for osseointegrated implants, cheek projection, and orbital reconstruction can be obtained by harvesting this flap well into the pelvis.[16] The orientation of the iliac flap is versatile and allows it to fill both high and low defects. The internal oblique muscle is used to line the nasal and oral cavity. Over 2 to 3 weeks, the muscle contracts and epithelializes, precluding the need for later debulking as in skin paddle–based flaps.[19,20] Two potential disadvantages of the iliac crest flap involve the thick subcutaneous layer associated with Western populations and its short pedicle of 4 to 5 cm, making it problematic in cases where the facial vein and artery are inadequate.[11,19] Donor-site morbidity is comparable in both flaps.[21] When selecting a donor site, we consider first concomitant injuries that may limit available tissue, need for dental rehabilitation, pedicle length, and finally the dimensions of the bone defect.

When combined with osseointegrated implants, free flaps offer the patient a degree of oral rehabilitation previously unavailable. The ulti-

Copyright © American Society of Plastic Surgeons. Unauthorized reproduction of this article is prohibited.

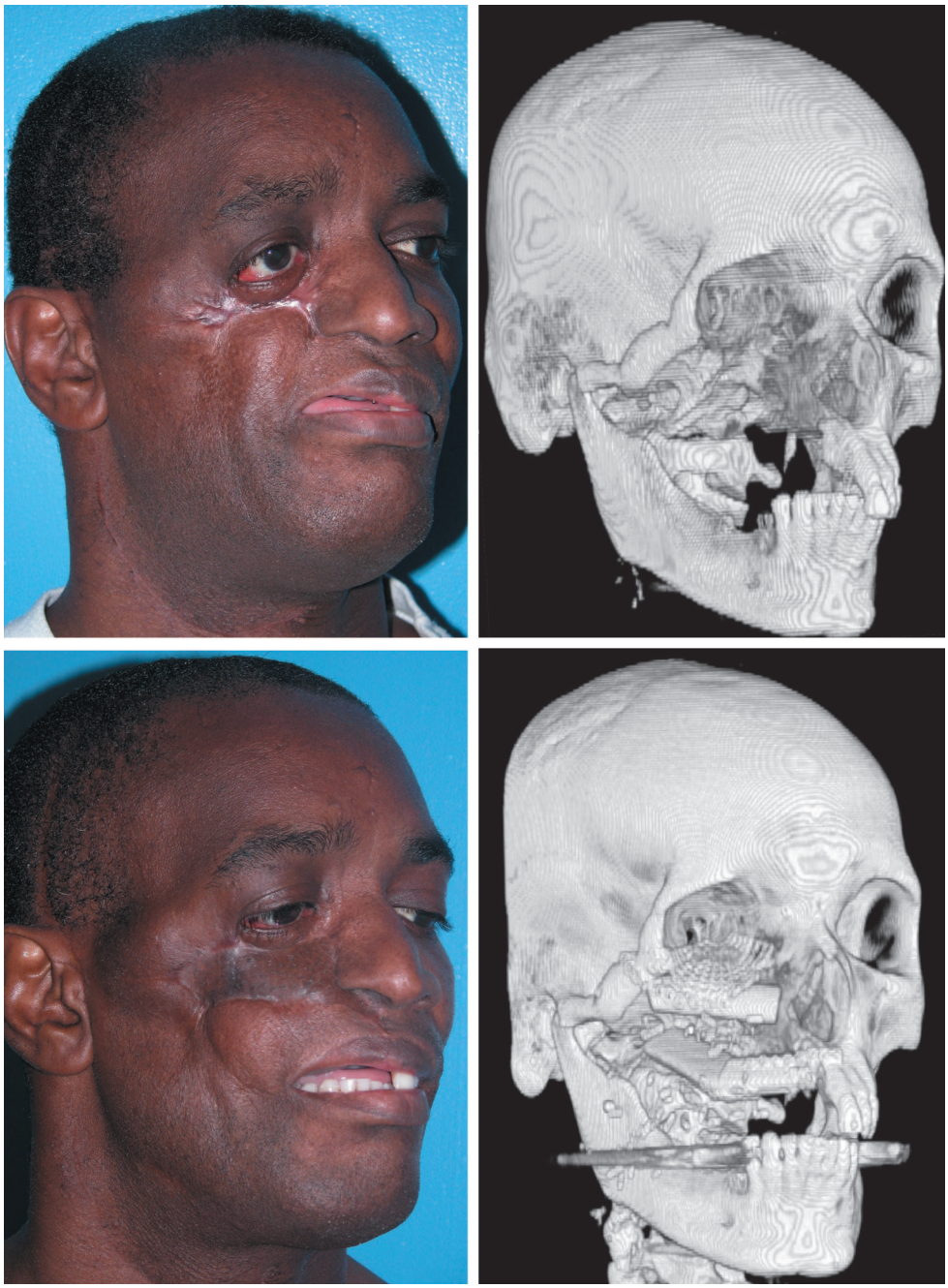

Fig. 8. The patient in case 12. (*Above*) Clinical photograph and preoperative three-dimensional computed tomographic scan demonstrating a right type IIb(+) defect. (*Below*) Clinical photograph and postoperative three-dimensional computed tomographic scan 6 months after reconstruction with a single free fibula osteoseptocutaneous flap.

mate functional goal of maxillary reconstruction is to restore speech, deglutition, and appearance. Restoration of speech requires obliteration of fistulas to avoid air escape and nasal regurgitation. Both soft-tissue flaps and obturators have been used, but each has its own disadvantage. Soft-tissue flaps do not provide a foundation that will tolerate the forces of mastication. Obturators require routine insertion and removal, which can be uncomfortable and inconvenient, particularly on raw tissue surfaces. Endosteal implants transfer the load to an implant-borne prosthesis, reducing problems of ulceration and discomfort. Preplacement of the dental implants into the flap during a first-stage operation, followed by flap transfer at 4 to 6 weeks, may shorten total rehabilitation time and

Copyright © American Society of Plastic Surgeons. Unauthorized reproduction of this article is prohibited.

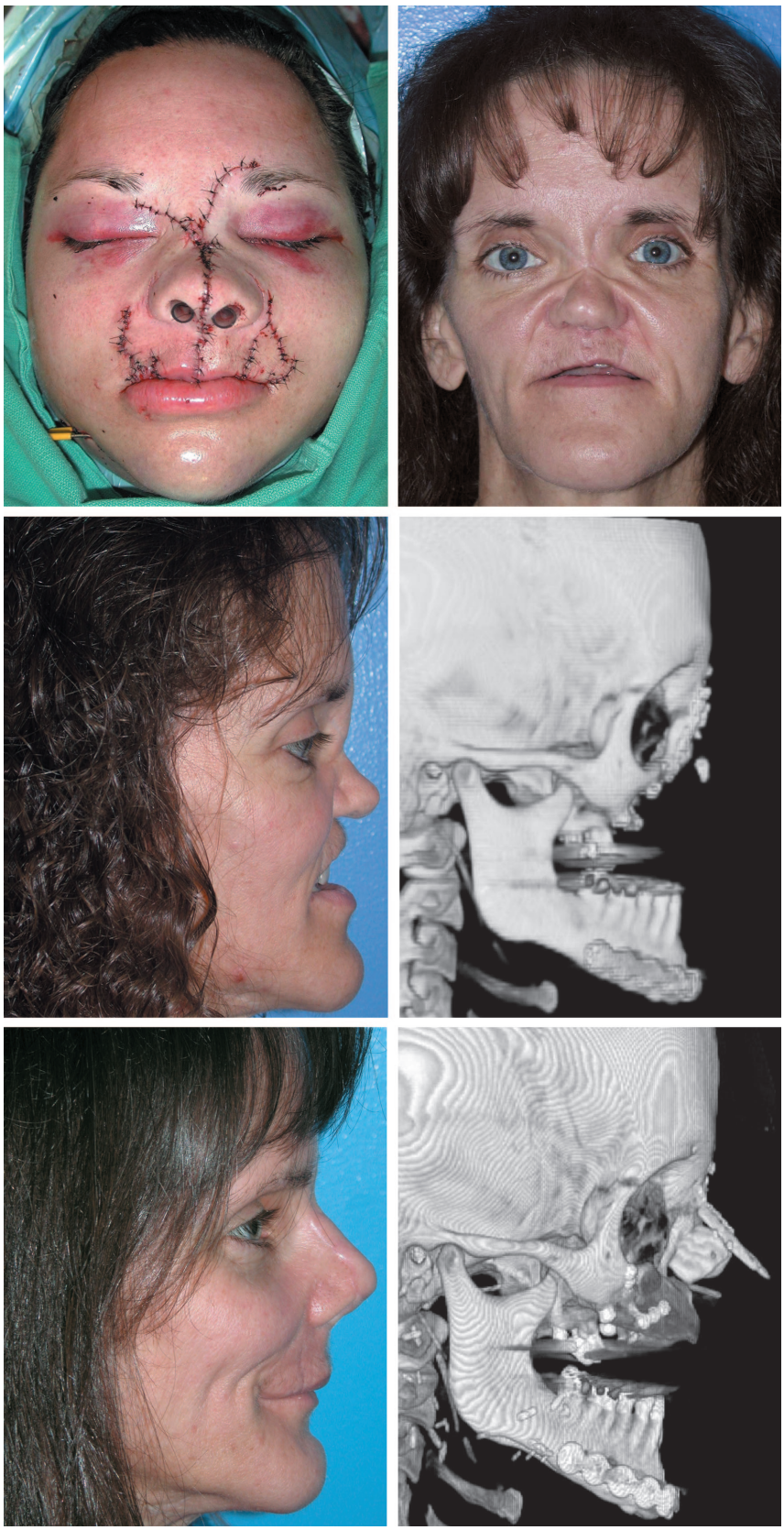

Fig. 9. The patient in case 4. (*Above*, *left*) Clinical photograph obtained immediately after reconstruction of soft tissue only. (*Above*, *right*) Three months after injury, there is

Copyright © American Society of Plastic Surgeons. Unauthorized reproduction of this article is prohibited.

Fig. 10. The patient in case 3. (*Left*) Preoperative clinical photograph and three-dimensional computed tomographic scan of a right type Ia(+) maxillary defect caused by a gunshot wound. (*Right*) Postoperative clinical photograph and three-dimensional computed tomographic scan 1 year after immediate reconstruction with a free iliac bone flap. There was no contracture of the soft-tissue envelope.

provide a dentally determined flap inset.[13] The fibula and iliac crest are superior to the scapula and radius when planning for dental implants.[16] Although there is significant debate about placement of bone flaps for oncologic head and neck defects given that many patients require radiation therapy, the trauma patient tends to be young, otherwise healthy, and with a long life expectancy. Therefore, we aim for total oral rehabilitation, which includes placement of osseointegrated implants. Although implants are often not covered by insurance initially, we have been successful in obtaining insurance coverage for patients with posttraumatic injuries, after much persistence.

The classification and algorithm presented facilitates evaluation and reconstruction of severe traumatic maxillary defects. Close attention is given to the skeletal pillars of the midface. Initial

total midface collapse because of lack of midface skeletal support. (*Center*) Preoperative clinical photograph and three-dimensional computed tomographic scan of a type IIIa(+) maxillary defect. (*Below*) Postoperative clinical photograph and three-dimensional computed tomographic scan at 1 year after free iliac crest with an internal oblique muscle flap.

Copyright © American Society of Plastic Surgeons. Unauthorized reproduction of this article is prohibited.

Fig. 11. Clinical photograph and three-dimensional computed tomographic scan depicting a left type IIa(+) maxillary defect with involution and contracture of the soft-tissue envelope resulting in vertical dystopia and loss of facial projection.

procedures focus on stabilization of the facial skeleton, correction of malocclusion, and elimination of fistulas. We prefer composite hard-tissue replacement at the initial stage of maxillary reconstruction. This allows ideal shaping of the arch for placement of endosteal dental implants.

Many patients will undergo revisions or secondary procedures. Achieving an optimal result is

Fig. 12. One-year postoperative clinical photograph of a reconstruction with nonvascularized rib graft wrapped in a free rectus flap.

Fig. 13. The patient in case 12. Postoperative clinical photograph of soft-tissue augmentation of the malar prominence with an anterolateral thigh flap.

Copyright © American Society of Plastic Surgeons. Unauthorized reproduction of this article is prohibited.

critical in trauma patients, as they are generally young, without comorbidities, and have long life expectancies. The goal of the first phase of reconstruction is to restore the skeletal construct and deliver adequate or abundant soft-tissue bulk that can be contoured or rearranged at a later date. In the second phase, the bone and soft tissue are contoured, and the position of the eyelids and the nose are addressed. We have found that type II and presumably type IV deformities often require additional soft-tissue augmentation in the periorbital and malar region as demonstrated in two of our cases (Fig. 13).

Complex maxillary reconstruction requires careful preoperative planning to ensure predictable results. Variables to consider when planning the operation include initial date of injury, mechanism of injury (high or low energy), other organ systems involved, nutritional status, and previous operative interventions,[22] all of which will affect donor-site selection. Free tissue transfer for treatment of high-energy facial trauma is reserved for severe cases with significant bone and soft-tissue loss. At our institution, this algorithm is applicable to a fraction of patients with severe facial injuries (approximately 0.1 percent). Although these cases are rare, proper initial treatment is critical. In our experience, tremendous amounts of time and effort have been spent correcting inadequate reconstructions that collapsed over time.

SUMMARY

Early aggressive operative intervention with vascularized bone flaps is recommended to avoid tissue contraction, scarring, bone malalignment, and bone resorption. A two-team approach in which one team explores the defect, dissects the recipient vessels, realigns the skeletal pillars, and corrects malocclusion with osteotomies while the second team harvests the flap is ideal. Although soft-tissue flaps obliterate dead space, they do not support the structural pillars crucial for facial projection and permanent dental rehabilitation. The authors' experience indicates that early intervention with a vascularized bone flap is ideal for permanent restoration of the maxilla and midface. The algorithm presented defines the range of traumatic defects and offers a systematic approach to complex reconstruction.

Eduardo D. Rodriguez, M.D., D.D.S.
Plastic, Reconstructive and Maxillofacial Surgery
R Adams Cowley Shock Trauma Center
22 South Greene Street
Baltimore, Md. 21201
erodriguez@umm.edu

REFERENCES

1. Genden, E. M., Okay, D., Stepp, M. T., et al. Comparison of functional and quality-of-life outcomes in patients with and without palatomaxillary reconstruction: A preliminary report. *Arch. Otolaryngol. Head Neck Surg.* 129: 775, 2003.
2. Gruss, J. S., Antonyshyn, O., and Phillips, J. H. Early definitive bone and soft-tissue reconstruction of major gunshot wounds of the face. *Plast. Reconstr. Surg.* 87: 436, 1991.
3. Edgerton, M. T., Jr., and Zovickian, A. Reconstruction of major defects of the palate. *Plast. Reconstr. Surg.* 17: 105, 1956.
4. Miller, T. A. The Tagliacozzi flap as a method of nasal and palatal reconstruction. *Plast. Reconstr. Surg.* 76: 870, 1985.
5. Campbell, H. Reconstruction of the left maxilla. *Plast. Reconstr. Surg.* 3: 66, 1948.
6. Branemark, P. I. Osseointegration and its experimental background. *J. Prosthet. Dent.* 50: 399, 1983.
7. Bartlett, C. S. Clinical update: Gunshot wound ballistics. *Clin. Orthop.* 408: 28, 2003.
8. Lutz, B. S., Wei, F. C., Ng, S. H., et al. Routine donor leg angiography before vascularized free fibula transplantation is not necessary: A prospective study in 120 clinical cases. *Plast. Reconstr. Surg.* 103: 121, 1999.
9. Muzaffar, A. R., Adams, W. P., Jr., Hartog, J. M., et al. Maxillary reconstruction: Functional and aesthetic considerations. *Plast. Reconstr. Surg.* 104: 2172, 1999.
10. Davison, S. P., Sherris, D. A., and Meland, N. B. An algorithm for maxillectomy defect reconstruction. *Laryngoscope* 108: 215, 1998.
11. Brown, J. S. Deep circumflex iliac artery free flap with internal oblique muscle as a new method of immediate reconstruction of maxillectomy defect. *Head Neck* 18: 412, 1996.
12. Robertson, B. C., and Manson, P. N. High-energy ballistic and avulsive injuries: A management protocol for the next millennium. *Surg. Clin. North Am* 79: 1489, 1999.
13. Rohner, D., Jaquiery, C., Kunz, C., et al. Maxillofacial reconstruction with prefabricated osseous free flaps: A 3-year experience with 24 patients. *Plast. Reconstr. Surg.* 112: 748, 2003.
14. Suominen, E., and Tukiainen, E. Close-range shotgun and rifle injuries to the face. *Clin. Plast. Surg.* 28: 323, 2001.
15. Genden, E. M., Higgins, K., and Urken, M. L. The role of pedicled flaps in a microvascular world. *Semin. Plast. Surg.* 17: 275, 2003.
16. Frodel, J. L., Jr., Funk, G. F., Capper, D. T., et al. Osseointegrated implants: A comparative study of bone thickness in four vascularized bone flaps. *Plast. Reconstr. Surg.* 92: 449, 1993.
17. Yim, K. K., and Wei, F. C. Fibula osteoseptocutaneous free flap in maxillary reconstruction. *Microsurgery* 15: 353, 1994.
18. Urken, M. L., Buchbinder, D., Costantino, P. D., et al. Oromandibular reconstruction using microvascular composite flaps: Report of 210 cases. *Arch. Otolaryngol. Head Neck Surg.* 124: 46, 1998.
19. Brown, J. S., Jones, D. C., Summerwill, A., et al. Vascularized iliac crest with internal oblique muscle for immediate reconstruction after maxillectomy. *Br. J. Oral Maxillofac. Surg.* 40: 183, 2002.
20. Kakibuchi, M., Fujikawa, M., Hosokawa, K., et al. Functional reconstruction of maxilla with free latissimus dorsi-scapular osteomusculocutaneous flap. *Plast. Reconstr. Surg.* 109: 1238, 2002.
21. Rogers, S. N., Lakshmiah, S. R., Narayan, B., et al. A comparison of the long-term morbidity following deep circumflex iliac and fibula free flaps for reconstruction following head and neck cancer. *Plast. Reconstr. Surg.* 112: 1517, 2003.
22. Dolin, J., Scalea, T., Mannor, L., et al. The management of gunshot wounds to the face. *J. Trauma* 33: 508, 1992.

Copyright © American Society of Plastic Surgeons. Unauthorized reproduction of this article is prohibited.