

Case Report

Infection After Augmentation Gluteoplasty in a Pregnant Patient

Michael Alperovich; Jeffrey E. Schreiber, MD; and Navin K. Singh, MD

The authors are from the Johns Hopkins School of Medicine, Baltimore, MD. Mr. Alperovich is a medical student; Dr. Schreiber is a Clinical Instructor; and Dr. Singh is a Clinical Assistant Professor in the Division of Plastic Surgery, Department of Surgery.

The authors present a case of late postoperative infection after augmentation gluteoplasty in a 32-year-old pregnant woman. The case is unique in that it is the first documented example of a gluteal implant infection in a pregnant woman and because the infection was not preceded by trauma to the anatomic region. (Aesthetic Surg J 2007;27:622–625.)

Augmentation gluteoplasty was initially performed primarily in Central and South America but has recently gained popularity in the United States. An estimated 2556 gluteal augmentations were performed in 2006, according to the American Society for Aesthetic Plastic Surgery.¹ Published accounts of the procedure have focused on surgical techniques and variations in implant placement,^{2–9} with relatively few reports of long-term outcomes or complications.^{10–15} Both the growing popularity of augmentation gluteoplasty and the relatively little data currently available on the subject warrant attention to possible risks associated with the procedure. In this article, we report a case of late postoperative infection after augmentation gluteoplasty in a pregnant woman.

Case Report

The patient is a 32-year-old Hispanic woman at 16 weeks of an intrauterine pregnancy who presented with a 4-day history of increasing lower back pain, fever, and chills 27 months after undergoing augmentation gluteoplasty with bilateral solid silicone implants (serial nos. 44317 and 44316; Spectrum Designs, Carpinteria, CA).

On examination, the patient had a buttock abscess measuring greater than 20 cm and had a fever and leukocytosis of 12,830 mL. She underwent magnetic resonance imaging to reveal a large fluid collection surrounding the implants that was consistent with an abscess (Figure 1). The patient was subsequently taken to the operating room for incision and drainage of the abscess and removal of the implants.

With the patient under spinal anesthesia, a 15-cm vertical incision was made over her old scar followed by electrocautery through the deep subfascial plane to evacuate 1.9 L of purulent liquid. Gram stain, culture, and sensitivity testing revealed *Pseudomonas aeruginosa*. The incision was closed over drains and, after surgery, the patient defervesced; her white blood cell count returned to a normal level of 8750 mL. On postoperative day 3, the patient was discharged with her drains and placed on a 7-day course of amoxicillin/clavulanate (Augmentin; GlaxoSmithKline, Research Triangle Park, NC).

Discussion

Augmentation gluteoplasty was first performed in 1969 with a Cronin prosthesis.¹⁶ The procedure initially involved introducing implants into the subcutaneous tissue, which frequently resulted in capsular contracture, dislodgements, and asymmetry.¹⁷ After Robles et al³ introduced the technique of inserting implants anterior to the gluteus maximus in 1984, the surgical results improved, and the popularity of the procedure increased.

Reports of complications after augmentation gluteoplasty are rare, but infection remains a risk. One 3-year series estimated infection risk to be 5%, which included superficial cellulitis, as well as deeper implant infection.¹² In comparison, breast implants have a 2% to 2.5% infection rate.¹⁷ The proximity of the incision site to the anal region is believed to place the gluteal implants at greater risk for infection in the immediate postoperative period.

Nevertheless, late postoperative gluteal infection after augmentation gluteoplasty is extremely rare, with only a

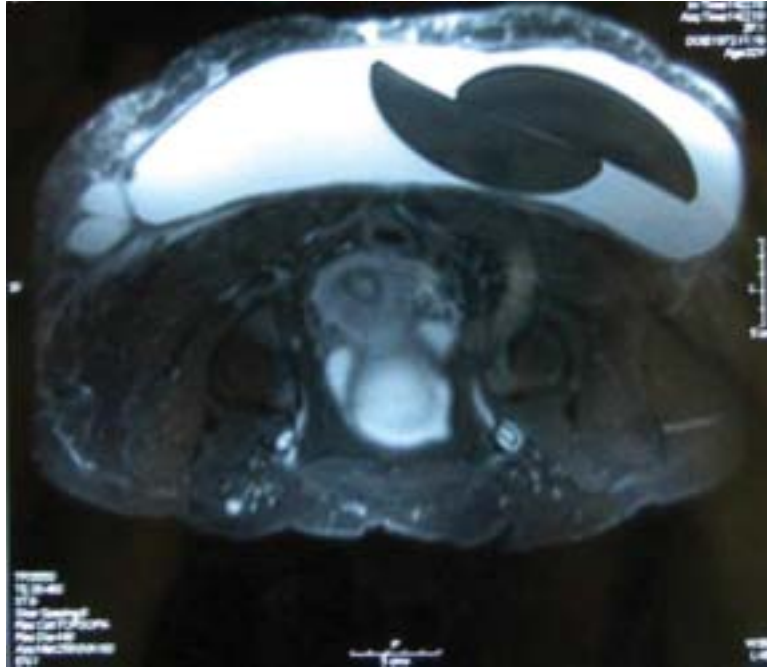


Figure 1. Preoperative MRI of gluteal region abscess with floating gluteal implants.

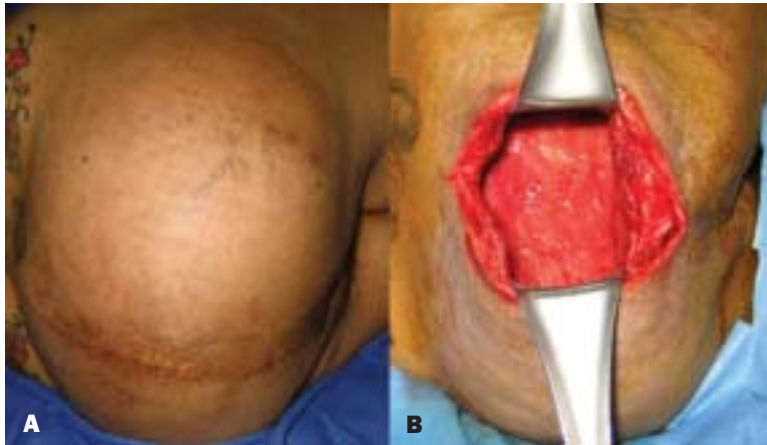


Figure 2. A, Preoperative buttock region of a 32-year-old pregnant woman with gluteal implant infection and abscess. **B,** Exposed implant pocket after abscess drainage.

few published accounts in the literature. Interestingly, all published accounts of infection beyond the immediate postoperative period have reported trauma.^{10,11} To our knowledge, this is the first reported case of infection this late in the postoperative period that occurred in the absence of trauma.

Our case also remains the only documented example of a gluteal implant infection in a pregnant patient. Pregnancy is believed to weaken the immune system and may have contributed to the patient's infection suscepti-

bility. Pregnant women have a decreased lymphocyte proliferative response, decreased natural killer cell activity, and decreased numbers of helper T cells.¹⁸ Fetal lymphocytes also inhibit the maternal immune response by suppressing T-cell proliferation.¹⁹

No risk factors for *Pseudomonas* infection, such as HIV status, intravenous drug use, or urinary tract infection, were present at the time of the augmentation. No urinalysis or blood cultures were obtained at that time. The infection may have occurred through several routes.

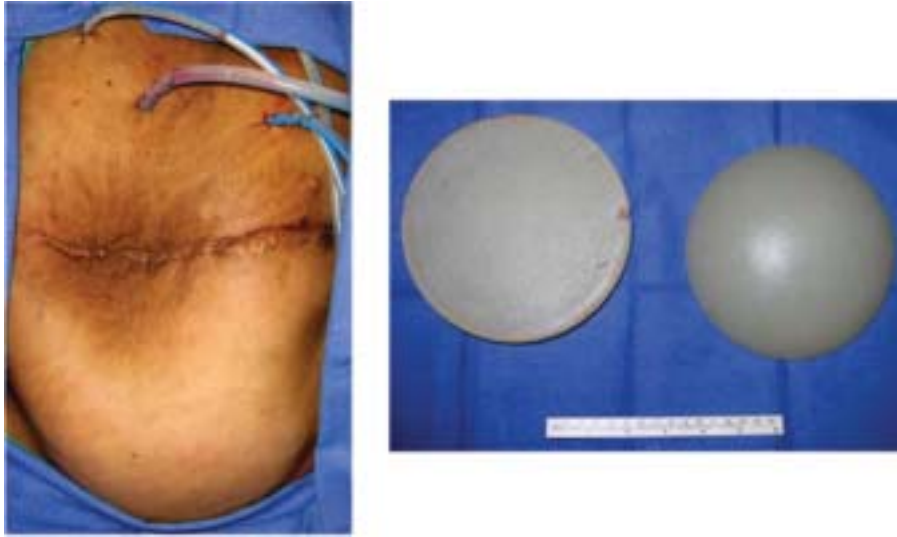


Figure 3. A, Immediate postoperative closed incision and 4 19F Blake drains. **B,** Removed gluteal implants. Minimal erosion on left implant from operative handling.

First, the patient's buttock implants were placed in March 2004, and several weeks after surgery, a seroma developed around the right implant that was aspirated locally. Second, the patient experienced partial dehiscence of her incision about 1 month after surgery that required secondary closure. Third, 2 months later the seroma reaccumulated, requiring further aspiration. Fourth, the patient had an ectopic pregnancy that resulted in a left salpingectomy approximately 1 year after the implants were inserted. Finally, she became pregnant soon thereafter and had a vaginal delivery 4 months before the onset of the periprosthetic infection.

We also considered the possibility of weight-bearing stress to the implants from additional weight gain in pregnancy. However, we believe this likely had minimal contribution because women only gain an average of between 2.8 and 4.4 lbs 16 weeks into pregnancy.²⁰

In deciding on a treatment for the patient's abscess, we considered other options, including packing the cavity, only placing invasive drains, and keeping the implants in place. We chose a conservative management course because the patient was pregnant and had notable systemic symptoms and an impressive abscess size. The patient has been regularly followed up in our plastic surgery clinic and has had uncomplicated healing 6 weeks after surgery.

Conclusion

We have described one of the few reported cases of infection after augmentation gluteoplasty. To our knowl-

edge, this is the first case of its kind that occurred in the absence of any trauma history, which may be partially explained by the patient's second-trimester pregnancy. It is important to consider late postoperative infection in augmentation gluteoplasty as this procedure continues to be performed with greater frequency. ■

The authors have no financial interest in and receive no compensation from manufacturers of products mentioned in this article.

References

- 2006 Cosmetic Surgery National Data Bank Statistics. New York: ASAPS; 2007.
- Gonzalez R. Augmentation Gluteoplasty: The XYZ Method. *Aesthetic Plast Surg* 2004;28:417-425.
- Robles JM, Tagliapietra JC, Grandi M. Gluteoplastia de aumento: Implante submuscular. *Cir Plast Iberolat* 1984;10:365-369.
- Raposo-Amaral CE, Cetrulo CL, Guidi MdC, Ferreira DM, Raposo-Amaral CM. Bilateral lumbar hip dermal fat rotation flaps: a novel technique for autologous augmentation gluteoplasty. *Plast Reconstr Surg* 2006;117:1781-1788.
- Vergara R, Marcos M. Intramuscular gluteal implants. *Aesthetic Plastic Surgery* 1996;20:259-262.
- Peren PA, Gomez JB, Guerrerosantos J, Salazar CA. Gluteus augmentation with fat grafting. *Aesthetic Plastic Surgery* 2000;24:412-417.
- Mendieta CG. Gluteoplasty. *Aesthetic Surg J* 2003;23:441-455.
- De la Pena J. Subfascial technique for gluteal augmentation. *Aesthetic Surg J* 2004;24:265-273.
- Vergara R, Amezcua H. Intramuscular gluteal implants: 15 years' experience. *Aesthetic Surg J* 2003;23:86-91.
- Buchuk L. Complication with gluteal prosthesis. *Plast Reconstr Surg* 1986;77:1012.

11. Ford RD, Simpson WD. Massive extravasation of traumatically ruptured buttock silicone implants. *Ann Plast Surg* 1992;29:86–88.
12. Senderoff DM. Buttock augmentation using solid silicone implants (a three year study). Presentation at the annual meeting of the American Society for Aesthetic Plastic Surgery and the Aesthetic Surgery Education and Research Foundation, May 3, 2005.
13. Cocke WM, Ricketson G. Gluteal augmentation. *Plast Reconstr Surg* 1973;52:93.
14. Douglas WM, Bartels RJ, Baker JL. An experience in aesthetic buttocks augmentation. *Clin Plast Surg* 1975, 3:471–476.
15. Gonzalez-Ulloa M. Gluteoplasty: a ten-year report. *Aesthetic Plast Surg* 1991;15:85–91.
16. Bartels RJ, O'Malley JE, Douglas WM, Wilson RG. An unusual use of the Cronin breast prosthesis. Case report. *Plast Reconstr Surg* 1969;44:500.
17. Pittet B, Montandon D, Pittet D. Infection in breast implants. *Lancet Infect Dis* 2005;5:94–106.
18. Rigby FB, Pastorek JG II. Pneumonia during pregnancy. *Clin Obstet Gynecol* 1996;39:107–119.
19. Lederman MM. Cell mediated immunity and pregnancy. *Chest* 1984;86:6s–9s.
20. Institute of Medicine. Committee on Nutritional Status During Pregnancy and Lactation. Nutrition During Pregnancy: Part I, Weight Gain: Part II, Nutrient Supplements. Washington, DC: National Academy Press, 1990.

Accepted for publication June 12, 2007.

Reprint requests: Navin K. Singh, MD, Ivy Plastic Surgery Associates, 5454 Wisconsin Avenue, Suite 1710, Chevy Chase, MD 20815. E-mail: nsingh@jhmi.edu.

Copyright © 2007 by The American Society for Aesthetic Plastic Surgery, Inc.

1090-820X/\$32.00

doi:10.1016.j.asj.2007.08.005