

# USE OF THE U-CLIP FOR MICROVASCULAR ANASTOMOSIS

JESSE TAYLOR, M.D., RYAN KATZ, M.D.,\* and NAVIN SINGH, M.D., M.S.

Microvascular anastomosis is a demanding skill requiring technical excellence and a thorough knowledge of anatomy and physiology. Every suture placed in a microvascular anastomosis should be considered critical as each has the potential to compromise the delicate reconstruction. As such, any device that can facilitate microvascular suture placement deserves thorough evaluation. The U-clip (Coalescent Surgical, Sunnyvale, CA) is such a device in that it eliminates the often time consuming process of tying knots. We evaluated use of the U-clip in microvascular anastomosis of a 1.5 mm artery. We found the U-clip to offer some advantages including ease of use, traditional feel of directed suture placement (as compared to couplers), and elimination of time needed for knot tying. Its shortcomings include size (in diameter, the "pop-off" section of the device appears larger than standard 8-0 suture), the significant force required to "pop-off" the device and difficulty removing the device. ©2006 Wiley-Liss, Inc. *Microsurgery* 26:550–551, 2006.

This case report presents the U-clip as an alternative method for reconstructive microvascular anastomosis. Though its benefits are well described for coronary artery anastomosis,<sup>1–3</sup> this is the first report of its use in reconstructive microvascular surgery. The majority of microvascular failures are thought to be due to technical errors. The morbidity associated with a failing microvascular procedure often includes a return to the operating room, the potential loss of the reconstruction, increased psychological stress, a prolonged hospital stay, and elevated health care costs.<sup>4</sup> The U-Clip (Coalescent Surgical, Sunnyvale, CA) facilitates vascular anastomosis by eliminating the need for tying knots and allowing predictable and reproducible coaptation of the vessel wall.<sup>5</sup> This technology has already been used to perform successful coronary artery bypass grafts and arterio-venous fistulae.<sup>6–8</sup> We report using the U-Clip for anastomosis of a traumatically lacerated radial artery.

## CASE REPORT

A healthy, right hand dominant, 23y/o male sustained a laceration to the dorso-radial aspect of his right hand after punching through a glass window. He noted pulsatile blood from his right wrist and sought emergent medical treatment. In the emergency room the exsanguination was controlled with manual pressure and a blood pressure cuff, and the patient was taken to the operating room for immediate exploration. On examination, the patient had a linear laceration to the dorso-radial aspect of the right hand at the level of the wrist severing all tendons in the first three extensor compartments, the radial artery, and the radial sensory nerve. After standard tendon repair, the microscope was then positioned to facilitate primary

repair of his 1.5 mm diameter radial artery with an end-to-end anastomosis using S15 U-Clips (Fig. 1). After the arterial repair, pulsatile arterial flow was confirmed distal to the anastomosis with a Doppler probe. The radial sensory nerve was coated with an 8-0 nylon suture, the wound was closed in a layered fashion, and the patient was placed in a volar based splint in slight extension. Post-operative physical examination with Allen test and Doppler confirmed prograde flow in all digital arteries via the radial artery.

## DISCUSSION

This case report presents the U-clip (Fig. 2) as an alternative method for reconstructive microvascular anastomosis. Though its benefits are well described for coronary artery anastomosis,<sup>1–3</sup> this is the first report of its use in reconstructive microvascular surgery.

The nitinol U-clip device (Coalescent Surgical, Sunnyvale, CA) has been designed to facilitate an interrupted anastomosis by reducing the complexity and difficulty of the anastomotic process. The device consists of a nitinol wire attached to a pop-off suture and needle. The nitinol wire has memory and forms a closed coil when detached from the suture. Once placed, this coil approximates and holds tissue together in a predictable, reliable, and atraumatic fashion. Thus, the nitinol U-clip device eliminates knot tying and extensive suture manipulation. In the cardiac surgery literature, its overall performance has been similar to interrupted suture anastomosis, with similar anastomotic patency rates, similar flow characteristics by angiography, and similar intimal histopathology.<sup>5</sup>

The experience with this anastomotic device offers several advantages, but does have shortcomings. Overall, we are impressed by the device's ease of use, predictability, and atraumatic handling of the tissues. The U-clip, when compared to anastomotic "coupling" devices, offers the surgeon the option of direct suture placement and better alignment of size-mismatch. However, there are several characteristics that may be improved prior to

The Johns Hopkins Hospital, McElderry 8152-C, Caroline, Baltimore, MD  
\*Correspondence to: Ryan Katz, The Johns Hopkins Hospital, McElderry 8152-C, 601 N. Caroline, Baltimore, MD. E-mail: ryankatz1@gmail.com  
Received 6 July 2006; Accepted 15 August 2006  
Published online 2 November 2006 in Wiley InterScience (www.interscience.wiley.com). DOI 10.1002/micr.20286

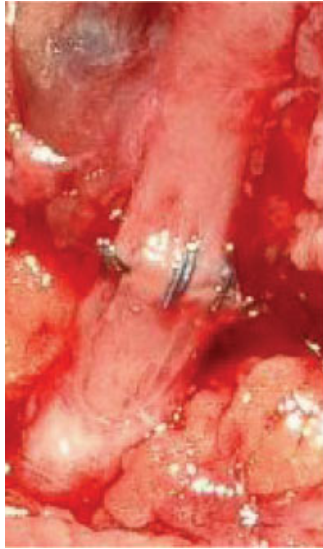

Figure 1. U-clip anastomosis of radial artery. [Color figure can be viewed in the online issue, which is available at [www.interscience.wiley.com](http://www.interscience.wiley.com).]

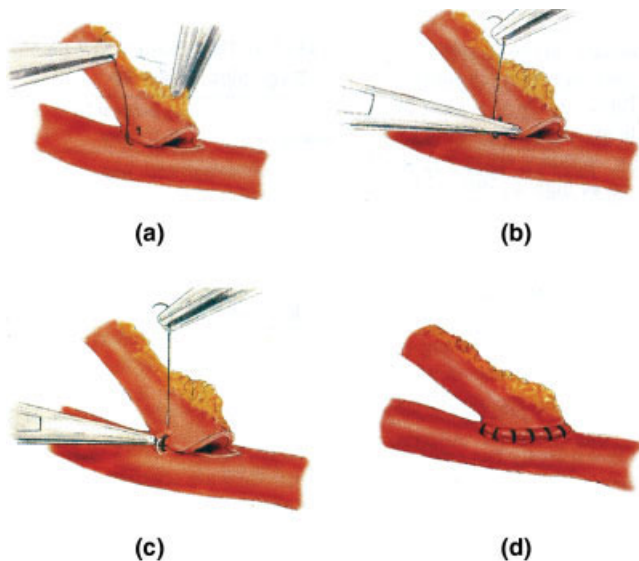


Figure 2. (a) Placement of U-clip device; (b) Pressure applied to release; (c) U-clip closure and removal of needle and flexible member; (d) Finished anastomosis (From Wolf et al, *J Thorac Cardiovasc Surg*, 2003, 169, 168–177. © American Association of Thoracic Surgery, reproduced by permission.) [Color figure can be viewed in the online issue, which is available at [www.interscience.wiley.com](http://www.interscience.wiley.com).]

widespread use of the device for reconstructive microsurgery. We have used Coalescent Surgical's smallest U-clip (the S15 which approximates an 8-0 nylon suture) and found its size to be larger than expected. The diameter of the nitinol wire was clearly larger than that of an 8-0 suture, as was the diameter of the suture's pop-off sec-

tion. In small vessels (1–2 mm), this could damage the tissue, lead to flow leaks (if a clip needs to be removed), or cause potentially turbulent flow depending on the endoluminal hardware profile.

We also found that the pop-off release mechanism, though easy to use, required a significant amount of force to detach the nitinol wire from the suture. Since excessive forces can result in vascular trauma, a proportionally lower amount of force might increase the microsurgeon's comfort zone with using the device. Once the nitinol wire is placed, it is difficult to remove. Removal requires cutting the device (which could prove quite difficult given the proximity of the device to the vessel wall) or removal using a specialized clamp designed by Coalescent Surgical. Lastly, many microsurgeons prefer that a tail of suture be left after a knot has been tied to facilitate manipulation of the vessel. The U-clip lacks such a "tail," which, if incorporated into the device, may increase its applicability.

## CONCLUSIONS

The U-Clip has the potential to facilitate microvascular anastomoses. At this point, caution should be exercised prior to its use in small, fragile vessels. Further development of the device may ultimately prove it to be a useful adjunct to the field of microvascular plastic and reconstructive surgery.

## REFERENCES

1. Wolf RK, Alderman EL, Caskey MP, Raczkowski AR, Dullum MK, Lundell DC, Hill AC, Wang N, Daniel MA. Clinical and six-month angiographic evaluation of coronary arterial graft interrupted anastomoses by use of a self-closing clip device: A multicenter prospective clinical trial. *J Thorac Cardiovasc Surg* 2003;169:168–178.
2. Berdat PA, Kipfer B, Immer FF, Pfammatter JP, Carrel T. Facilitated vascular interrupted anastomosis in cardioascular surgery with a new clip device. *J Thorac Cardiovasc Surg* 2002;124:1256–1258.
3. Shermin RJ, Shapira OM, Pawar RV, Bao U, Sayeed-Shah U, Lazar HL. U-clip anastomoses in coronary artery bypass grafting: Initial clinical experience. *Heart Surg Forum* 2003;6:362–365.
4. Heinz TR, Cowper PA, Levin LS. Microsurgery costs and outcome. *Plast Reconstr Surg* 1999;104:89–96.
5. Hill AC, Maroney TP, Virmani R. Facilitated coronary anastomosis using a nitinol U-Clip device: Bovine model. *J Thorac Cardiovasc Surg* 2001;121:859–870.
6. DeMaria RG, Fortier S, Malo O, Carrier M, Perrault LP. Interrupted coalescent nitinol clip versus continuous suture coronary anastomosis: A comparative endothelial function study. *Heart Surg Forum* 2003;6: 72–76.
7. Lin PH, Bush RL, Nelson JC, Lam R, Paladugu R, Chen C, Quinn G, Lumsden AB. A prospective evaluation of interrupted nitinol surgical clips in arteriovenous fistula for hemodialysis. *Am J Surg* 2003;186: 625–630.
8. Tirabassi MV, Banever GT, Moriarty KP, Konefal S, Reiter E, Wait R. Feasibility of thoracoscopic U-clip esophageal anastomosis: An alternative for esophageal atresia reconstruction. *J Pediatr Surg* 2004; 39:851–854.