

# Use of an Innervated Tongue Flap to Rehabilitate the Tongue after Hypoglossal-to-Facial Nerve Transfer

Navin Singh, M.D., Bradley Robertson, M.D., D.D.S., and Lee Dellon, M.D.

Baltimore, Md.

Facial palsy resulting from loss of the intracranial portion of the facial nerve has been reconstructed traditionally by transferring motor axons from the hypoglossal nerve to the facial nerve.<sup>1-4</sup> This approach can reinnervate the facial muscles if it is done before these muscles have undergone irreversible atrophy, eliminating the need for a free-muscle transfer. The two major disadvantages of the hypoglossal-to-facial nerve transfer as an ideal strategy are (1) synkinetic movements of the reinnervated side of the face without volitional control<sup>5</sup> and (2) untoward sequelae of hemiglossal denervation. Cross-facial nerve grafting can provide the volitional control of facial animation<sup>6,7</sup> and is now the preferred approach.<sup>1,8</sup> Transferring half of the hypoglossal nerve is recommended to “babysit” the paralyzed side of the face until the cross-facial nerve graft regenerates.<sup>9</sup> There remains a need, however, to rehabilitate those patients in whom a complete hypoglossal-to-facial nerve transfer has resulted in tongue dysfunction.

In the patients who have undergone complete hypoglossal-to-facial nerve transfer, moderate hemiglossal atrophy has been reported to occur in 50 percent and severe hemiglossal atrophy in 25 percent, with swallowing problems in 10 percent and speech problems in 16 percent.<sup>10</sup> An approach to rehabilitate the tongue with these problems, by transferring an innervated flap from the contralateral tongue, is presented in two patients.

### CASE REPORTS

#### Case 1

A 16-year-old girl was seen 5 years after a benign brain tumor resection left her with a complete left facial paralysis. Three years after the cranial tumor resection, she had a hypoglossal-to-facial nerve transfer, which did not result in any facial reinnervation but did result in left hemiglossal atrophy (Fig. 1, *left*). Her speech was mildly impaired and she had difficulty with chewing her food and swallowing. A triangular flap was designed with its base positioned to permit innervation by the contralateral hypoglossal nerve. An incision into the atrophic side of the tongue was outlined (Fig. 1, *center*) to permit the new flap to increase its bulk, rather than the traditional switch of flaps as with a Z-plasty. At follow-up 1 year after the tongue flap, tongue protrusion was midline, and her speech and deglutition problems were corrected (Fig. 1, *right*).

#### Case 2

A 47-year-old woman was seen 3 years after resection of an acoustic neuroma and contemporaneous left-sided complete hypoglossal-to-facial nerve transfer. About 9 months later, she had severe atrophy of the left side of the tongue (Fig. 2, *above, left*). This impaired her speech such that she was intelligible in the morning, but by evening, with muscle fatigue, her locution was unintelligible. Similarly, swallowing was arduous later in the day. She also experienced drooling along the left commissure.

A half-Z-plasty was designed from the trophic right tongue to the atrophic left tongue (Fig. 2, *above, right*). After transposition of the flaps, the incision was closed (Fig. 2, *below, left*). Eighteen-month follow-up demonstrated midline tongue protrusion (Fig. 2, *below, right*). Her speech was intelligible in person and also over the telephone and she reported subjective amelioration but not resolution of her swallowing difficulties. Oral continence was normal and she no longer had a chronic candidal rash along the left commissure, where she previously drooled. Moreover, she had improvement in her taste sensation, no longer complaining of a bitter taste in her mouth, and was able to taste on both sides of her tongue.

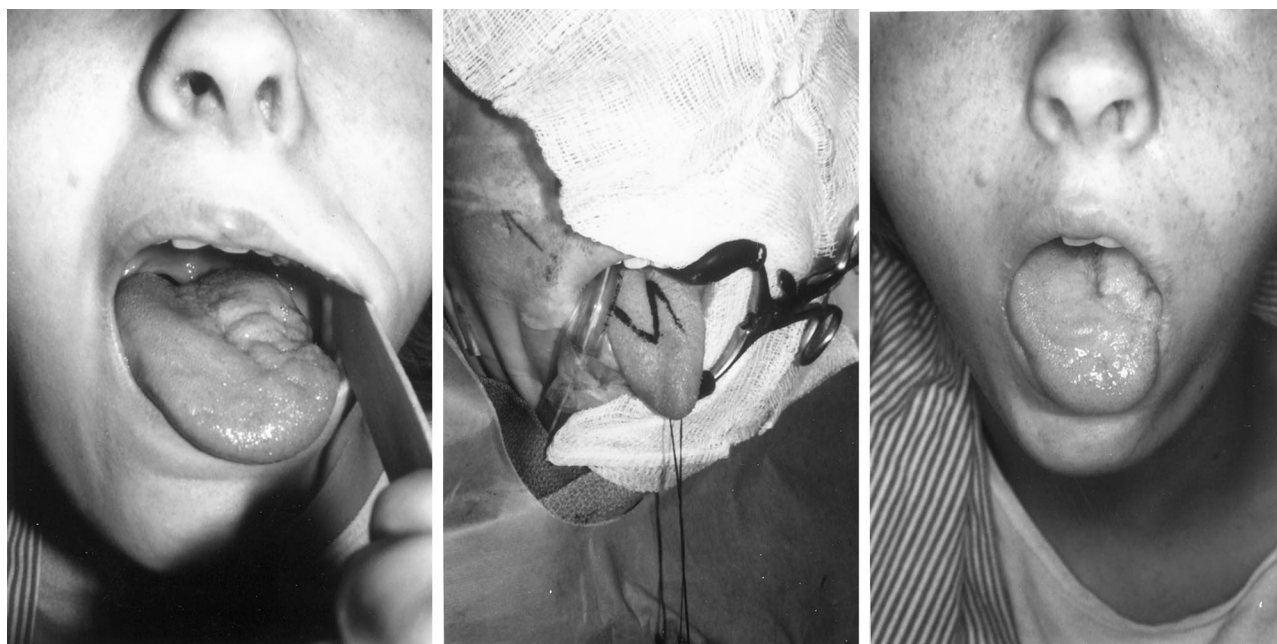

FIG. 1. Patient in case 1. (Left) Preoperatively; (center) design of flap; (right) postoperatively.

#### SURGICAL TECHNIQUE

Musculomucosal flaps are outlined leaving the distal 1.5 cm of tongue on either side. A 2-0 silk suture is placed in the tip of the tongue for traction. The flap is 1.5 cm at its base and 2 cm at either limb, and is based posteriorly and laterally on the normal side. A 2-cm incision is made at a 60-degree angle through the tongue on the atrophic side after first infiltrating with anesthetic solution with 1:200,000 epinephrine. The flaps are cut as full-thickness flaps, hemostasis is achieved with electrocautery, and flaps are transposed. Suturing is accomplished with 4-0 polyglactic suture. It is possible to appreciate the volume correction of the tongue in the operating room; moreover, the tongue will lay straight in the mouth immediately.

#### DISCUSSION

The tongue is striated muscle invested with a mucous membrane with its anterior two-thirds in the mouth and posterior one-third in the pharynx, divided sagittally by a median fibrous septum. The intrinsic musculature of the tongue, innervated by the hypoglossal nerve, is composed of longitudinal, transverse, and vertical fibers originating on the median septum and submucosa and inserting on the mucous membrane. Thus, the shape of the tongue is controlled by the hypoglossal nerve acting on the intrinsic tongue musculature.

The mechanisms by which the outlined transposition flap results in improved tongue coordination are (1) rearrangement of the median fibrous septum on which these muscles originate, such that unilaterally directed hypoglossal action results in muscle action on the entire tongue (the flap could contain enough tongue musculature to motor the inanimate side);<sup>11</sup> or (2) introduction of vascularized and trophic striated muscle cut fibers onto cut atrophic muscle fibers, allowing trophic muscle fibers to fuse to atrophic fibers. Experimental and clinical cases have shown that nerve axons can sprout from the cut edges of innervated muscles to denervated muscle and form new myoneural junctions. Reinnervation of a denervated muscle by adjacent muscle as a mechanism was proposed by Thompson<sup>12</sup> in 1971 and demonstrated by Hakelius<sup>13</sup> and Miller et al.<sup>14</sup> by using free-muscle grafts and demonstrating return of function simply by being placed adjacent to neurotized muscle. This same mechanism is postulated in a study of cynomolgus monkeys by Dellon and Mackinnon,<sup>15</sup> who hypothesized that a denervated muscle initially undergoes atrophy and later reversal if an adjacent innervated muscle sprouts into the denervated muscle. It is this same adjacent-neurotization mechanism that is postulated in the lack of glossal atrophy in up to 22 percent of patients after a complete hypoglossal transfer—neurotization is proceed-



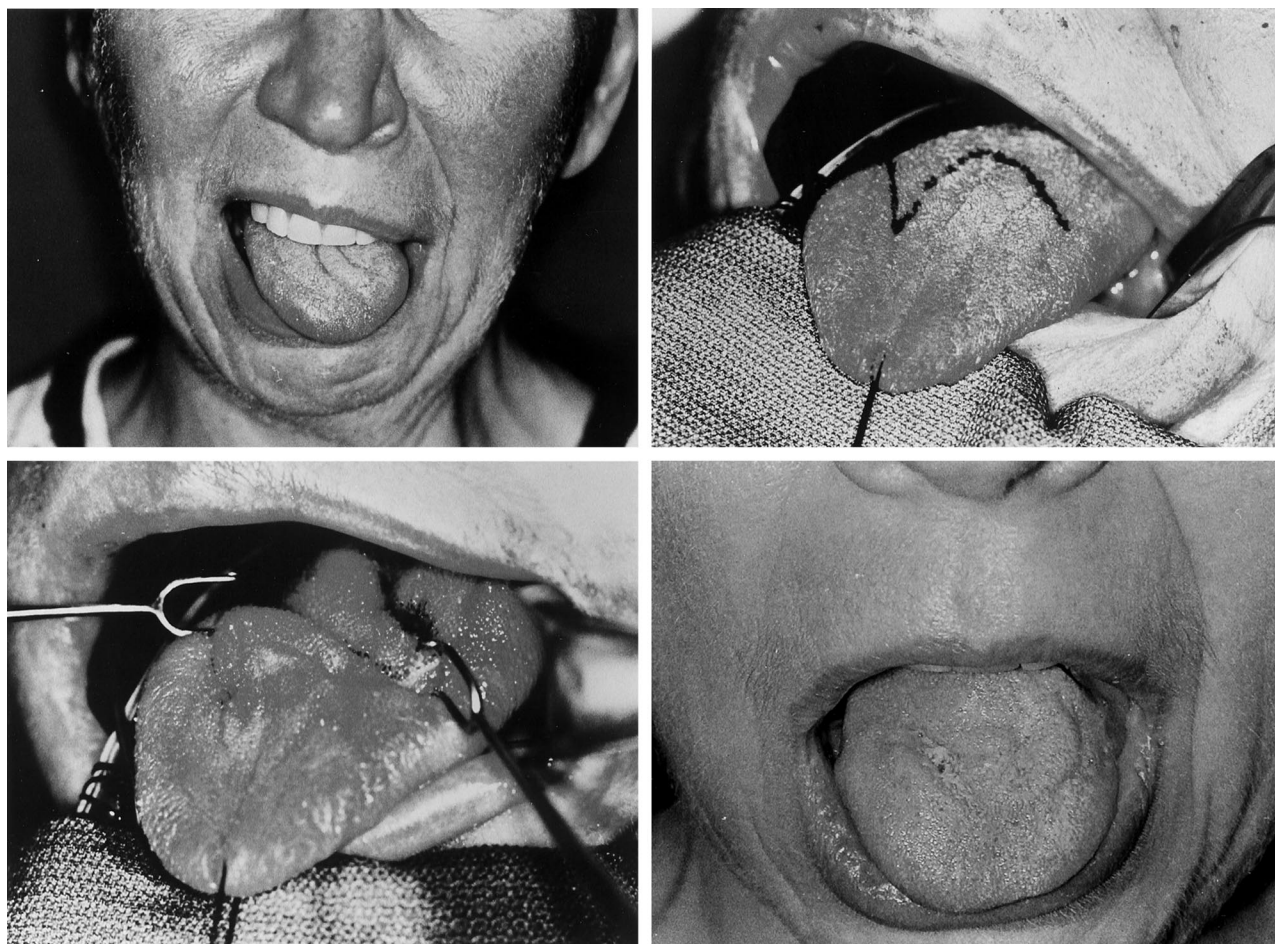


FIG. 2. Patient in case 2. (Above, left) Preoperatively; (above, right) design of flap; (below, left) flap being transposed; (below, right) postoperatively.

ing from the normal half of the tongue without a flap procedure. In those that have moderate to severe glossal atrophy, a half-Z-plasty as we describe in this technique can provide the stimulus for adjacent-muscle neurotization. Because of adjacent motor neurotization after the half-Z-plasty, there is reorganization of motor units when transected nerve fibers traversing the muscle sprout into contralaterally transposed denervated muscle, returning cohesive tongue function. The flap design, being full thickness and posteriorly based, allows incorporation of taste, touch/temperature sensation, and motor innervation, which explains the return of taste sensation in case 2.

It is suggested that this form of tongue rehabilitation has a role in the treatment of patients who have had prior hypoglossal-to-facial nerve transfers or unilateral complete hypoglossal nerve transactions from other causes (i.e., as a complication of carotid endarterectomy). This form of tongue rehabilitation improves speech,

improves saliva control, and stops drooling. The histology of such a flap should be investigated to substantiate the mechanisms postulated from clinical observations and success of this technique.

A. Lee Dellon, M.D.  
3333 North Calvert Street  
Suite 370  
Baltimore, Md. 21218  
aldellon@erols.com

#### REFERENCES

1. Dellon, A. L. Restoration of facial nerve function: An approach for the twenty-first century. *Neurosurg. Q.* 2: 199, 1992.
2. Falbe-Hansen, J., and Hermann, S. Hypoglossal-facial nerve anastomosis. *Acta Neurol. Scand.* 43: 472, 1967.
3. Evans, D. M. Hypoglossal-facial anastomosis in the treatment of facial palsy. *Br. J. Plast. Surg.* 27: 251, 1974.
4. Conley, J., and Baker, D. C. Hypoglossal-facial nerve anastomosis for reinnervation of the paralyzed face. *Plast. Reconstr. Surg.* 63: 63, 1979.
5. Pensak, M. L., Jackson, C. G., Glasscock, M. E., III, and Gulya, A. J. Facial reanimation with the VII-XII anas-

- tomosis: Analysis of the functional and psychologic results. *Otolaryngol. Head Neck Surg.* 94: 305, 1986.
6. Anderl, H. Reconstruction of the face through cross-face nerve transplantation facial paralysis. *Chir. Plast.* 2: 17, 1973.
  7. Ferreira, M. C., Marchese, A. T., and Spinno, Y. Injertos transfaciales des nervios en el tratamiento de la parálisis facial observaciones iniciales. *Chir. Plast. Ibero Lat. Am.* 3: 301, 1977.
  8. Mackinnon, S. E., and Dellon, A. L. Facial nerve injury. In S. E. Mackinnon and A. L. Dellon (Eds.), *Surgery of the Peripheral Nerve*. New York: Thieme, 1988. Pp. 393–420.
  9. Terzis, J. K. Personal communication, 1998.
  10. Conley, J. Management of facial nerve paresis in malignant tumors of the parotid gland. In L. R. Rubin (Ed.), *Reanimation of the Paralyzed Face*. St. Louis: Mosby, 1977. Pp. 229–230.
  11. Rubin, L. R., Mishriki, Y. Y., and Speace, G. Reanimation of the hemiparalytic tongue. *Plast. Reconstr. Surg.* 73: 184, 1984.
  12. Thompson, N. Autogenous free grafts of skeletal muscle. *Plast. Reconstr. Surg.* 48: 11, 1971.
  13. Hakelius, L. Transplantation of free autogenous muscles in the treatment of facial paralysis. *Scand. J. Plast. Reconstr. Surg.* 8: 220, 1974.
  14. Miller, T. A., Korn, H. N., Wheeler, E. S., et al. Can one muscle innervate another? A preliminary study of muscular neurotization in the rabbit. *Plast. Reconstr. Surg.* 61: 50, 1978.
  15. Dellon, A. L., and Mackinnon, S. E. Reanimation following facial paralysis by adjacent muscle neurotization: Experimental model in the primate. *Microsurgery* 10: 251, 1989.



**Unauthorized Use  
Prohibited**