

Robotics in Plastic and Reconstructive Surgery: Use of a Telemanipulator Slave Robot to Perform Microvascular Anastomoses

Ryan D. Katz, M.D.,¹ Jesse A. Taylor, M.D.,¹ Gedge D. Rosson, M.D.,¹
Phillip R. Brown, D.V.M.,¹ and Navin K. Singh, M.D., M.S.¹

ABSTRACT

Many methods for microvascular anastomoses exist, including use of magnifying loupes ($\times 2.5$, $\times 3.5$, $\times 4.5$, $\times 6$), but the operating microscope remains the gold standard. The authors present the da Vinci[®] Surgical System (Intuitive Surgical, Sunnyvale, CA) as an alternative method for performing microvascular anastomoses. The da Vinci robot has fully articulating microinstruments with six degrees of freedom, the ability to filter tremor, the capability to perform telesurgery, and the advantage of 3-D visualization. It offers full and dynamic control over the operating camera, allowing variable positioning and the ability to scale down movements. Its drawbacks include initial high cost, lack of haptic feedback, decreased participation of the first assistant, and lack of widespread availability.

In this feasibility study, multiple microanastomoses were performed in canine tarsal and superficial femoral vessels.

KEYWORDS: Robot, da Vinci, microsurgery

First generation surgical robots consisted mainly of robotic arms designed to assist the primary surgeon by holding and positioning instruments such as a laparoscopic camera or retractor. Newer surgical robots have transcended the role of assistant to become the primary surgeon's hands through a computer interface.¹ One such robot, the da Vinci[®] Surgical System (Intuitive Surgical, Inc., Sunnyvale, CA) incorporates 3-D stereoscopic vision with two (or three, depending on model) robotic slave-arms that can be equipped with instruments that have six degrees of freedom and wrist-like motions. It has the ability to filter tremor, gives the primary surgeon dynamic control over the camera, and offers the surgeon the option of scaling down motions to allow ultra-fine manipulations—all

of which provide clear benefit to the operating surgeon. Thus, it is no surprise that many surgical specialties are applying this new technology. Cardiac surgeons have used the da Vinci to perform successful closed-chest internal mammary artery harvesting, coronary artery bypass grafts, and mitral valve repair.²⁻⁴ Urologists have used the robot to successfully perform radical prostatectomies and nephrectomies.^{5,6} General surgeons have used it for minimally invasive cholecystectomy, Nissen fundoplication, gastric bypass, and adrenalectomy.^{7,8}

The same attributes that make the da Vinci robot suitable for minimally invasive surgery make it an attractive option for performing microsurgery, a discipline that demands optimal visualization,

Journal of Reconstructive Microsurgery, Volume 22, Number 1, 2006; accepted for publication September 20, 2005. Address for correspondence and reprint requests: Navin K. Singh, M.D., M.S., Division of Plastic, Reconstructive, and Maxillofacial Surgery, The Johns Hopkins University School of Medicine, McElderry 8152-C, 601 N. Caroline, Baltimore, MD 21287-0980. ¹The Johns Hopkins University School of Medicine, Baltimore, MD. Copyright © 2006 by Thieme Medical Publishers, Inc., 333 Seventh Avenue, New York, NY 10001, USA. Tel: +1(212) 584-4662. 0743-684X,p;2006,22,01,053,058,ftx,en:jrm01160x.

minimization of tremor, technical skill, and precise surgical manipulations. Many methods for microvascular anastomoses exist, including use of magnifying loupes ($\times 2.5$, $\times 3.5$, $\times 4.5$, $\times 6$), but the operating microscope has remained the gold standard. Using a canine model, we demonstrate that both arterial and venous microvascular anastomoses can be successfully performed with the da Vinci robot.

MATERIALS AND METHODS

Robotic Setup The da Vinci robot was draped in a sterile fashion. Each slave arm was equipped with sterile “black diamond microforceps” [Fig. 1] (Intuitive Surgical, Inc., Sunnyvale, CA). Our da Vinci robot has two slave arms only; some newer models are equipped with a third arm that may be equipped with microscissors for cutting. The slave arms were positioned over a previously dissected surgical site. [Figs. 2,3]

Preparation of Surgical Site Two freshly sacrificed 30-kg mixed breed dogs were prepped and draped in the usual sterile fashion, and all procedures were performed using aseptic technique. After shaving the surgical site, a 4-cm vertical incision was made at a distance one third of the way between the pubic symphysis and anterior superior iliac spine. The femoral vessels were then identified, isolated, and cleaned of surrounding soft tissue. This process was repeated in the contralateral groin. The lateral aspect of the animals’ hind legs was shaved at the level of the knee. A 4-cm vertical incision was made at this site and carried down to the level of the recurrent tarsal vein. This vessel was isolated and cleaned of surrounding soft tissue.

Robotic Operative Technique After vessel preparation, a double approximating vascular clamp was placed on the vessel by the first assistant. The microvessels were then transected. These vessels were measured and ranged



Figure 1 Black diamond microforceps.

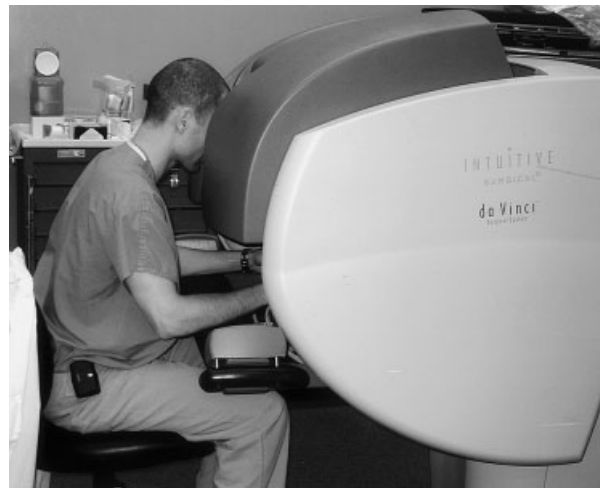

Figure 2 The surgeon seated at the “surgeon’s console” with hands in the “masters” (master controls for the slave arms and camera).

from 1.5 to 2.5 mm, with the average diameter measuring approximately 2 mm. The primary surgeon, positioned at the surgeon’s console, then took control of the machine’s “masters” (master controls for the slave arms and camera) and performed an interrupted, end-to-end, microvascular anastomosis using 8-0 nylon sutures. This process was repeated for all vessels. All sutures were cut by the first assistant.

Operating Time All anastomoses were performed by the same surgeon. The operating time was measured using a digital timer. The timer was started upon placement of microvascular clamps and was stopped upon clamp removal. Setup time was also measured using a digital timer. The timer was started prior to draping the first “slave arm” and was stopped once the robot was wheeled into the appropriate operating position. All times were rounded up to the nearest minute.

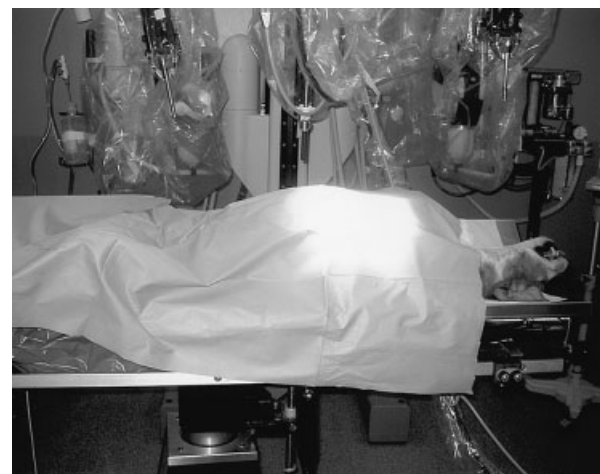

Figure 3 Robot draped and positioned over the patient.

Postoperative Evaluation Postoperatively, each vessel was assessed for patency by clamping off the proximal end and injecting 10 cc of normal saline through a 25-G needle in a proximal to distal fashion. An easy flush, as well as vessel distension proximal and distal to the anastomosis, was considered a sign of patency. Each vessel was then harvested for gross and microscopic evaluation of patency and suture placement. Operating times were also recorded starting from the moment the vessel was cut.

RESULTS

Patency Six of six vessels were noted to be patent. Grossly, the anastomoses appeared circular, with good eversion of the vessel edges. Microscopically, the sutures were noted to contain intima, media, and adventitia. There were no back-wall sutures. [Figs. 4–6]

Setup Time The initial setup time was 45 min. This time decreased to an average of 31 min for the remaining five anastomoses (Table 1, Fig. 7).

Anastomosis Time The first two anastomoses took 67 min and 70 min, respectively. The operating time was noted to consistently decrease with each anastomosis. (Table 2, Fig. 7).

DISCUSSION

The field of microsurgery continues to evolve to produce quality reconstructions with less morbidity. Well-trained practitioners, coupled with good instrumentation, produce reliable results close to 100 percent of the time. Our study validates the feasibility of microarterial and microvenous anastomoses with the da Vinci robot.

Although current microsurgical techniques are effective and reliable, limitations include a steep learning curve, the inability to eliminate tremor, and rigid

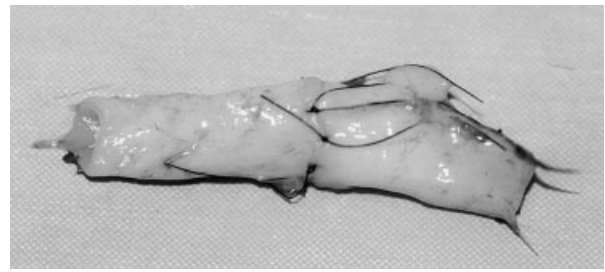


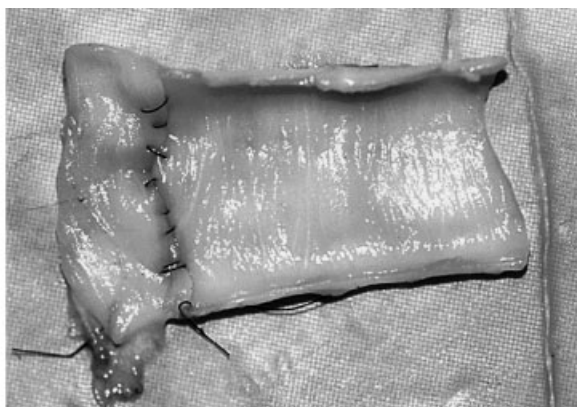
Figure 4 Representative vessels after robotically-assisted microvascular anastomosis.

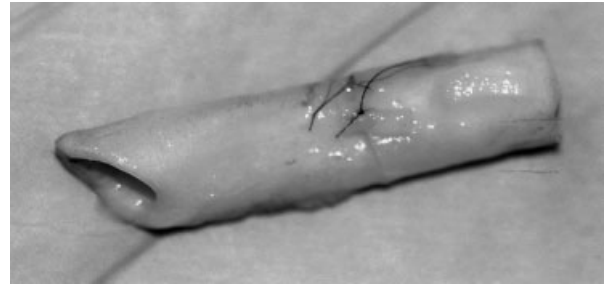


Figure 5 Representative vessels after robotically-assisted microvascular anastomosis.

non-articulating instruments.^{9,10} The da Vinci surgical system, a surgical robot armed with 3-D dynamic visualization, fully articulating instruments, scalable movements, and the ability to minimize tremor, has the potential to overcome these limitations. These benefits have already been recognized by surgeons of various specialties who are using the machine to successfully perform a variety of procedures.

When using the da Vinci robot, the primary surgeon operates from a seated position at the “surgeon’s console” (see Fig. 2). This position, as well as the ergonomic surgical controls (or “masters”), minimize hand fatigue. Through the “masters,” every movement made by the surgeon is replicated in real time by two



A



B

Figure 6 [A,B] Vessels have been filleted open to demonstrate stitch placement and endoluminal profile.

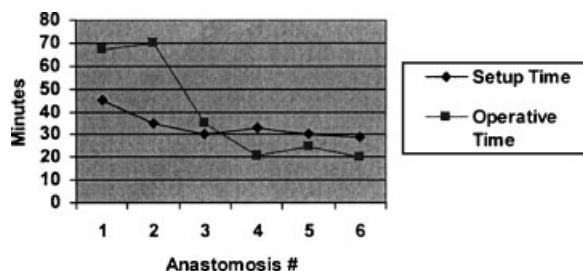
Table 1 Setup Time Necessary to Prepare the Robot Prior to each Operation

Setup (#)	Time (minutes)
1	45
2	35
3	30
4	33
5	30
6	29

surgical “slave arms.” These movements can be scaled down to allow increased accuracy and precision.^{11,12} Each slave arm can be equipped with a fully articulating instrument offering the surgeon wrist-like motions and six degrees of freedom (in, out, pitch, yaw, up, down). This allows easy access to any point in the three-dimensional operative space. The wrist-like response of the instruments feels quite natural and, in our experience, makes using the machine quite instinctive and spontaneous. The rapid learning curve and decreasing operative times seen in this study reflect this concept (see Fig. 7). Similar learning-curve trends have previously been described by surgeons of various specialties.^{13,14} Of interest, the time to completion of our robotically-assisted microanastomoses was ultimately similar to that of completing traditional microanastomoses.

An added benefit to the increased instrument mobility is the ease with which the surgeon can maneuver within small, anatomically confined spaces.¹⁵ This could greatly facilitate operating in otherwise technically demanding environments, such as the axilla in breast reconstruction or around bulky external fixators during reconstruction of traumatic limb injuries.

Setting up the da Vinci robot does require both time and effort.¹⁶ In our study, the set up time ranged from 29 to 45 min. All draping should be done prior to beginning the case and, if performed by knowledgeable staff, should take no longer than setting up an operating microscope. Since the microsurgeon will be using the machine extracorporeally, there is no need to expend time on port placement or instrument changes, as described in the endoscopic literature.¹⁶

**Figure 7** Line graph demonstrating setup time and operating time for each anastomosis.**Table 2 Operating Time for each Anastomosis**

Anastomosis (#)	Time (minutes)
1	67
2	70
3	35
4	21
5	25
6	20

The operating field is viewed three-dimensionally through a viewing port located at the surgeon's console. From this console, the surgeon can easily adjust the focus and zoom as well as rotate the operating field of view without repositioning either the patient or the machine. We found this latter trait to be particularly useful for operating on the tarsal vein which, prior to visual reorientation, was positioned nearly perpendicular to the field of view. Although there is, at present, no true microsurgical instrument set designed for this machine, we found the “black diamond microforceps” (see Fig. 1) delicate enough to handle both the vessel and suture.

An obvious drawback to using the da Vinci robot for microsurgical procedures is the initial cost of acquiring the machine (roughly \$1 million), as well as the associated cost of personnel training, machine maintenance, and repairs. As with many new technologies, this cost may be prohibitively high to justify its use—especially in today's environment in which traditional microsurgical techniques have such high success rates. However, when costs are shared across specialties (urology, general surgery, and cardiac surgery), the device may, in the long run, prove cost-effective. Certainly, as in this particular case, if the device has already been acquired by the institution, then its broader use by additional specialties (such as plastic surgery) actually has minimal incremental costs and helps decrease variable costs for the other specialties.

Finally, this machine is limited by its lack of force feedback. Although this should not be a problem for the experienced microsurgeon with knowledge of the forces required to safely manipulate the tissues, a lack of haptic feedback carries with it the inherent risk of undue tissue trauma—especially for the neophyte.¹⁷

CONCLUSIONS

This study introduces a role for robotics in the field of microsurgery. Although traditional microvascular techniques are quite successful, there are inherent human and mechanical limitations that can be overcome with robotic assistance. Despite its drawbacks, the da Vinci robot offers the microsurgeon certain tools and abilities otherwise unavailable to the unaided human. In a field in

which success or failure often hinges on technique, such tools could be very useful. In addition, the da Vinci robot offers the possibility of true telepresence surgery. Further experimentation to delineate the role of robotics in the field of microsurgery is warranted.

REFERENCES

1. Ballantyne G. Robotic surgery, telerobotic surgery, telepresence, and telemonitoring. *Surge Endosc* 2002;16:1389–1402
2. Stephenson E Jr, Sankholkar S. Robotically assisted microsurgery for endoscopic coronary artery bypass grafting. *Ann Thorac Surg* 1998;66:1064–1067
3. Bonatti J, Schachner T. Robotic totally endoscopic coronary artery bypass: program development and learning curve issues. *J Thorac Cardiovasc Surg* 2004;127:504–510
4. Tatoes A, Pappas P. Minimally invasive mitral valve repair using the da Vinci robotic system. *Ann Thorac Surg* 2004;77:1978–1982; discussion 1982–1984
5. Bentas W, Wolfram M. Robotic technology and the translation of open radical prostatectomy to laparoscopy: the early Frankfurt experience with robotic radical prostatectomy and one year follow-up. *Eur Urol* 2003;44:175–181
6. Horgan S, Vanuno D. Early experience with robotically assisted laparoscopic donor nephrectomy. *Surg Laparosc Endosc Percutan Tech* 2002;12:64–70
7. Horgan S, Vanuno D. Robots in laparoscopic surgery. *J Laparoendosc Adv Surg Tech A* 2001;11:415–419
8. Ayav A, Bresler L. Early results of one-year robotic surgery using the da Vinci system to perform advanced laparoscopic procedures. *J Gastrointest Surg* 2004;8:720–726
9. Khouri R, Cooley B. A prospective study of microvascular free-flap surgery and outcome. *Plast Reconstr Surg* 1998;102:711–721
10. Kelly J, Eadie P. Prospective evaluation of outcome measures in free-flap surgery. *J Reconstr Microsurg* 2004;20:435–438
11. Siemionow M, Ozer K. Robotic assistance in microsurgery. *J Reconstr Microsurg* 2000;16:643–649
12. Le Roux P, Das H. Robot-assisted microsurgery: a feasibility study in the rat. *Neurosurgery* 2001;48:584–589
13. Hanly E, Marohn M. Multiservice laparoscopic surgical training using the da Vinci surgical system. *Am J Surg* 2004;187:309–315
14. Yohannes P, Rotariu P. Comparison of robotic versus laparoscopic skills: is there a difference in the learning curve?. *Urology* 2002;60:39–45; discussion 45
15. Cadiere GB, Himpens J. Feasibility of robotic laparoscopic surgery: 146 cases. *World J Surg* 2001;25:1467–1477
16. Talamini M, Chapman S. A prospective analysis of 211 robotic-assisted surgical procedures. *Surg Endosc* 2003;17:1521–1524; Epub 2003 Aug 15
17. Brett P, Ma X. The potential of robotic technology applied to meet requirements for tools to support microsurgery and cellular surgery. *Cell Mol Biol* 2004;50:275–280
18. Li R, Jensen J. Microvascular anastomoses performed in rats using a microsurgical telemanipulator. *Computer Aided Surg* 2000;5:326–332

