

# Pocket Conversion Made Easy: A Simple Technique Using Alloderm to Convert Subglandular Breast Implants to the Dual-Plane Position

M. Mark Mofid, MD; and Navin K. Singh, MD

**BACKGROUND:** The advantages of dual-plane, partially submuscular breast implants are well documented. Standard conversion techniques to dual-plane positioning use marionette sutures and internal capsulorrhaphy sutures from the lower edge of the pectoralis major muscle to the anterior capsule or breast fascia within the subglandular plane. These techniques are limited by high rates of postoperative implant malposition and technical limitations that make combined mastopexy procedures difficult to perform.

**OBJECTIVE:** We describe a simple technique familiar to most plastic surgeons accustomed to placing tissue expanders for use in breast reconstruction using Alloderm (LifeCell Corp., Branchburg, NJ) as a sling beneath the pectoralis major muscle to the chest wall.

**METHODS:** We studied 25 women who underwent breast augmentation revision from the subglandular to the dual-plane position by performing a 9-year retrospective review from 1999 to 2007 of 2 surgeons' experience. We identified 10 women for whom Alloderm, sutured from the lower edge of the pectoralis major muscle to the chest wall, was used to create a composite pectoralis–Alloderm pocket for partial submuscular transfer of implants and 15 case controls who underwent pocket conversion using standard capsulorrhaphy and marionette suture techniques.

**RESULTS:** The principal outcome variable of at least 1 complication was 73.3% without Alloderm, resulting in a 40% need for revision surgery, versus 0% with Alloderm (Fisher exact test;  $P < .05$ ).

**CONCLUSIONS:** The standard techniques available for conversion of subglandular breast implants to the dual-plane position using capsulorrhaphy and marionette sutures are limited by a high complication rate for the reliable positioning into a stable dual-plane pocket during implant exchange. A commonly used technique in reconstructive breast surgery using Alloderm is shown to reliably convert subglandular implants to the dual-plane position. (*Aesthetic Surg J* 2009;29:12-18.)

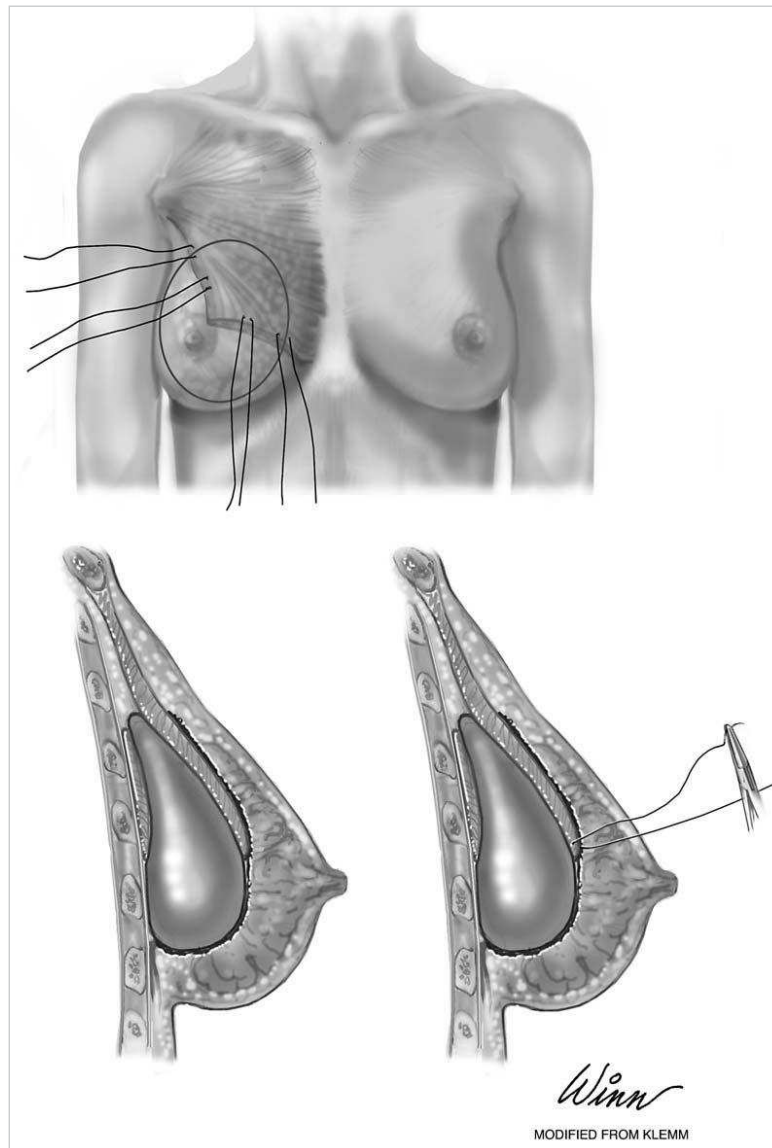
The use of Alloderm (LifeCell Corp., Branchburg, NJ) for implant-based breast reconstruction and revisionary breast surgery has been extensively documented within the plastic surgery literature.<sup>1-4</sup> After mastectomy, a subpectoral pocket is created for the implant or tissue expander. Alloderm is sewn to the lower pole of the released muscle superiorly, to the chest wall inferiorly, and to the serratus anterior muscle laterally. Interposition of a prosthetic sling inferiorly allows for thicker muscle coverage in the upper and medial poles and for lower pole support while at the same time

increasing the capacity of the pectoralis major pocket. The use of Alloderm has also been described for use in revision breast surgery for the repair of symmastia, periprosthetic atrophy, and implant malposition as onlay grafts to reinforce the periprosthetic capsule.<sup>5</sup>

The conversion of breast implants situated within the subglandular plane into the dual-plane position for the correction of capsular contracture using a combination of capsulorrhaphy and marionette sutures has been most recently described by Spear et al.<sup>5</sup> The advantages of dual-plane, partially submuscular breast implants include decreased rates of capsular contracture, improved upper pole fullness, decreased palpability and visibility of implants, and improved breast aesthetics in cases where the soft tissue envelope is inadequate to support subglandular implants. The tabulation of complications within

---

Dr. Mofid is from the Division of Plastic Surgery, Department of Surgery, University of California–San Diego School of Medicine, San Diego, CA. Dr. Singh is from the Division of Plastic Surgery, Department of Surgery, The Johns Hopkins School of Medicine, Baltimore, MD.



**Figure 1.** **A**, Implant in position with marionette sutures placed at the inferior edge of the pectoralis major muscle. **B**, Implant in position in a patient with previously placed subglandular implant, before placement of marionette sutures. **C**, Implant in position with residual subglandular space obliterated by marionette sutures. (From Spear et al,<sup>5</sup> with permission.)

this subset of patients has not yet been reported in a series, and there have been no reports to date of combination pocket conversions from the subglandular to the dual-plane position with mastopexy. The limitations of capsulorrhaphy and marionette techniques are obvious in the breast that has undergone multiple operations or when a mastopexy procedure is performed in combination with pocket conversion, making achievement of reliable symmetry a technically difficult endeavor.

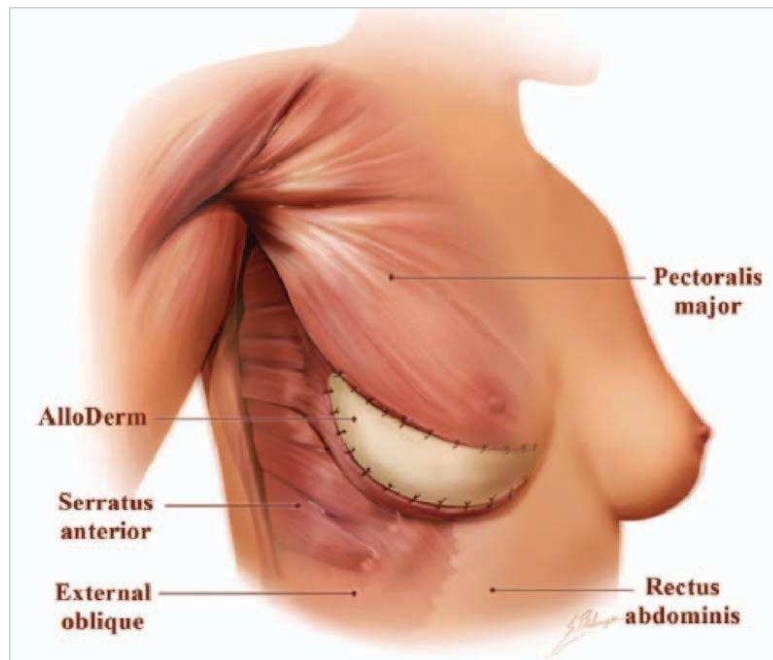
Isolated capsulorrhaphy for implant malposition has also been variously described, although there have been no reports to date of the upsizing of implants in combination with the repair of implant malposition or to address the “bottoming out” of implants.<sup>7</sup>

In this paper, we report the experience of 2 surgeons in the performance of conversion to dual-plane positioning using both standard suturing techniques described in the literature, and the use of Alloderm as a subpectoral sling, a technique commonly employed by plastic sur-

geons in contemporary implant-based reconstructive breast surgery.

## METHODS

A retrospective review was performed of patients with implant-related problems in the subglandular position treated by pocket conversion into the dual-plane position by the 2 authors of this study between 1999 and 2007. We identified 10 women for whom human acellular dermal matrix (Alloderm) sutured from the lower edge of the pectoralis major muscle to the chest wall was used to create a composite pectoralis–Alloderm pocket for partial submuscular transfer of implants, and 15 case controls who underwent pocket conversion using standard capsulorrhaphy and marionette suture techniques. Data analyzed at the time of revision surgery included patient age, implant size, the presence of saline versus silicone gel implants, duration from previous surgery, the presence of implant palpability or capsular contracture, need for



**Figure 2.** Placement of the AlloDerm graft. The graft is fixed to the pectoralis major muscle superiorly, to the perichondrium of the rib cage inferiorly and inferomedially, and to the serratus anterior muscle flap laterally. (From Zienowicz and Karacaoglu,<sup>3</sup> with permission.)

mastopexy, presence of intraoperative drains, and confirmation that existing implants were found within the subglandular plane. Independent variables analyzed included age, silicone gel versus saline implants, additional mastopexy, use of AlloDerm, drains, previous ruptured implants, and implant size change. Dependent variables included postoperative capsular contracture, pain, seroma, implant pocket displacement, inframammary fold discrepancy, infection, chronic pain, requirement for revision, and duration of surgery.

All patients received perioperative intravenous antibiotics and breast pocket irrigation with antibiotic solutions. At the time of surgery, all patients underwent a total or near total capsulectomy in order to obliterate the bursa-like surface within the subglandular pocket, and new implants were used during the exchange. In each case, the edge of the pectoralis major muscle was identified, released from its inferior chest wall insertion, elevated using cautery dissection, and released as far medially and laterally as necessary to achieve the desired pocket shape.

In each of the 15 case controls who underwent pocket conversion using standard capsulorrhaphy and marionette suture techniques, the procedures were performed as described by Spear et al<sup>6</sup> (Figure 1). New implants were placed within the pocket so that the superior two-thirds of the implant were within the subpectoral plane and the inferior one-third was in the subglandular plane. Internal stabilizing sutures using 2-0 polydioxanone were placed between the pectoralis major muscle and the anterior glandular tissue to stabilize the inferior muscle edge at or near the level of the areola. In addition, in some patients, half-mattress marionette sutures were placed between the skin and pectoralis major muscle to stabilize the inferior muscle edge in order to pre-

vent the new implant from dislodging back into the previous purely subglandular plane.

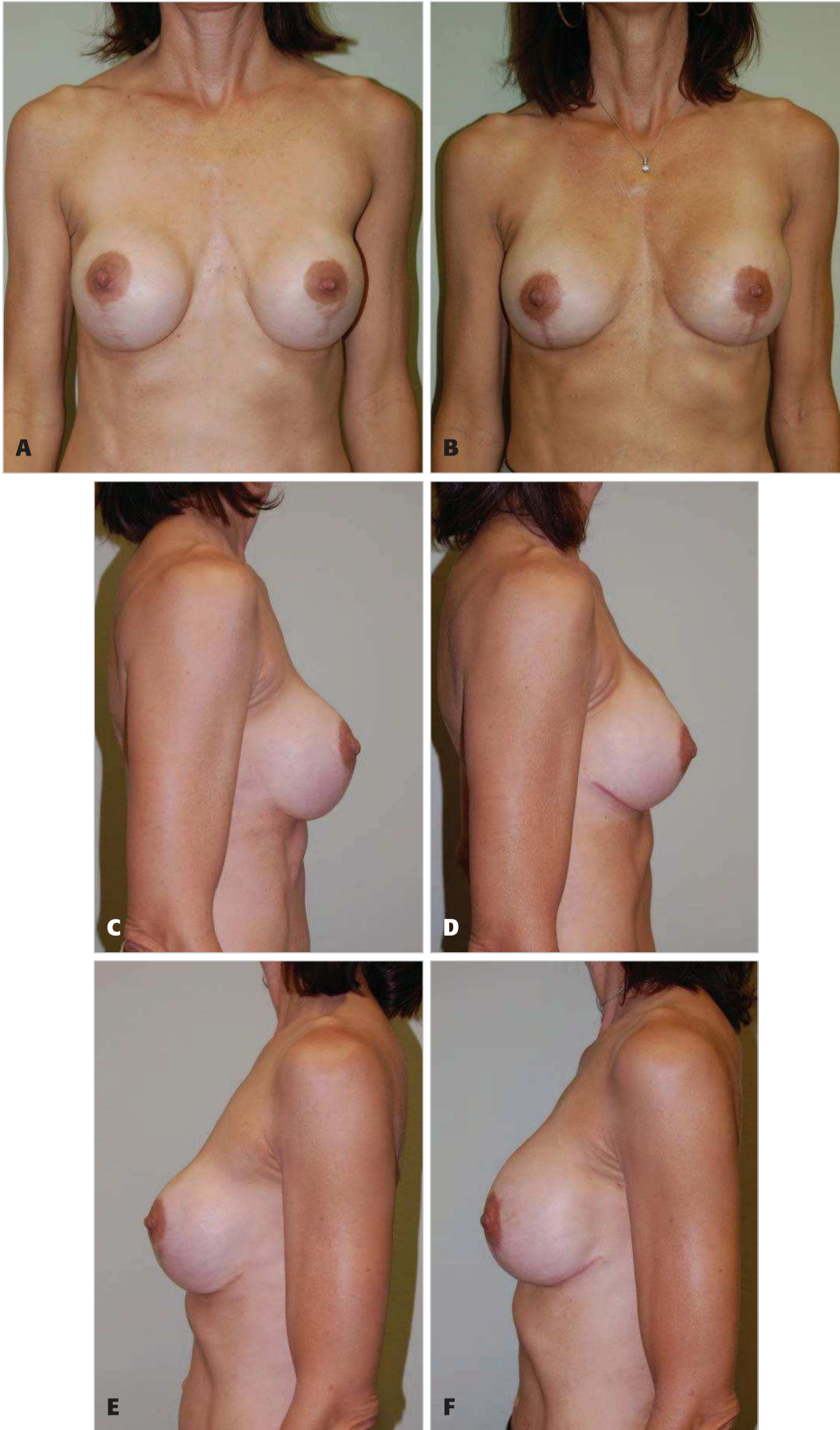
In the 10 patients in whom AlloDerm was used to create a composite pectoralis–AlloDerm pocket for partial submuscular transfer of implants (Figure 2), following full or partial capsulectomy and pectoralis major elevation as described above, a 4 cm × 16 cm sheet of AlloDerm was rehydrated in saline antibiotic baths according to the manufacturer’s instructions. Grafts were inset with the dermal side towards the skin–glandular envelope. Preexisting markings identifying the preexisting or neoinframammary fold (IMF) were used to guide suture placement using 2-0 polydioxanone to the fascia of the IMF and the serratus anterior muscle and fascia laterally. Implants were placed in situ before the closure of the lower edge of the pectoralis major muscle to the superior edge of the AlloDerm using 2-0 polydioxanone sutures. In several patients, drains were placed within the breast pocket and exited remotely through the axilla or lateral IMF.

Statistical analyses were performed using Stata statistical software (version 10; StataCorp, College Station, TX). Because of the small sample size, the Fisher exact test was used for comparisons of contingency tables. The *t* test was used to compare mean operating room times.

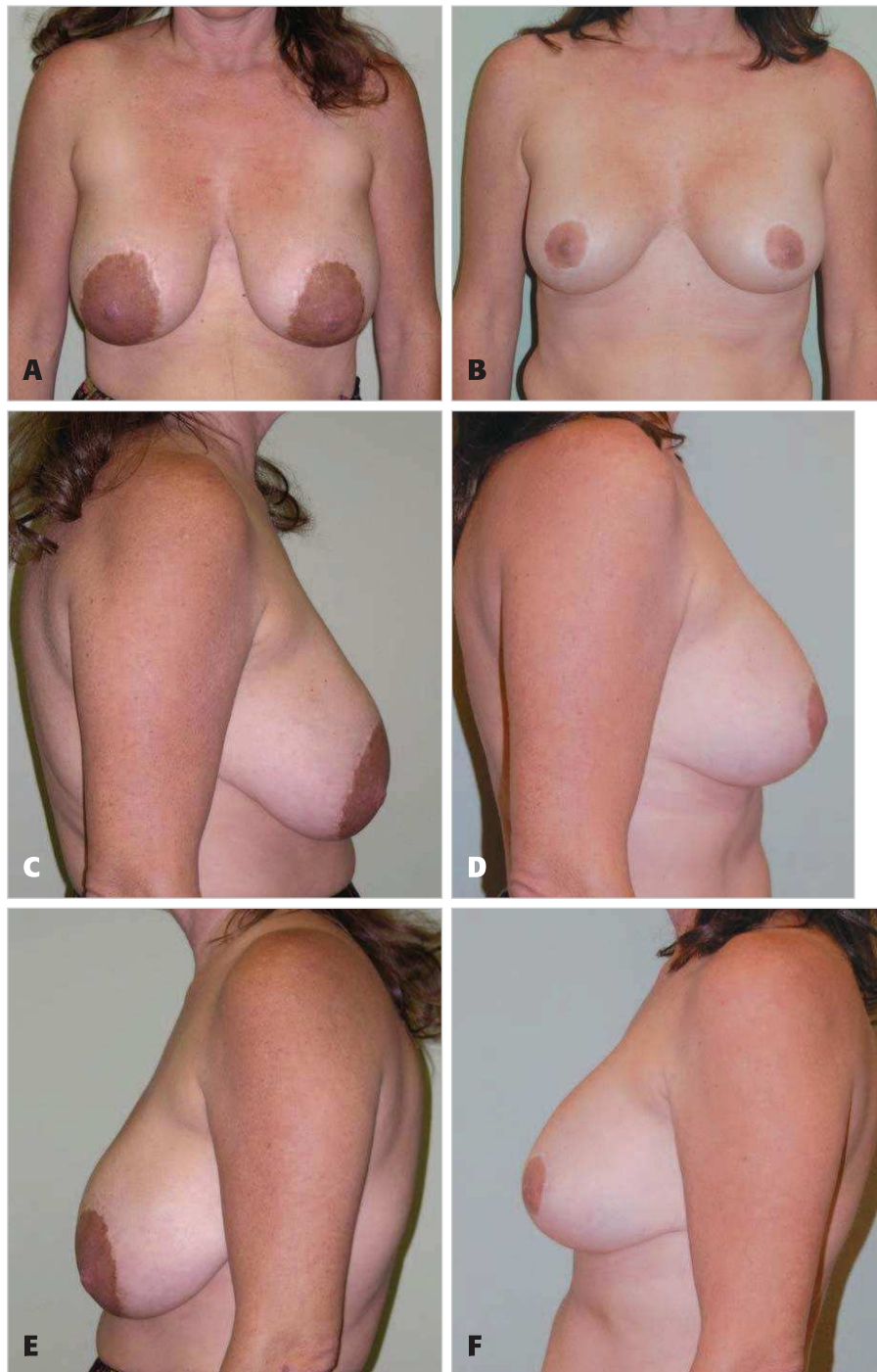
## RESULTS

The average patient age was 42 years (range, 29-56 yrs). The average implant size at the time of conversion was 323 cc (range, 200-500 cc); 74% of pocket-change patients also sought a size change. For the size change, 61% sought an increase and 39% sought a decrease in size. Indications for seeking revision were palpability (48%), capsular contracture (70%), and rupture (26%), which were not related to





**Figure 3. A, C, E,** A 51-year-old woman 8 years after bilateral revision vertical scar mastopexy and 10 years after bilateral breast augmentation with subglandular saline implants and vertical scar mastopexy. **B, D, F,** Postoperative views 4 months after bilateral breast implant exchange with silicone gel implants, conversion to the dual-plane position with Alloderm sling, and bilateral Wise pattern mastopexy.

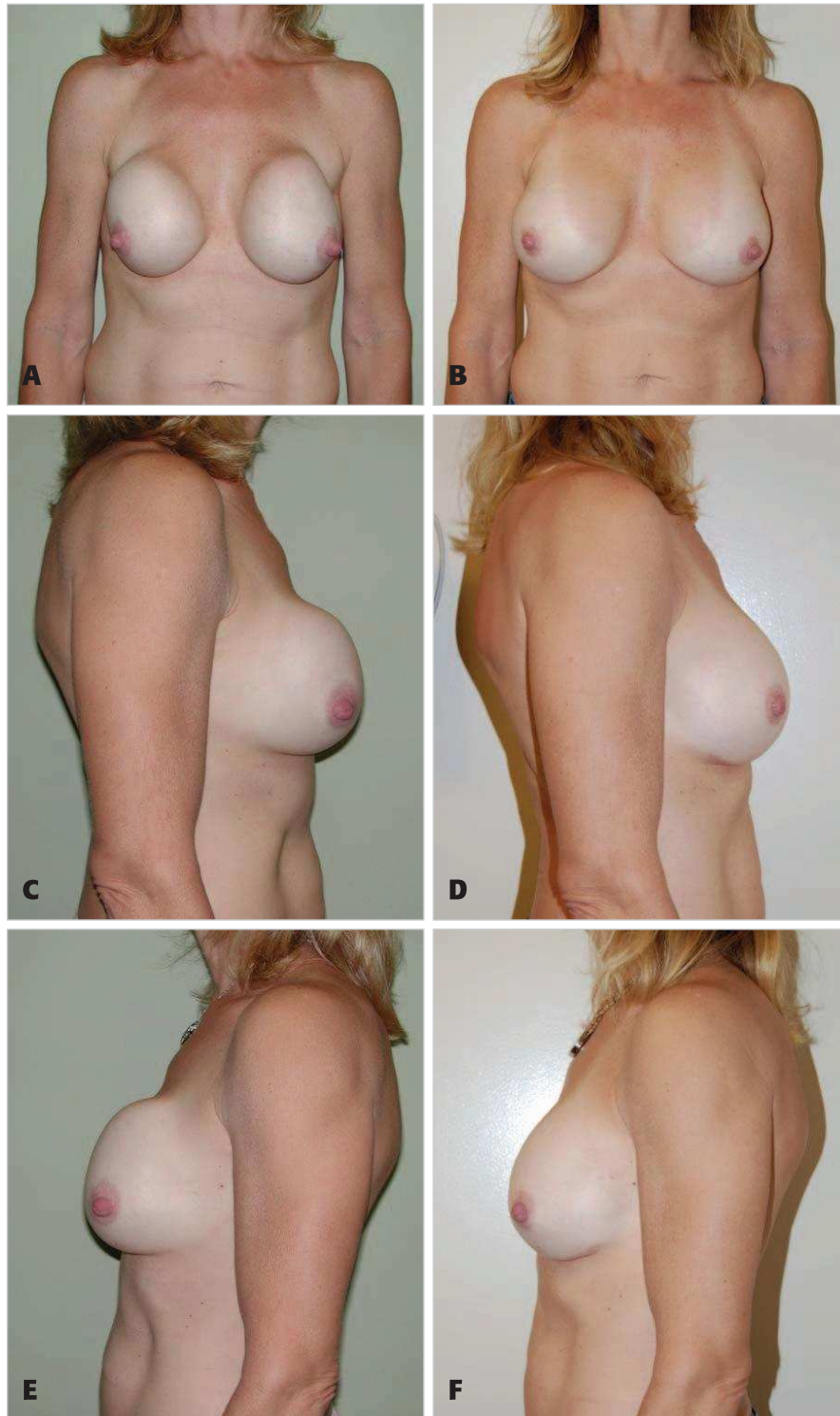


**Figure 4. A, C, E,** A 44-year-old woman 1 year after bilateral revision circumareolar mastopexy and 9 years after bilateral breast augmentation with subglandular saline implants and circumareolar mastopexy. **B, D, F,** Postoperative views 14 months after bilateral breast implant exchange with silicone gel implants, conversion to the dual-plane position with bilateral Alloderm sling, and bilateral vertical scar mastopexy.

silicone gel or saline implants (Fisher exact test;  $P = .40$ ). The average operative time (235 min) was not found to be significantly different between the groups ( $P = .49$ ;  $t$  test). The use of drains was not found to be correlated to the development of seromas and none were found in either group (Fisher exact test;  $P = .50$ ). The average period of follow-up in the conventional group (capsulorrhaphy and marionette sutures) was 21 months and the average follow up in the Alloderm group was 12 months. Dependent variables, including both postoperative capsular contracture and infection, were not found to be statistically significant,

with only one occurrence of each in the conventional pocket conversion group (Fisher exact test;  $P = .50$ ).

In 5 of the 10 patients in whom Alloderm was used, a previous pocket conversion had been attempted, and failed, using conventional pocket conversion techniques including capsulorrhaphy and marionette sutures. In only 1 of the 15 patients in whom conventional techniques were used was there a previous failure at pocket conversion, and this patient was found to have failed again with a resulting IMF fold discrepancy. In 4 of the 15 patients within the conventional pocket conversion group, a concurrent mastopexy



**Figure 5. A, C, E,** A 45-year-old woman 18 years after bilateral breast augmentation with subglandular silicone gel implants. **B, D, F,** Postoperative views 11 months after removal of ruptured silicone gel implants, bilateral breast implant exchange with new silicone implants, and conversion to the dual-plane position with bilateral Alloderm sling.

was performed; every patient within this subgroup developed at least 1 complication. In 5 of the 10 patients in whom Alloderm was used, a concurrent mastopexy was performed; there were no complications in this subgroup. Figures 3 to 5 document clinical summaries and patient photographs demonstrating the successful use of Alloderm for pocket conversion as a subpectoral sling.

Complications are presented in the Table. The principal outcome variable of at least 1 complication was

73.3% without Alloderm versus 0% with Alloderm (Fisher exact test;  $P < .05$ ), resulting in a 40% need for revision in the non-Alloderm group.

### DISCUSSION

In the field of aesthetic breast surgery, the conversion of subglandular to dual-plane breast implants is among the most challenging of cases. Using conventional capsulorrhaphy and marionette suture techniques, the additional com-



**Table.** Complications resulting from pocket conversion using capsulorrhaphy and marionette sutures (conventional techniques) versus Alloderm

Complication	Conventional pocket conversion (n = 15)	Alloderm sling pocket conversion (n = 10)
Pocket displacement	4 (26.7%)	0 (0%)
Inframammary fold displacement	5 (33.3%)	0 (0%)
Chronic pain	2 (13%)	0 (0%)
Need for revision	6 (40%)	0 (0%)
At least 1 complication	11 (73.3%)	0 (0%)

plexity involved in also performing an implant size change and mastopexy often results in a suboptimal outcome.

A technique familiar to most plastic surgeons versed in contemporary implant-based breast reconstruction using Alloderm has been adapted to the treatment of pocket conversion from the subglandular to dual-plane position. We feel that this technique allows the average plastic surgeon to achieve consistently good results with a minimum risk of complications. We have found that even though the group of 10 patients treated with Alloderm were cases of greater surgical complexity (5 of these 10 patients had already failed a previous pocket conversion attempt using standard techniques vs only 1 of 15 in the conventional technique group), the complication rates including need for surgical revision were significantly lower in the Alloderm group.

The cost associated with Alloderm represents a significant drawback to its use for this procedure. A single 4 cm × 16 cm sheet of Alloderm has a retail cost of roughly \$1900. As a result, in an average bilateral case, the additional cost of surgery for the patient is \$3800 in excess of standard operative fees. For the patient in whom revision with Alloderm is warranted, this additional cost may be prohibitive, especially in light of the fact that these patients have already spent a considerable sum of money on their primary and subsequent surgeries. Nevertheless, we feel that these costs are worthwhile, given that the risk of revision was so high in our study of patients treated with conventional techniques and that the cost and inconvenience of revision surgery is most certainly greater than the additional cost of Alloderm.

There are perhaps other, less costly, prosthetic materials that could be used as a subpectoral sling. However, we have found that, in comparison to Alloderm, other dermal matrix products do not have the same elastic properties that provide the ideal “stretch” necessary to achieve a natural appearing lower pole of the breast. Other nondonor materials, such as prolene mesh and polytetrafluoroethylene (PTFE,) have not been used by the authors of this study and are not advocated because there are not enough data available to support the safe use of these materials in the breast.

## CONCLUSIONS

Pocket conversion using Alloderm to convert subglandular breast implants to the dual-plane position is safe, reliable, and effective. While the high cost of Alloderm may represent a drawback to use of this procedure, in our view, the higher risk of revision using other techniques and the expense and inconvenience of revision surgery render the described procedure worthwhile. There are as yet insufficient data to determine whether alternative nondonor materials can safely be used in the breast. ▀

## DISCLOSURES

*Drs. Mofid and Singh have in the past served as paid consultants to Lifecell, Inc. Dr. Mofid received discounted Alloderm for use in this study.*

## REFERENCES

1. Parikh PM, Spear SL, Menon N, Reisin E. Immediate breast reconstruction with tissue expanders and Alloderm. *Plast Reconstr Surg* 2006;118(suppl):18.
2. Hochberg J, Margulies A, Yuen JC, Kepple J, Tillman RH, Dorroh S, et al. Alloderm (acellular human dermis) in breast reconstruction with tissue expansion. *Plast Reconstr Surg* 2005;116(suppl 3):126–128.
3. Zienowicz R, Karacaoglu E. Implant-based breast reconstruction with allograft. *Plast Reconstr Surg* 2007;120:373–381.
4. Duncan D. Correction of implant rippling using Allograft dermis. *Aesthetic Surg J* 2001;21:81–84.
5. Baxter R. Intracapsular allogenic dermal grafts for breast implant-related problems. *Plast Reconstr Surg* 2003;112:1692–1696.
6. Spear SL, Carter ME, Ganz JC. The correction of capsular contracture by conversion to “dual-plane” positioning: technique and outcomes. *Plast Reconstr Surg* 2006;118(suppl 7):103S–113S.
7. Chasan PE. Breast capsulorrhaphy revisited: a simple technique for complex problems. *Plast Reconstr Surg* 2005;115:296–301.

Accepted for publication September 10, 2008.

Reprint requests: M. Mark Mofid, MD, 4150 Regents Park Row, Suite #300, La Jolla, CA 92037. E-mail: [drmofid@mofidplasticsurgery.com](mailto:drmofid@mofidplasticsurgery.com).

Copyright © 2009 by The American Society for Aesthetic Plastic Surgery, Inc.

1090-820X/\$36.00

doi:10.1016/j.asj.2008.12.005