

## Long-segment substernal jejunal esophageal replacement with internal mammary vascular augmentation

R. F. Heitmiller, P. J. Gruber, P. Swier, N. Singh

*Department of Surgery, The Johns Hopkins Medical Institutions, Baltimore, MD, USA*

---

**SUMMARY.** We describe a technique that uses the internal mammary vessels to enhance long-segment jejunal graft blood supply in addition to an intact distal mesenteric vascular arcade. We believe that this technique, called vascular augmentation, improves jejunal graft perfusion and decreases ischemic complications.

---

### INTRODUCTION

Because of technical difficulties in the mobilization of long-segment grafts and concern regarding ischemic complications, many esophageal surgeons reserve the jejunum for short-segment or distal esophageal replacement. We describe a technique that uses the internal mammary vessels to enhance long-segment jejunal graft blood supply in addition to an intact distal mesenteric vascular arcade. We believe that this technique, called vascular augmentation, improves jejunal graft perfusion and decreases ischemic complications. The details of this approach are presented.

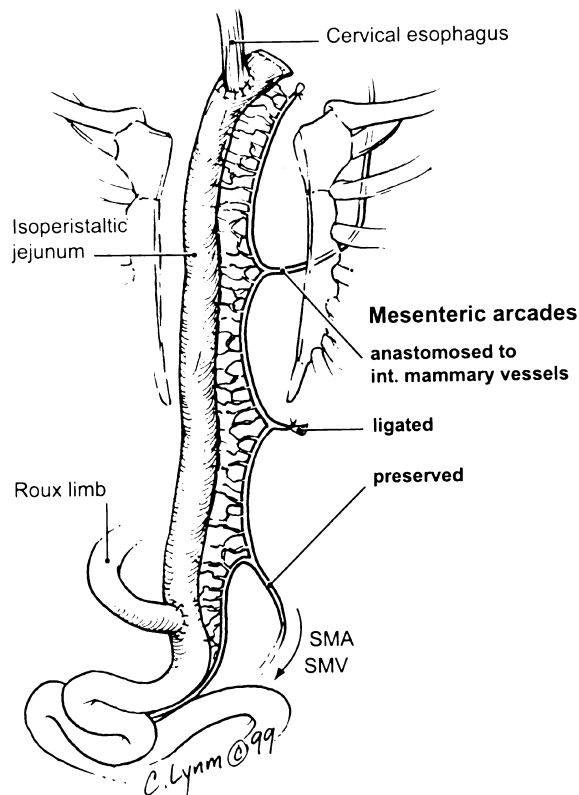
### CASE REPORT

The patient is a 66-year-old man with a distal esophageal adenocarcinoma who underwent preoperative chemotherapy (5-fluorouracil, cis-platinum) and radiotherapy (4500 cGy) followed by trans-hiatal esophagectomy. The post-operative course was uncomplicated and the pathological stage was T3N1M0. In follow-up, the patient underwent a series of esophageal dilatations for a tight cervical anastomotic stricture that resulted in a large tracheo-esophageal fistula (TEF) at the level of the proximal trachea. No evidence of recurrent cancer was identified. Using a left cervicomediastinal incision, the TEF was divided and the airway repaired. The esophago-gastric anastomosis was occluded with fibrous tissue.

The stomach appeared healthy; however, the esophagus and stomach could not be mobilized to permit end-to-end anastomosis. The proximal esophagus was turned out as a cervical ostomy. Enteral feedings were instituted via a jejunostomy tube. Long-segment colon interposition reconstruction was considered; however, a preoperative mesenteric angiogram demonstrated a completely occluded inferior mesenteric artery and a stenosis of the celiac artery at its origin. It was elected to try esophageal reconstruction using either a free jejunal graft between the proximal esophagus and stomach or long-segment jejunum. At laparotomy, the jejunum was mobile, without adhesions and with large, prominent vascular arcades. A long Roux-en-Y limb of jejunum was selected based on three mesenteric vascular arcades. The proximal two were divided to achieve sufficient length to permit passage of the bowel to the neck. A median sternotomy was performed and the left internal mammary vessels were mobilized, as for coronary revascularization. The isoperistaltic jejunum was passed through the anterior mediastinum into the neck. The internal mammary artery and vein were anastomosed to the respective mesenteric vessels of the proximal mesenteric arcade using 9–0 nylon and microvascular techniques. Then, a cervical end-to-end esophagojejunal anastomosis was fashioned and the Roux loop completed in the abdomen. The completed reconstruction is illustrated in Fig. 1. The post-operative course was uncomplicated. No anastomotic leak or stricture was identified. The patient was discharged on oral and enteral feedings. He is now eating regular food and weaning from enteral tube feedings with the expectation of jejunostomy tube removal.

---

Address correspondence to: Dr R. F. Heitmiller, Osler 624, Johns Hopkins Hospital, Baltimore, MD 21136, USA. Fax: (+1) 410 614 9428.



**Fig. 1** An overview of the operative technique is illustrated. A median sternotomy and midline laparotomy incision have been employed. A long-segment, isoperistaltic, Roux-en-Y jejunal graft is passed through the anterior mediastinum and anastomosed to the cervical esophagus. The jejunal graft has a dual blood supply, one native (the preserved distal mesenteric vessels) and the other from the left internal mammary vessels that are anastomosed to the proximal mesenteric vessels. SMA, superior mesenteric artery; SMV, superior mesenteric vein.

## COMMENT

The use of the jejunum as an esophageal replacement conduit is well-established. Roux<sup>1</sup> described its use for esophageal replacement in 1907. Since then, multiple jejunal reconstructive techniques have been described including free grafts, pedicled interposition segments, intact loops or Roux-en-Y limbs. Proponents of using the jejunum for esophageal replacement cite its availability, equivalent esophageal diameter, peristalsis and the lack of a need for preoperative bowel preparation. Critics cite technical difficulties in mobilization and the jejunal mesenteric vascular anatomy, which limits the length of small bowel that can be mobilized without risking ischemic complications. Despite the fact that Rienhoff<sup>2</sup> described long-segment esophageal replacement using jejunum in 1942, subsequent reports using similar techniques are very limited.<sup>3</sup> Because of the concern regarding ischemic complications, many esophageal surgeons use jejunal grafts only for short-segment or distal esophageal replacement.<sup>4-9</sup> If total or near-total esophageal replacement is indicated, then the stomach or colon are preferred because the blood

supply of these conduits is sufficient for safe, long-segment esophageal replacement. There are patients, however (as with our patient), who, because of previous surgery, radiation, age, associated bowel disease, or atherosclerotic vascular disease, do not have either the stomach or colon available for esophageal reconstructive use. For these patients, long-segment jejunal interposition may be the best remaining reconstructive alternative.

The technique of vascular grafting to a segment of bowel that has been mobilized for esophageal replacement, in addition to its mesenteric blood supply, is termed vascular augmentation. A donor graft that is mobilized with a dual blood supply, one native and the other surgically created, is often referred to as “supercharged” because of its enhanced perfusion. Although supporting data are lacking, we feel that the technique of vascular augmentation improves long-segment jejunal graft perfusion and decreases ischemic complications that have historically been associated with these grafts.

Technical guidelines for using this technique include the following. The operative field should be widely prepared to include the neck, anterior chest and abdomen. Explore the abdomen and select an appropriate length of jejunum. The jejunal segment should not include the first vascular arcade distal to the ligament of Trietz as this will limit mobility and jeopardize vascularity to the distal duodenum. Determine which vascular arcades will supply the graft. The distal most arcade will be left *in situ*. Do not divide the proximal arcade(s) at this time. Open the anterior mediastinum using a median sternotomy incision. The patient does not need to be repositioned for this second incision. This technique results in substernal esophageal replacement. We do not feel that this compromises esophageal reconstructive function. In many cases involving complex esophageal reconstruction, the substernal approach is preferentially selected, as the posterior mediastinum has been obliterated by previous surgery. In addition, an open surgical approach prevents traction injury to the bowel or its blood supply when the graft is pulled through the closed substernal space. The proximal esophagus is prepared for anastomosis using a cervical incision. The left internal mammary artery and vein are mobilized as a single pedicle in a fashion identical to the preparation for coronary revascularization (the pedicle will be based superiorly). Ligate the proximal mesenteric vascular arcades to the jejunal graft, leaving the distal arcade intact. Pass the isoperistaltic graft to the neck through the anterior mediastinum. Perform sequential arteriovenous anastomosis between the internal mammary vessels and the corresponding vessels of the proximal mesenteric arcades. In this patient, we used microvascular anastomotic techniques for the vascular anastomoses. However, it may be possible to perform

the vascular anastomosis using standard loupe magnification. Complete the bowel reconstruction using proximal esophageal anastomosis and distal completion of the Roux-en-Y limb. An overview of the completed reconstruction is illustrated in Fig. 1.

Cusick et al<sup>3</sup> reported their results with five pediatric patients in which jejunal interposition was employed for long-gap esophageal atresia. In four patients, the long-segment jejunal graft was supported by an intact distal mesenteric arcade, as well as a vascular graft to the superior thyroid artery and internal jugular vein. In the remaining patient, a free jejunal graft was used based on the internal mammary artery and the external jugular vein. The advantages of using the internal mammary vessels for vascular augmentation (as we describe) include their availability, single-pedicle arteriovenous blood supply, ease of harvesting and mobility of the vascular pedicle, which allows the augmenting blood supply to be brought to the jejunal graft. If needed, multiple site revascularization using both the left and right internal mammary pedicles would be possible. The technique could also be applied to interposed colon grafts.

The technique of long-segment substernal jejunal esophageal replacement with internal mammary vascular augmentation should be considered as a recon-

structive option, especially in patients in which the stomach or colon are not readily available for use.

## References

1. Roux C. L'oesophago-jejuno-gastrostomose, nouvelle operation pour rerecissement infranchissable de l'oesophage. *Semin Med* 1907; 27: 37–40.
2. Reinhoff W F. Intrathoracic esophagojejunostomy for lesions of the upper third of the esophagus. *South Med J* 1946; 39: 928–940.
3. Cusick E L, Batchelor A A G, Spicer R D. Development of a technique for jejunal interposition in long-gap esophageal atresia. *J Ped Surg* 1993; 28: 990–994.
4. Wright C, Cuschieri A. Jejunal interposition for benign esophageal disease. *Ann Surg* 1987; 205: 54–60.
5. Polk H C. Jejunal interposition for reflux esophagitis and esophageal stricture unresponsive to valvuloplasty. *World J Surg* 1980; 4: 731–736.
6. Gaissert H A, Mathisen D J, Grillo H C et al. Short-segment intestinal interposition of the distal esophagus. *J Thorac Cardiovasc Surg* 1993; 106: 860–866.
7. Picchio M, Lombardi A, Zolovkins A et al. Jejunal interposition for peptic stenosis of the esophagus following esophagomyotomy for achalasia. *Int Surg* 1997; 82: 198–200.
8. Mansour K A, Bryan F C, Carlson G W. Bowel interposition for esophageal replacement: twenty-five-year experience. *Ann Thorac Surg* 1997; 64: 752–756.
9. Cooper W A, Miller Jr J I. Jejunal interposition for esophageal replacement. *Operative Techniques Thoracic Cardiovascular Surgery* 1999; 4: 239–251.