

Does Fascia Lata Repair Facilitate Closure and Does It Affect Compartment Pressures of the Anterolateral Thigh Flap Donor Site?

Eduardo D. Rodriguez, M.D.,
D.D.S.

Rachel Bluebond-Langner,
M.D.

Julie Park, M.D.

Xiaojun You, B.S.

Gedge Rosson, M.D.

Navin Singh, M.D.

Baltimore, Md.

The reliability and versatility of the anterolateral thigh flap has been established; however, reducing donor-site morbidity continues to be a focus. The major donor-site difficulties reported include wound complications related to primary closure (i.e., wound dehiscence, muscle bulge, need for skin grafting) and mild lower extremity weakness.¹⁻³ Techniques to further decrease donor-site morbidity would further enhance appeal of the anterolateral thigh flap.

Primary fascial closure or imbrication may decrease tension on the skin repair and allow primary closure of larger defects; however, its effect on compartment pressures has not yet been documented. We sought to demonstrate that primary closure or imbrication of the fascia lata following anterolateral thigh flap harvest could be performed safely and predictably, achieving higher rates of primary skin closure.

PATIENTS AND METHODS

We conducted an institutional review board-approved retrospective review of 86 patients who underwent 88 anterolateral thigh flap harvests to reconstruct lower extremity ($n = 65$), head and neck ($n = 15$), upper extremity ($n = 4$), chest and abdomen ($n = 3$), and penis ($n = 1$) defects between September of 2003 and March of 2006. In

an attempt to achieve higher primary skin closure rates, the fascia was closed or imbricated in 64 of 88 cases. Fascial imbrication or closure began in December of 2003 and was attempted in all subsequent patients. Closure or imbrication was aborted if the fascia began to tear or distal perfusion was compromised.

To evaluate safety, compartment pressures were measured in 50 consecutive patients beginning in April of 2003. Data collected included age, sex, mechanism of injury, body mass index, size of fascia lata removed, type of donor-site closure, compartment pressures, flap survival, and donor-site complications.

All flaps were harvested by a single surgeon (E.D.R.), based on the technique described by Song et al.,⁴ and followed the suprafascial flap dissection described by Wei et al.⁵ When possible, the fascia lata was closed or imbricated and the skin closed primarily. If the donor site was too large to close primarily, a meshed split-thickness skin graft was used (Fig. 1). Approximately 2 cm of fascia is imbricated when fascia is not taken, reducing the width of the wound and the volume of the thigh. We have found that it is not possible to close the fascia if more than 5 cm has been taken with the flap.

Compartment pressures were measured by inserting the Stryker needle (Stryker Corp., Kalamazoo, Mich.) parallel to the floor along three equidistant points of the lateral thigh. Measurements were taken preoperatively, immediately postoperatively, and 48 hours postoperatively. Pain, pulses, and flap viability were monitored every hour for 36 hours.

STATA software (STATA Corp., College Station, Texas) was used for all statistical analysis. The

From the R Adams Cowley Shock Trauma Center, University of Maryland School of Medicine, and the Johns Hopkins Schools of Medicine and Public Health.

Received for publication September 4, 2006; accepted November 7, 2006.

Copyright ©2007 by the American Society of Plastic Surgeons

DOI: 10.1097/01.prs.0000279347.40506.c6

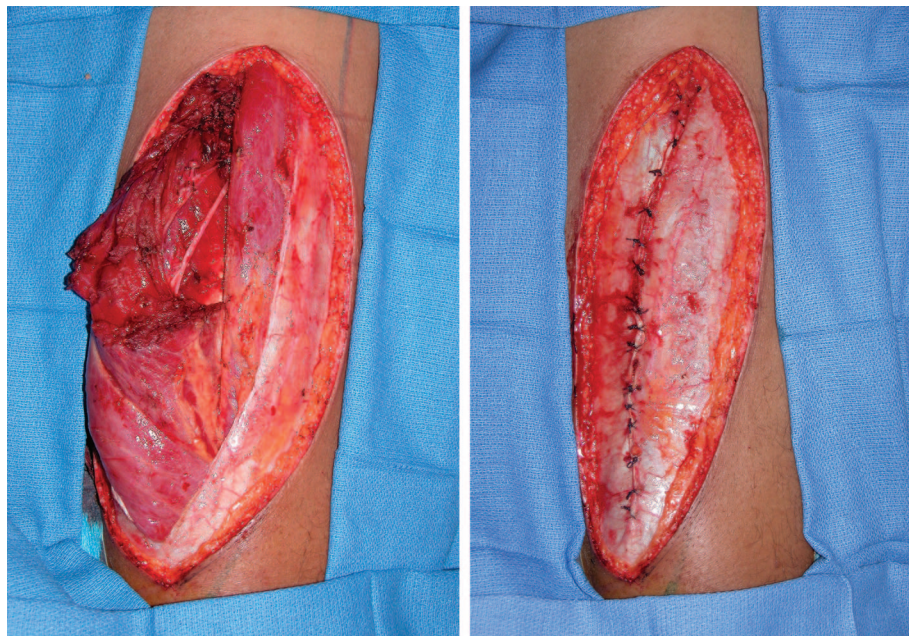


Fig. 1. (Left) Muscle bulge following fascia lata incision and (right) imbrication of fascia lata.

t test, Fischer’s exact test, and logistic regression were used to analyze the relationship of flap size, body mass index, age, sex, fascia harvested, fascial closure or imbrication, rate of donor-site closure, and rise in compartment pressure. Patients were stratified into two groups (flap width less than 8 cm and flap width greater than 8 cm; this cutoff is based on data from Lipa et al.,² in which 8 cm was the maximal width for predictable primary skin closure) to analyze the effect of fascial imbrication or primary fascial closure on the ability to close the skin primarily. All values of *p* < 0.05 were considered statistically significant.

RESULTS

Eighty flaps were for trauma reconstruction, six were for oncologic reconstruction, and two were for soft-tissue reconstruction following necrotizing fasciitis. There were 18 female patients and 70 male patients, with an average age of 38.8 years (range, 14 to 90 years) and average body mass index of 27 kg/m² [underweight, 18.5 (*n* = 4); normal, 18.5 to 24.9 (*n* = 32); overweight, 25 to 29.9 (*n* = 25); obese, >30 (*n* = 25)]. Eighty-three of the 88 free tissue transfers (93.9 percent) were successful. None of the failures was related to ipsilateral flap harvest. The five failed free flaps were replaced with an anterolateral thigh flap from the contralateral leg. There were no patients with evidence of compartment syndrome as measured by clinical symptoms (uncontrolled thigh pain, pain with passive stretch, significant swelling, motor or

sensory deficits) or Stryker needle measurements. One patient’s fascial closure was released on the table after the loss of distal perfusion. Pulses returned following fascial release and the flap survived. In this patient, the donor site measured 30 × 10 cm and was subsequently skin grafted.

The average flap size measured 20.9 × 8.53 cm (range, 35 × 15 cm to 6 × 6 cm). An average of 4.1 cm of fascia lata (range, 0 to 15 cm) was included in 35 flaps. The fascia was closed (if fascia was taken) or imbricated in 64 patients, the skin was closed primarily in 76 patients, and 12 patients required split-thickness skin grafts. The average flap size in those patients requiring skin grafts measured 24.3 × 11.3 cm. In patients with flap

Table 1. Characteristics of Donor-Site Skin Closure Rates Using Two-Sample *t* Test and Two-Sample Proportion Test*

	Split-Thickness Skin Graft (<i>n</i> = 12)	Primary Skin Closure (<i>n</i> = 76)	<i>p</i>
Flap area, cm ²	24.3 ± 6.5*	20.3 ± 6.3*	0.05*
Flap width, cm	11.3 ± 3.1*	9.0 ± 2.0*	0.00*
Body mass index, kg/m ²	27.3 ± 3.6	27.0 ± 6.1	0.88
Age, years	40.1 ± 7.8	38.6 ± 16.0	0.75
Fascia taken, cm	2.3 ± 3.4	2.6 ± 3.1	0.76
Fascial closure/imbrication	42%* (<i>n</i> = 5)	78%* (<i>n</i> = 60)	0.02*
Sex	75% (male, 9)	82% (male, 62)	0.70

*Flap area, flap width, and fascial closure/imbrication are statistically significant.

Table 2. Logistic Regression of Primary Skin Closure Controlling for Fascial Closure, Body Mass Index, Age, and Sex, Stratified by Flap Width*

	Flap Width <8 cm			Flap Width >8 cm		
	Donor Site Closed Primarily	OR	<i>p</i>	Donor Site Closed Primarily	OR	<i>p</i>
Fascia not closed/imbricated	93.3%	1.0 (ref)	0.28	40%	1.0 (ref)	0.04
Fascia closed/imbricated	97.5%	6.03		83%	9.33	

OR, odds ratio; ref, reference.

*Only fascial imbrication in flaps >8 cm affected the ability to close the skin primarily. The interaction term between flap width and fascial closure/imbrication is not significant ($p = 0.66$).

width greater than 8 cm, closure or imbrication of the fascia made primary skin closure nine times more likely ($p = 0.035$, logistic regression). Flap area, age, sex, and body mass index did not affect primary skin closure ($p > 0.05$, logistic regression) (Tables 1 and 2).

The average compartment pressures were 6.67 mmHg preoperatively, 19.29 mmHg immediately postoperatively, and 14.36 mmHg 48 hours postoperatively. The curve of the change in pressure over the 48 hours was the same in patients with flaps less than 8 cm and flaps greater than 8 cm (Fig. 2). Forty-one of the 65 patients undergoing lower extremity reconstruction had ipsilateral anterolateral thigh flap harvest. The compartment pressures were not higher in the ipsilateral donor site (17.5 versus 19.8 mmHg; $p = 0.31$, *t* test) and flap survival was not affected ($p = 0.6$, *t* test).

The average follow-up time was 24.8 months (range, 5 to 49 months). None of the patients with imbrication or primary fascial closure developed seroma, wound infection, muscle herniation, or

wound dehiscence at the donor site. Muscle bulge was seen in seven patients whose donor site was covered with a split-thickness skin graft and whose fascia was not closed or imbricated (Fig. 3). All patients complained of lateral thigh numbness, but it was not a long-term complaint.

DISCUSSION

Primary closure rates of anterolateral thigh donor sites range from 6 to 9 cm wide.³⁻⁵ Lipa and Novak recently reported donor-site closure measuring up to 10 cm but with increased donor-site complications, including wound dehiscence, muscle bulge, and need for skin grafting.² In our series, larger donor sites were closed (average, 9 cm; range, 5 to 13 cm) without donor-site complications (wound dehiscence and muscle herniation). Our technique is particularly useful in donor sites larger than 8 cm, making primary skin closure nine times more likely (Table 2). Although lateral compartment pressures increase significantly following primary fascial closure or imbrication, it

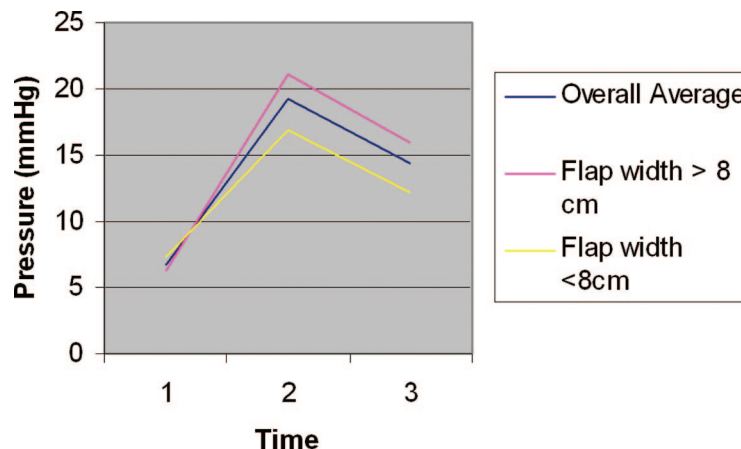


Fig. 2. Graph of compartment pressures. The three lines represent the overall average, the average for flaps wider than 8 cm, and the average for flaps narrower than 8 cm. The trend in pressures is the same in patients with both small and large flaps.

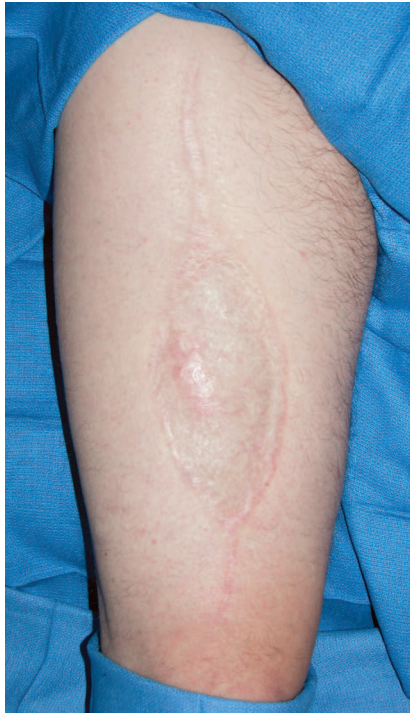

Fig. 3. Muscle bulge following approximation but not closure of the fascia lata and application of a split-thickness skin graft to the anterolateral thigh donor site.

may be performed safely without adverse clinical sequelae or increased morbidity, as defined by risk of compartment syndrome or flap failure following ipsilateral flap harvest.

Thigh compartment syndrome is well documented in the orthopedic literature⁶⁻¹⁵ but has not been documented following anterolateral thigh flap harvest. However, the potential exists either from vastus lateralis muscle swelling following dissection or from volume reduction of the compartment following fascial repair. Compartment syndrome develops when the pressure in the muscle compartment exceeds the capillary pressure, resulting in microvascular collapse, muscle necrosis, and nerve ischemia.¹⁶⁻¹⁸ Our study suggests that compartment pressures do rise but compartment syndrome does not develop.

CONCLUSIONS

Fascia lata closure or imbrication following anterolateral thigh flap harvest is safe and reduces donor-site morbidity by allowing primary skin closure of larger defects, decreasing muscle herniation and wound dehiscence. To further minimize donor-site morbidity, the thigh of the

injured leg can be used safely, with predictable results.

Eduardo D. Rodriguez, M.D., D.D.S.

Plastic, Reconstructive, and Maxillofacial Surgery
R Adams Cowley Shock Trauma Center
22 South Greene Street
Baltimore, Md. 21201
erodriguez@umm.edu

DISCLOSURE

None of the authors has a financial interest in any of the products mentioned in the article or used in the study.

REFERENCES

1. Kimata, Y., Uchiyama, K., Ebihara, S., et al. Anterolateral thigh flap donor-site complications and morbidity. *Plast. Reconstr. Surg.* 106: 584, 2000.
2. Lipa, J. E., Novak, C. B., and Binhammer, P. A. Patient-reported donor-site morbidity following anterolateral thigh free flaps. *J. Reconstr. Microsurg.* 21: 365, 2005.
3. Kuo, Y. R., Jeng, S. F., Kuo, M. H., et al. Free anterolateral thigh flap for extremity reconstruction: Clinical experience and functional assessment of donor site. *Plast. Reconstr. Surg.* 107: 1766, 2001.
4. Song, Y. G., Chen, G. Z., and Song, Y. L. The free thigh flap: A new free flap concept based on the septocutaneous artery. *Br. J. Plast. Surg.* 37: 149, 1984.
5. Wei, F., Jain, C. V., Celik, N., Chen, H. C., Chuang, D. C., and Lin, C. H. Have we found an ideal soft-tissue flap? An experience with 672 anterolateral thigh flaps. *Plast. Reconstr. Surg.* 109: 2219, 2002.
6. Mubarak, S. J., Owen, C. A., Hargens, A. R., Garetto, L. P., and Akeson, W. H. Acute compartment syndromes: Diagnosis and treatment with the aid of the wick catheter. *J. Bone Joint Surg. (Am.)* 60: 1091, 1978.
7. Whitesides, T. E., and Heckman, M. M. Acute compartment syndrome: Update on diagnosis and treatment. *J. Am. Acad. Orthop. Surg.* 4: 209, 1996.
8. Matsen, F. A., III, Winquist, R. A., and Krugmire, R. B. Diagnosis and management of compartmental syndromes. *J. Bone Joint Surg. (Am.)* 62: 286, 1980.
9. Schwartz, J. T., Jr., Brumback, R. J., Lakatos, R., Poka, A., Bathon, G. H., and Burgess, A. R. Acute compartment syndrome of the thigh: A spectrum of injury. *J. Bone Joint Surg. (Am.)* 71: 392, 1989.
10. Mithofer, K., Lhowe, D. W., Vrahas, M. S., Altman, D. T., and Altman, G. T. Clinical spectrum of acute compartment syndrome of the thigh and its relation to associated injuries. *Clin. Orthop. Relat. Res.* 425: 223, 2004.
11. Tarlow, S. D., Achterman, C. A., Hayhurst, J., and Ovadia, D. N. Acute compartment syndrome in the thigh complicating fracture of the femur: A report of three cases. *J. Bone Joint Surg. (Am.)* 68: 1439, 1986.
12. Best, I. M., and Bumpers, H. L. Thigh compartment syndrome after acute ischemia. *Am. Surg.* 68: 996, 2002.
13. Suzuki, T., Moirmura, N., Kawai, K., and Sugiyama, M. Arterial injury associated with acute compartment syndrome of the thigh following blunt trauma. *Injury* 36: 151, 2005.
14. Doube, A. An acute compartment syndrome involving the anterior thighs after isometric exercise. *N. Z. Med. J.* 108: 413, 1995.
15. Bidwell, J. P., Gibbons, C. E., and Godsiff, S. Acute compartment syndrome of the thigh after weight training. *Br. J. Sports Med.* 30: 264, 1996.

16. Rahm, M., and Probe, R. Extensive deep venous thrombosis resulting in compartment syndrome of the thigh and leg: A case report. *J. Bone Joint Surg. (Am.)* 76: 1854, 1994.
17. Nadeem, R. D., Clift, B. A., Martindale, J. P., Hadden, W. A., and Ritchie, I. K. Acute compartment syndrome of the thigh after joint replacement with anticoagulation. *J. Bone Joint Surg. (Br.)* 80: 866, 1998.
18. Brotman, S., Browner, B. D., and Cox, E. F. MAS trousers improperly applied causing a compartment syndrome in lower-extremity trauma. *J. Trauma* 22: 598, 1982.

PRS-Online

Gain access to the full spectrum of plastic and reconstructive surgery. Visit *Plastic and Reconstructive Surgery's* Web site, www.PRSJournal.com today!

Every subscription to the print edition of *PRS* includes full access to the online *Journal*. PRS-Online contains the complete text and figure content of the print *Journal*, and has these additional features:

- Article+ items (short-duration videos and animations)
- Video+ videos (high-resolution streaming videos of operative procedures)
- Podcasts of selected article abstracts—download PRS abstracts and listen on the go
- CME articles and tests—earn up to 14 Category 1 CME credits/year
- CME Contemporary Collections (CME articles grouped by section)
- Advance Online articles (preprint publication of selected clinical and experimental articles)
- Key images from each section, including Image of the Month
- Calendar of future meetings and events
- Links to the ASPS homepage and other sister society links

In order to activate the full content of PRS-Online, you must register. Registration is a quick, one-time process.

To register:

- Go to www.PRSJournal.com.
- Click “Register” on the top menu bar.
- Follow the activation instructions that appear on the screen.
- ASPS members, please have your ASPS member number ready.