

Contour Abnormalities of the Abdomen after Breast Reconstruction with Abdominal Flaps: The Role of Muscle Preservation

Maurice Y. Nahabedian, M.D., William Dooley, M.D., Navin Singh, M.D., and Paul N. Manson, M.D.

Baltimore, Md., and Oklahoma City, Okla.

The purpose of the present study was to determine whether contour abnormalities of the abdomen after breast reconstruction with abdominal flaps are related to the harvest of the rectus abdominis muscle. Abdominal contour was analyzed in 155 women who had breast reconstruction with abdominal flaps; 108 women had free transverse rectus abdominis muscle (TRAM) flaps, 37 had pedicled TRAM flaps, and 10 had deep inferior epigastric perforator (DIEP) flaps. The reconstruction was unilateral in 110 women and bilateral in 45 women. Three methods of muscle-sparing were used; they are classified as preservation of the lateral muscle, preservation of the medial and lateral muscle, or preservation of the entire muscle. One of these three methods of muscle-sparing was used in 91 women (59 percent) and no muscle-sparing was used in 64 women (41 percent). Postoperative contour abnormalities occurred in 15 women and included epigastric fullness in five, upper bulge in three, and lower bulge in 10. One woman experienced two abnormalities, one woman experienced three, and no woman developed a hernia. Of these abnormalities, 11 occurred after the free TRAM flap, seven after the pedicled TRAM flap, and none after the DIEP flap. Bilateral reconstruction resulted in 11 abnormalities in nine women, and unilateral reconstruction resulted in seven abnormalities in six women. χ^2 analysis of the free and pedicled TRAM flaps demonstrates that muscle-sparing explains the observed differences in upper bulge and upper fullness ($p = 0.02$), with a trend toward significance for lower bulge ($p = 0.06$). χ^2 analysis of the free TRAM and DIEP flaps does not explain the observed difference in abnormal abdominal contour. Analysis of muscle-sparing and non-muscle-sparing methods demonstrates that the observed difference between the techniques is only explained for a lower bulge after the bilateral free TRAM flap ($p = 0.04$). (*Plast. Reconstr. Surg.* 109: 91, 2002.)

Contour abnormalities of the abdomen after breast reconstruction with abdominal flaps in-

clude upper fullness, upper bulge, lower bulge, and hernia, with an incidence ranging from 0 to 82 percent¹⁻¹⁵ (Figs. 1 and 2). The cause of these abnormalities is multifactorial, controversial, and may be related to the harvest of the rectus abdominis muscle and anterior rectus sheath.¹⁵ Proposed causes related to the rectus abdominis muscle include total or partial harvest, displacement, denervation, myotomy scar, epigastric tunneling, and atrophy; factors related to the anterior rectus sheath include attenuation, laxity, unequal tension, and dehiscence.^{1-3,7-10,13,15-20} Previous studies have demonstrated that the anterior rectus sheath has the primary role and the rectus abdominis is less involved in the cause and prevention of abnormal abdominal contour.³ However, a detailed analysis of abnormal abdominal contour after abdominal flap breast reconstruction that evaluates the role of muscle preservation has not been performed.

The purpose of the present study was to analyze the role of the rectus abdominis muscle and its relationship to abnormal abdominal contour. Three methods of breast reconstruction were studied, including the pedicled transverse rectus abdominis muscle (TRAM), free TRAM flap, and deep inferior epigastric perforator (DIEP) flap. The choice of flap represents an evolution in technique that has progressed from total muscle harvest to total muscle preservation in an attempt to minimize abdominal wall abnormalities related to strength and contour. A single surgeon's expe-

From the Division of Plastic and Reconstructive Surgery, Johns Hopkins Medical Institutions, and the Department of Surgery, University of Oklahoma. Received for publication January 12, 2001; revised March 26, 2001.

Presented at the Annual Meetings of the American Association of Plastic Surgeons, Charleston, South Carolina, May 13 through 16, 2001, and the European Association of Plastic Surgeons, in Helsinki, Finland, May 31 through June 2, 2001.

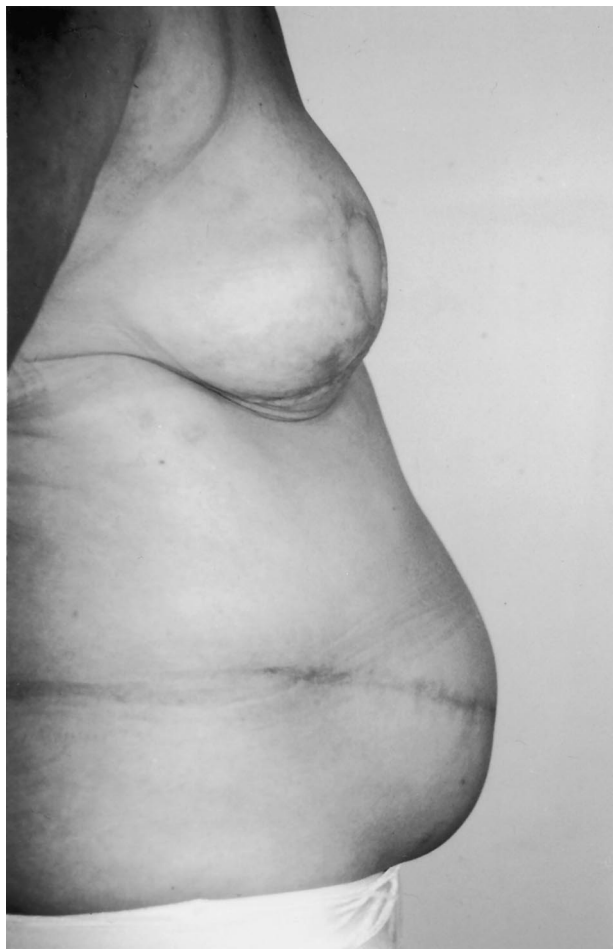

FIG. 1. Lateral view of a lower abdominal bulge after bilateral free TRAM breast reconstruction.

rience is provided to minimize variables related to the technique of flap elevation, the definition of abnormal contour, the amount of rectus abdominis removed, the innervation and vascularity of the remaining muscle segment, and the method of fascial closure.

PATIENTS AND METHODS

Definitions

Abdominal bulge is defined as abdominal wall laxity without an associated fascial defect. Hernia is defined as abdominal wall laxity with an associated fascial defect. Epigastric fullness is due to the tunneling of the pedicled TRAM. Muscle-sparing of the rectus abdominis is defined as preservation of the lateral segment, preservation of the medial and lateral segments, or preservation of the entire muscle. Non-muscle-sparing techniques incorporate the full width and a variable length of muscle.

Study Design

Between July of 1997 and July of 2000, 155 women underwent breast reconstruction using abdominal flaps. Breast reconstruction was unilateral in 110 women (71 percent) and bilateral in 45 women (29 percent); thus, a total of 200 flaps were used. The free TRAM was used in 108 women, pedicled TRAM flap was used in 37 women, and the DIEP flap was used in 10 women. One of the three methods of muscle-sparing was used in 91 women (59 percent), and non-muscle-sparing techniques were used in 64 women (41 percent). Six groups of women were analyzed; these included the unilateral free TRAM ($n = 85$), unilateral pedicled TRAM ($n = 17$), unilateral DIEP flap ($n = 8$), bilateral free TRAM ($n = 23$), bilateral pedicled TRAM ($n = 20$), and bilateral DIEP flap ($n = 2$). The pedicled and free TRAM groups included both muscle-sparing and non-muscle-sparing techniques, but the DIEP flap groups included only muscle-sparing techniques (the entire muscle was preserved in all; Table I). The mean follow-up is 19.8 months (range, 6 to 42 months). Statistical analysis was completed using χ^2 .

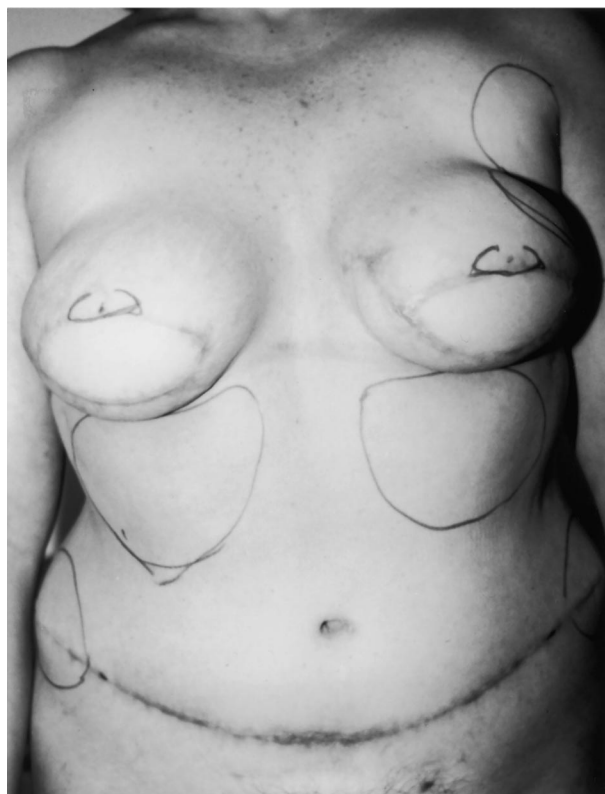


FIG. 2. Anterior view of epigastric fullness after bilateral pedicled TRAM breast reconstruction. The pedicles are tunneled ipsilaterally.

TABLE I
The Six Groups

	No. of Women	Age (y)	Nerve-Sparing (n)	Diabetes Mellitus (n)	Tobacco Use (n)	Mesh Used (n)	Prior Abdominal Surgery (n)	Incisions					Flammensstiel (n)
								Right Lower Quadrant (n)	Right Upper Quadrant (n)	Lower Midline (n)	Upper Midline (n)	Flammensstiel (n)	
Unilateral pedicled TRAM													
MS-0	13	48	0	1	2	0	6	1	1	0	0	4	
MS-1	4	42	3	0	0	0	2	0	0	0	0	2	
Unilateral free TRAM													
MS-0	30	49	0	0	9	0	0	0	0	0	0	0	
MS-1	23	49	20	0	4	0	1	0	1	0	0	0	
MS-2	32	47	27	0	6	0	7	3	1	0	0	3	
Unilateral DIEP													
MS-3	8	55	6	1	0	0	1	0	0	0	0	1	
Bilateral pedicled TRAM													
MS-0	17	51	0	0	4	9	4	2	0	1	0	1	
MS-1	3	45	3	0	1	1	1	0	0	1	0	0	
Bilateral free TRAM													
MS-0	4	53	0	0	1	2	2	0	0	1	1	0	
MS-1	4	51	4	0	1	4	0	0	0	1	0	0	
MS-2	15	43	14	0	2	3	7	0	1	0	1	5	
Bilateral DIEP													
MS-3	2	40	2	0	0	0	0	0	0	0	0	0	
TOTAL	155	48	79	2	30	19	32	6	4	4	2	16	

MS:0, non-muscle-sparing; MS:1, lateral segment preserved; MS:2, medial and lateral segments preserved; MS:3, entire muscle preserved.

The various techniques of muscle preservation and the importance of preserving the intercostal nerves and blood vessels have been described previously.^{1,19,21-26} Schematic illustrations and clinical photographs of the muscle-sparing pedicled TRAM, free TRAM, and DIEP flaps are depicted in Figures 3 through 7. The methods of repairing the anterior rectus sheath after flap elevation have been described previously and depend on the type of abdominal flap and the degree of muscle-sparing.^{3,13}

Associated Factors

Associated factors relevant to the analysis include patient age, tobacco use, diabetes mellitus, prior abdominal surgery, bilateral versus unilateral reconstruction, use of mesh for fascial closure, and preservation of motor innervation (Table I). Mean patient age was 48 years, with a range of 25 to 75 years. A history of tobacco use was documented in 30 women (19.4 percent). Tobacco use was defined by the consumption of more than 10 cigarettes per day. Diabetes mellitus was noted in two women

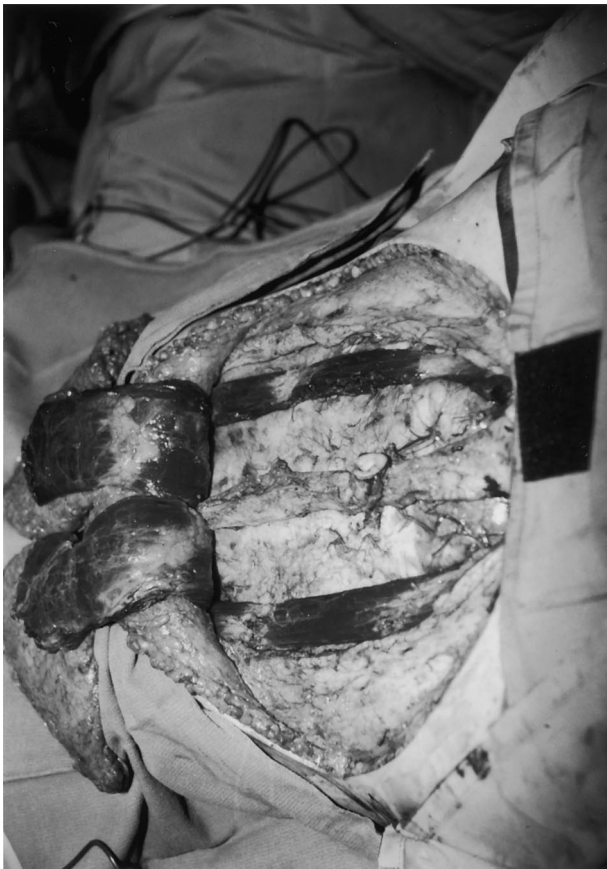

FIG. 3. Intraoperative view of the muscle-sparing, bilateral, pedicled TRAM technique.

Unilateral Free TRAM (Transverse Rectus Abdominis Myocutaneous)

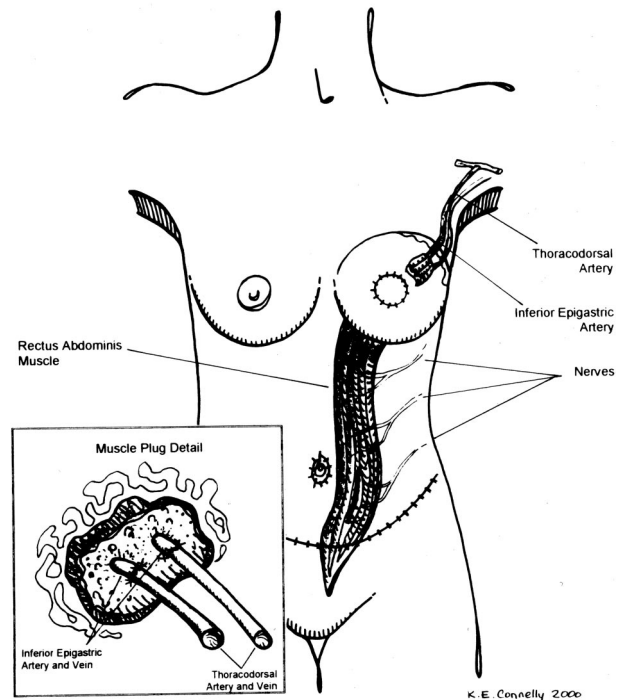


FIG. 4. Schematic illustration of the muscle-sparing, unilateral, free TRAM technique.

(1.3 percent). Prior abdominal operations had been performed in 32 women (20.6 percent) and included a right lower quadrant incision in six women, a right upper quadrant incision in four women, a lower (infraumbilical) midline incision in four women, an upper (supraumbilical) incision in two women, and a Pfannenstiel incision in 16 women. Using Marlex mesh to close the anterior rectus sheath was necessary in 19 women (12 percent). Preserving motor innervation to the rectus abdominis muscle was accomplished in 89 women (57 percent).

RESULTS

Overall Results

A total of 18 contour abnormalities occurred in 15 of 155 women (9.7 percent) after breast reconstruction using abdominal flaps (Table II). The number of contour abnormalities per patient varied and included a single abnormality in 13 women, two abnormalities in one woman, and three abnormalities in one woman. The specific contour abnormalities included upper fullness in five women, upper bulge in three women, and lower bulge in 10

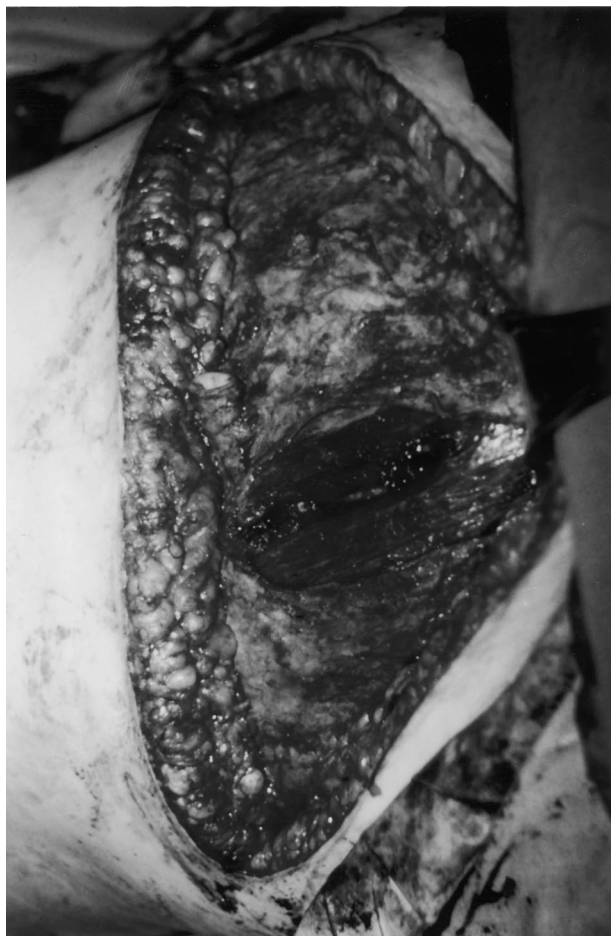

FIG. 5. Intraoperative view of the muscle-sparing, unilateral, free TRAM technique. A small central segment of the rectus abdominis muscle is harvested, thus preserving the lateral and medial segments.

women. No woman developed a hernia. χ^2 analyses are shown in Table III.

Secondary procedures were completed in eight women and included epigastric liposuction in two women and repair of lower abdominal bulge in six women. The bulge was due to laxity and attenuation of the anterior rectus sheath in all cases and was repaired by plication of the anterior sheath in two women and by onlay mesh reinforcement in four women. There have been no recurrent bulges at a minimum of 1 year of follow-up. Secondary procedures were not performed in seven women because the contour abnormality was minor and did not interfere with their activities of daily living.

Associated factor analysis of the 15 women with abnormal abdominal contours demonstrated a mean age of 52.6 years with a range from 45 to 62 years (Table IV). Tobacco use was noted in three women (20 percent), and

diabetes mellitus was a factor in one woman (6.6 percent). Breast reconstruction was unilateral in six women (40 percent) and bilateral in nine women (60 percent). The flap type was a unilateral pedicled TRAM in three women (20 percent), unilateral free TRAM in three women (20 percent), bilateral pedicled TRAM in five women (33 percent), and bilateral free TRAM in four women (27 percent). No woman having a unilateral or bilateral DIEP flap reconstruction developed a contour abnormality. Non-muscle-sparing techniques resulted in an abnormal contour in 10 of 15 women (67 percent), whereas muscle-sparing techniques resulted in an abnormal contour in five women (33 percent). Within the muscle-sparing group were three women in whom the lateral muscle strip was preserved and two women in whom the medial and lateral muscle strip was preserved. Five women had the intercostal innervation to the remaining muscle segment or segments preserved. Prior abdominal operations had been performed in five women with an abnormal contour; four of these women

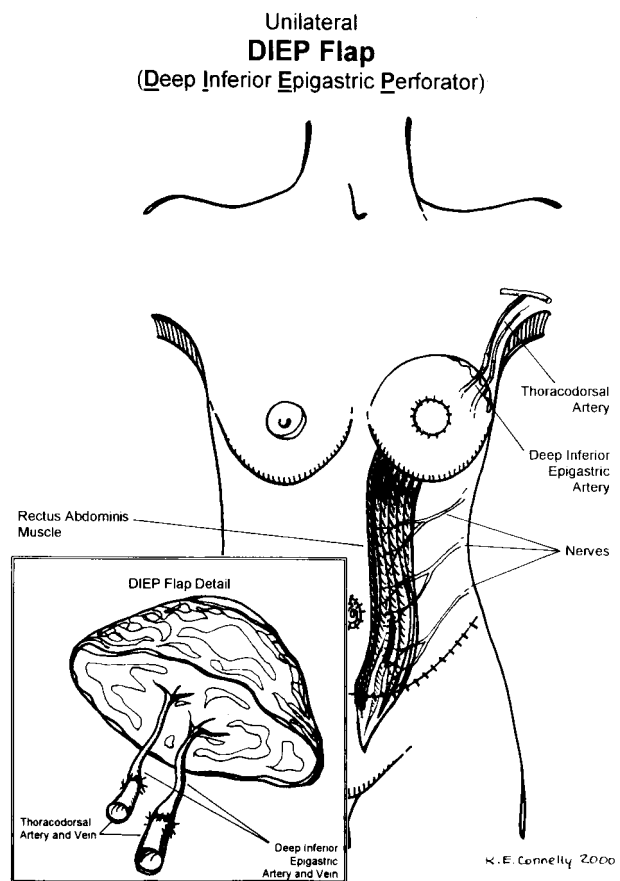


FIG. 6. Schematic illustration of the unilateral DIEP flap. No muscle is harvested.

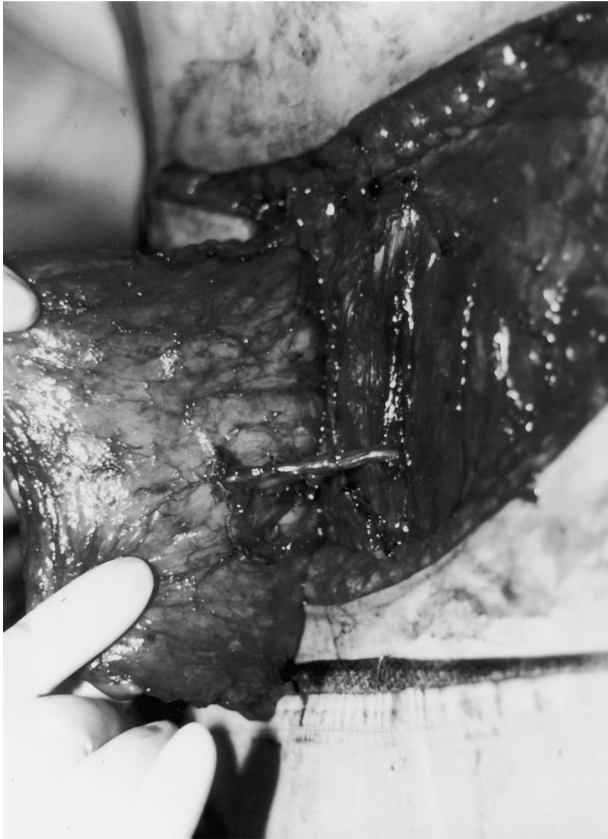

FIG. 7. Intraoperative view demonstrating DIEP flap elevation on a single perforator. No muscle is harvested.

had bilateral reconstruction in the presence of a prior midline incision. Fascial closure was completed without mesh in 12 women (80 percent) and with mesh in three women (20 percent).

Pedicled TRAM Flap

Pedicled TRAM reconstruction was performed in 37 women (24 percent); 17 procedures were unilateral and 20 were bilateral (Table V). A total of 11 contour abnormalities occurred in eight women (22 percent) after pedicled TRAM reconstruction. Reconstruction using the unilateral pedicled TRAM flap included four women who had the lateral muscle preserved and 13 women who had non-muscle-sparing techniques. These women had four contour abnormalities, all of which occurred in those who had non-muscle-sparing techniques; abnormalities included upper fullness in one woman, upper bulge in two women, and lower bulge in one woman. Reconstruction using the bilateral pedicled TRAM flap included three women who had the lateral muscle preserved and 17 women who

had a non-muscle-sparing technique. These women had seven contour abnormalities, six of which occurred in those who had a non-muscle-sparing technique (86 percent); abnormalities included upper fullness in four women, upper bulge in one woman, and lower bulge in two women.

Free TRAM Flap

Free TRAM reconstruction was performed in 108 women (70 percent); 85 procedures were unilateral and 23 were bilateral (Table V). A total of seven contour abnormalities were documented in seven women after free TRAM reconstruction. Reconstruction using the unilateral free TRAM flap included 30 women who had non-muscle-sparing techniques, 23 women who had the lateral muscle preserved, and 32 women who had the medial and lateral muscles preserved. Three contour abnormalities (all lower abdominal bulges) occurred in these women; one woman from each subgroup experienced this complication. Reconstruction using the bilateral free TRAM flap included four women who had non-muscle-sparing techniques, four women who had the lateral muscle preserved, and 15 women who had both the medial and lateral muscle preserved. These women had four contour abnormalities, which were all lower abdominal bulges; they occurred in two women who had a non-muscle-sparing technique, one woman who had the lateral muscle preserved, and one woman who had the medial and lateral muscles preserved.

DIEP Flap

The DIEP flap was performed in 10 women (6.5 percent); eight flaps were unilateral and two were bilateral (Table V). No contour abnormalities were noted in this group. No woman required the use of Marlex mesh, a nerve-sparing technique was used in all women, and only one woman had a previous abdominal Pfannenstiel incision.

DISCUSSION

The strength, support, and normal contour of the anterior abdominal wall are derived from the paired rectus abdominis muscles and the anterior and posterior rectus sheaths. The elevation of an abdominal flap will violate the integrity of these structures and may result in

TABLE II
Abnormal Abdominal Contour in Each Group

	Patients	Upper Fullness	Upper Bulge	Lower Bulge	Hernia	Total
Unilateral pedicled TRAM						
MS-0	13	1	2	1	0	4
MS-1	4	0	0	0	0	0
Unilateral free TRAM						
MS-0	30	0	0	1	0	1
MS-1	23	0	0	1	0	1
MS-2	32	0	0	1	0	1
Unilateral DIEP						
MS-3	8	0	0	0	0	0
Bilateral pedicled TRAM						
MS-0	17	3	1	2	0	6
MS-1	3	1	0	0	0	1
Bilateral free TRAM						
MS-0	4	0	0	2	0	2
MS-1	4	0	0	1	0	1
MS-2	15	0	0	1	0	1
Bilateral DIEP						
MS-3	2	0	0	0	0	0
TOTAL	155	5	3	10	0	18

Abbreviations as in Table I.

an abnormal abdominal contour. Although contour abnormalities have been observed with the pedicled TRAM, free TRAM, and DIEP flaps, the specific role of muscle preservation and its relation to contour abnormalities has not been adequately studied.

The role of the rectus abdominis muscle within the abdominal flap is to protect the inferior and superior epigastric vascular systems. It does not contribute to the volume, shape, or contour of the reconstructed breast. The transplanted muscle is denervated, atrophies, and serves no function. Muscle-based abdominal flaps also incorporate a portion of

the anterior rectus sheath. Loss of this fascia can further compromise the supportive function of the anterior abdominal wall. Using abdominal flaps that minimize the amount of rectus abdominis muscle and anterior rectus sheath harvested may result in improved abdominal strength, support, and contour. However, the preserved muscle must retain the elements necessary for proper function, namely, vascularity and innervation.

The innervation and blood supply to the remaining segment(s) of the rectus abdominis muscle are derived from the laterally based intercostal nerves and vasculature. The importance of preserving this vascularity and innervation was first emphasized by Hartrampf in 1984.¹ Subsequent anatomic studies have further defined the neural architecture within the rectus abdominis muscle.^{17,25,26} The intercostal nerves may enter the muscle in the lateral or central segment. Noninnervated segments lack the ability to contract on stimulation and ultimately atrophy; innervated muscle segments will contract on stimulation and maintain muscle width and volume.

The importance of the anterior rectus sheath has been described previously.^{13,15} It has been reported that the incidence of abdominal bulge or hernia depends primarily on the method of fascial closure rather than the amount of muscle removed.³ Techniques to close the anterior rectus sheath vary widely among surgeons and may include one layer, two layers, or the use of mesh.^{1,3-5,7,13,20,27,28} Kroll

TABLE III
 χ^2 Analysis

	Upper Fullness	Upper Bulge	Lower Bulge
Pedicled vs free TRAM			
Across the board	0*	0.02*	0.06
Unilateral	0.02*	0.001*	0.59
Bilateral	0.02*	0.02*	0.11
Free TRAM vs DIEP			
Across the board	NA	NA	0.41
Unilateral	NA	NA	0.59
Bilateral	NA	NA	0.54
Muscle-sparing			
Across the board	0.07	0.04*	0.22
Unilateral	0.21	0.08	0.65
Bilateral	0.24	0.29	0.3
Pedicled	0.95	0.4	0.4
Free	NA	NA	0.4
Unilateral pedicle	0.6	0.44	0.6
Unilateral free	NA	NA	0.97
Bilateral pedicle	0.56	0.69	0.56
Bilateral free	NA	NA	0.04*

* Significant difference.

TABLE IV
All Women with Abnormal Abdominal Contours

Patient	Age (yrs)	Flap	Muscle-Sparing	Nerve-Sparing	Diabetes Mellitus	Tobacco Use	Prior Incisions	Mesh	Upper Fullness	Upper Laxity	Lower Laxity	Hernia
1	45	UPT	MS-0	No	Yes	No	RUQ	No	No	No	Yes	No
2	58	UPT	MS-0	No	No	No	None	No	No	Yes	No	No
3	51	UPT	MS-0	No	No	No	None	No	Yes	Yes	No	No
4	49	UFT	MS-0	No	No	No	None	No	No	No	Yes	No
5	48	UFT	MS-1	Yes	No	No	None	No	No	No	Yes	No
6	62	UFT	MS-2	Yes	No	No	None	No	No	No	Yes	No
7	45	BPT	MS-0	No	No	Yes	None	Yes	Yes	No	No	No
8	54	BPT	MS-0	No	No	Yes	None	Yes	Yes	No	No	No
9	46	BPT	MS-0	No	No	No	LM	Yes	No	No	Yes	No
10	59	BPT	MS-0	No	No	No	None	No	Yes	Yes	Yes	No
11	52	BPT	MS-1	Yes	No	No	LM	No	Yes	No	No	No
12	58	BFT	MS-0	No	No	No	None	Yes	No	No	Yes	No
13	59	BFT	MS-0	No	No	No	UM	No	No	No	Yes	No
14	54	BFT	MS-1	Yes	No	Yes	LM	No	No	No	Yes	No
15	50	BFT	MS-2	Yes	No	No	None	No	No	No	Yes	No

U, unilateral; B, bilateral; P, pedicled; F, free; T, TRAM; RUQ, right upper quadrant; LM, lower midline; UL, upper midline; other abbreviations as in Table I.

et al.^{3,7} recommend a two-layer fascial closure incorporating the superficial medial and lateral edges of the external oblique fascia and the deeper internal oblique fascia laterally and the midline fascia deep to the linea alba medially. Using this technique, the bulge rate is reduced from 30 percent to 5 percent. Synthetic materials, including Gore-Tex, prolene, and Marlex mesh (as a patch and/or onlay graft to reinforce the abdominal wall after free and pedicled TRAM flaps), are used routinely by some surgeons.^{26,29-31} These materials can be used in an interposition fashion or as onlay grafts.² Hernia and bulge rates

are reported to be less than 5 percent in these studies.

In an attempt to reduce the incidence of abdominal morbidity, muscle-sparing techniques such as the free TRAM and DIEP flaps have been introduced.^{11,12,21,22,32-34} However, most studies have demonstrated no significant difference when these techniques are compared with the pedicled TRAM; however, many of these studies are limited by their small sample size (Table VI). Comparative studies between the pedicled and free TRAM flaps analyzing the incidence of bulge or hernia have demonstrated mixed results.^{7,8,10,15} Compara-

TABLE V
Women with Abnormal Abdominal Contour after Each Type of Reconstruction

Type	Total Patients	Upper Fullness	Upper Bulge	Lower Bulge	Hernia	Total
Pedicled TRAM						
Unilateral						
MS-0	13	1	2	1	0	4
MS-1	4	0	0	0	0	0
Bilateral						
MS-0	17	3	1	2	0	6
MS-1	3	1	0	0	0	1
TOTAL	37	5	3	3	0	11
Free TRAM						
Unilateral						
MS-0	30	0	0	1	0	1
MS-1	23	0	0	1	0	1
MS-2	32	0	0	1	0	1
Bilateral						
MS-0	4	0	0	2	0	2
MS-1	4	0	0	1	0	1
MS-2	15	0	0	1	0	1
TOTAL	108	0	0	7	0	7
DIEP						
Unilateral (MS-3)						
MS-3	8	0	0	0	0	0
Bilateral (MS-3)						
MS-3	2	0	0	0	0	0
TOTAL	10	0	0	0	0	0

Abbreviations as in Table I.

TABLE VI
Historical Review of Abnormal Abdominal Contour after Breast Reconstruction with Abdominal Flaps

Author	Year	Patients	Type of Flap	Mesh	Bulge	Hernia
Hartrampf ¹	1984	82	UPT (<i>n</i> = 68) BPT (<i>n</i> = 14)	82/82	NR	1/68 (1.2%)
Lejour and Dome ²	1991	57	UPT (<i>n</i> = 33) BPT (<i>n</i> = 24)	57/57	0	0
Kroll and Marchi ³	1992	130	UPT (<i>n</i> = 40) BP-UPT (<i>n</i> = 83) BPT (<i>n</i> = 7)	17/130	25/130 (19%)	5/130 (4%)
Mizgala et al. ⁴	1994	662	UPT (<i>n</i> = 296) BP-UPT (<i>n</i> = 146) BPT (<i>n</i> = 214)	120/662	5/296 (1.7%) 0 7/214 (3.3%)	5/296 (1.7%) 2/146 (1.4%) 2/214 (0.9%)
Feller ⁵	1995	151	UFT (<i>n</i> = 139) BFT (<i>n</i> = 12)	NR	22/151 (15%)	0
Zeinowicz and May ⁶	1995	65	UPT (<i>n</i> = 63) BPT (<i>n</i> = 2)	65/65	1/65 (1.5%)	1/65 (1.5%)
Kroll et al. ⁷	1995	268	UPT (<i>n</i> = 40) BPT (<i>n</i> = 60) UFT (<i>n</i> = 123) BFT (<i>n</i> = 45)	45/100 36/168	2/40 (5%) 2/60 (3.4%) 5/123 (4.1%) 1/45 (2.2%)	2/40 (5%) 1/60 (1.7%) 4/123 (3.3%) 0
Suominen et al. ⁸	1996	43	PT (<i>n</i> = 16) FT (<i>n</i> = 27)	4/16 0/27	7/16 (44%) 1/27 (4%)	0 0
Blondeel et al. ⁹	1997	38	UD (<i>n</i> = 18) UFT (<i>n</i> = 20)	0/18 18/20	0 2 (10%)	0 1/20 (5%)
Edsander-Nord et al. ¹⁰	1998	41	PT (<i>n</i> = 21) FT (<i>n</i> = 17)	9/21 4/17	10/21 (48%) 14/17 (82%)	0 0
Arnaz et al. ¹¹	1999	15	UD (<i>n</i> = 13) UFT (<i>n</i> = 2)	0/13 0/2	1/13 (8%) 0	0 0
Hamdi et al. ¹²	1999	42	UD (<i>n</i> = 34) BD (<i>n</i> = 8)	0/34 0/8	2/42 (5%)	0 0
Nahabedian and Manson ¹⁵	2002	101	UPT (<i>n</i> = 13) UFT (<i>n</i> = 58) BPT (<i>n</i> = 17) BFT (<i>n</i> = 13)	0/13 0/58 9/17 7/13	3/13 (23%) 2/58 (3.4%) 3/17 (17%) 3/13 (23%)	0 0 0 0

NR, no report; D, DIEP flap; other abbreviations as in Table IV.

tive studies between the free TRAM and DIEP flap have also demonstrated mixed results.^{9,11} Evaluations of abdominal strength, however, have demonstrated that the free TRAM flap is superior to the pedicled TRAM flap⁷ and that the DIEP flap may be superior to the free TRAM flap.⁹ Postoperative magnetic resonance imaging scans have demonstrated less than 5 percent muscle atrophy in 80 percent of women after DIEP flap reconstruction.⁹

The present study demonstrated that the difference in the frequency of abnormal abdominal contour after unilateral breast reconstruction with the pedicled and free TRAM flaps and DIEP flaps is not explained by muscle-sparing; however, the observed difference after bilateral reconstruction is explained by muscle-sparing. The observed difference in frequency may be secondary to factors related to the anterior rectus sheath, which include the amount of sheath resected, prior abdominal operations, and the fibrous strength of the sheath. Previous studies have demonstrated an increased incidence of lower bulge after bilateral

breast reconstruction with abdominal flaps in the presence of a previous lower midline incision.¹⁵

Recommendations for minimizing the incidence of abnormal abdominal contour after pedicled and free TRAM reconstruction include the following: plication of the anterior rectus sheath above and below the resected fascial territory, contralateral plication sutures to centralize the umbilicus, and onlay synthetic mesh used in the presence of a previous midline abdominal incision, anterior rectus sheath attenuation, and excessive fascial harvest. Upper abdominal fullness after pedicled TRAM reconstruction can be reduced by the tangential excision of subcutaneous fat in the upper abdominal skin flap.

CONCLUSIONS

The lower abdominal bulge is the most common abnormality of the abdomen after breast reconstruction with abdominal flaps. Muscle-sparing does not seem to explain differences in abnormal contour for all methods of unilateral

reconstruction but does explain the differences in bilateral free TRAM reconstruction. Comparisons between the pedicled and free TRAM flap demonstrate that upper fullness and bulge are significantly reduced with the free TRAM flap and that lower bulge complication with the pedicled flap approaches significance. The difference in abnormal contour for the DIEP flap and free TRAM flap was not explained by muscle-sparing alone, although the sample size for the DIEP flap was relatively small.

Maurice Nahabedian, M.D.
 Johns Hopkins Medical Institutions
 601 North Caroline Street, Suite 8152C
 Baltimore, Md. 21287
 mnahabed@jhmi.edu

REFERENCES

1. Hartrampf, C. R., Jr. Abdominal wall competence in transverse abdominal island flap operations. *Ann. Plast. Surg.* 12: 139, 1984.
2. Lejour, M., and Dome, M. Abdominal wall function after rectus abdominis transfer. *Plast. Reconstr. Surg.* 87: 1054, 1991.
3. Kroll, S. S., and Marchi, M. Comparison of strategies for preventing abdominal-wall weakness after TRAM flap breast reconstruction. *Plast. Reconstr. Surg.* 89: 1045, 1992.
4. Mizgala, C. L., Hartrampf, C. R., Jr., and Bennett, G. K. Abdominal function after pedicled TRAM flap surgery. *Clin. Plast. Surg.* 21: 255, 1994.
5. Feller, A. M. Free TRAM: Results and abdominal wall function. *Clin. Plast. Surg.* 21: 223, 1994.
6. Zienowicz, R. J., and May, J. W., Jr. Hernia prevention and aesthetic contouring of the abdomen following TRAM flap breast reconstruction by the use of polypropylene mesh. *Plast. Reconstr. Surg.* 96: 1346, 1995.
7. Kroll, S. S., Schusterman, M. A., Reece, G. P., Miller, M. J., Robb, G., and Evans, G. Abdominal wall strength, bulging, and hernia after TRAM flap breast reconstruction. *Plast. Reconstr. Surg.* 96: 616, 1995.
8. Suominen, S., Asko-Seljavaara, S., von Smitten, K., et al. Sequelae in the abdominal wall after pedicled or free TRAM flap surgery. *Ann. Plast. Surg.* 36: 629, 1996.
9. Blondeel, N., Vanderstraeten, G. G., Monstrey, S. J., et al. The donor site morbidity of free DIEP flaps and free TRAM flaps for breast reconstruction. *Br. J. Plast. Surg.* 50: 322, 1997.
10. Edsander-Nord, A., Jurell, G., and Wickman, M. Donor-site morbidity after pedicled or free TRAM flap surgery: A prospective and objective study. *Plast. Reconstr. Surg.* 102: 1508, 1998.
11. Arnaz, Z. M., Kahn, U., Pogorelec, D., and Planinsek, F. Rational selection of flaps from the abdomen in breast reconstruction to reduce donor site morbidity. *Br. J. Plast. Surg.* 52: 351, 1999.
12. Hamdi, M., Weiler-Mithoff, E. M., and Webster, M. H. Deep inferior epigastric perforator flap in breast reconstruction: Experience with the first 50 flaps. *Plast. Reconstr. Surg.* 103: 86, 1999.
13. Reece, G. P., and Kroll, S. S. Abdominal wall complications: Prevention and treatment. *Clin. Plast. Surg.* 25: 235, 1998.
14. Petit, Y. J., Rietjens, M., Ferreira, M. A. R., et al. Abdominal sequelae after pedicled TRAM flap breast reconstruction. *Plast. Reconstr. Surg.* 99: 723, 1997.
15. Nahabedian, M. Y., and Manson, P. M. Contour abnormalities of the abdomen following TRAM flap breast reconstruction: A multifactorial analysis. *Plast. Reconstr. Surg.* 109: 81, 2002.
16. Zauner-Dungl, A., Resch, K. L., Herczeg, E., and Pizakatz, H. Quantification of functional deficits associated with rectus abdominis muscle flaps. *Plast. Reconstr. Surg.* 96: 1623, 1995.
17. Galli, A., Adami, M., Berrino, P., et al. Long-term evaluation of abdominal wall competence after total and selective harvesting of the rectus abdominis muscle. *Ann. Plast. Surg.* 28: 409, 1992.
18. Suominen, S., Asko-Seljavaara, S., Kinnunen, J., and Alaranta, H. Abdominal wall competence after free transverse rectus abdominis musculocutaneous flap harvest: A prospective study. *Ann. Plast. Surg.* 39: 229, 1997.
19. Blondeel, N., Boeckx, W. D., Vanderstraeten, G. G., et al. The fate of the oblique abdominal muscles after free TRAM flap surgery. *Br. J. Plast. Surg.* 50: 315, 1997.
20. Suominen, S., Tervahartiala, P., von Smitten, K., and Asko-Seljavaara, S. Magnetic resonance imaging of the TRAM flap donor site. *Ann. Plast. Surg.* 38: 23, 1997.
21. Grotting, J. C., Urist, M. M., Maddox, W. A., and Vasconez, L. O. Conventional TRAM flap versus free microsurgical TRAM flap for immediate breast reconstruction. *Plast. Reconstr. Surg.* 83: 828, 1989.
22. Allen, R. J., and Treece, P. Deep inferior epigastric perforator flap for breast reconstruction. *Ann. Plast. Surg.* 32: 32, 1994.
23. Bostwick, J. Abdominal flap reconstruction. In J. Bostwick (Ed.), *Plastic and Reconstructive Breast Surgery*, 2nd Ed. St. Louis: Quality Medical Publishing, 2000. Pp. 1016-1029.
24. Hartrampf, C. R., Michelow, B. J., and Taylor, G. I. Anatomy of the anterior abdominal wall. In C. R. Hartrampf, Jr. (Ed.), *Hartrampf's Breast Reconstruction with Living Tissue*. New York: Raven Press, 1991. Pp. 2-19.
25. Duchateau, J., Declety, A., and Lejour, M. Innervation of the rectus abdominis muscle: Implications for rectus flaps. *Plast. Reconstr. Surg.* 82: 223, 1988.
26. Hammond, D. C., Larson, D. L., Severinac, R. N., and Marcias, M. Rectus abdominis muscle innervation: Implications for TRAM flap elevation. *Plast. Reconstr. Surg.* 96: 105, 1995.
27. Hartrampf, C. R., Jr. The transverse abdominal island flap for breast reconstruction: A 7-year experience. *Clin. Plast. Surg.* 15: 703, 1988.
28. Kroll, S. S., Schusterman, M. A., and Mistry, D. The internal oblique repair of abdominal bulges secondary to TRAM flap breast reconstruction. *Plast. Reconstr. Surg.* 96: 100, 1995.
29. Moscona, R. A., Ramon, Y., Toledano, H., and Barzilay, G. Use of synthetic mesh for the entire abdominal wall after TRAM flap transfer. *Plast. Reconstr. Surg.* 101: 706, 1998.
30. Pennington, D. G., and Lam, T. Gore-Tex patch repair of the anterior rectus sheath in free rectus abdominis

- muscle any myocutaneous flaps. *Plast. Reconstr. Surg.* 97: 1436, 1996.
31. Bucky, L. P., and May, J. W., Jr. Synthetic mesh: Its use in abdominal wall reconstruction after the TRAM. *Clin. Plast. Surg.* 21: 273, 1994.
32. Koshima, I., and Soeda, S. Inferior epigastric artery skin flap without rectus abdominis muscle. *Br. J. Plast. Surg.* 42: 645, 1989.
33. Arnez, Z. M., Smith, R. W., Eder, E. et al. Breast reconstruction by the free lower transverse rectus abdominis musculocutaneous flap. *Br. J. Plast. Surg.* 41: 500, 1988.
34. Kind, G. M., Rademaker, A. W., and Mustoe, T. A. Abdominal-wall recovery following TRAM flap: A functional outcome study. *Plast. Reconstr. Surg.* 99: 417, 1997.