

# Abdominal Wall Reconstruction With the Free Tensor Fascia Lata Musculofasciocutaneous Flap Using Intraperitoneal Gastroepiploic Recipient Vessels

Pierre M. Chevray, MD, PhD\*

Navin K. Singh, MD†

The authors report their experience with a method for definitive abdominal wall reconstruction using the free tensor fascia lata musculofasciocutaneous flap anastomosed to the intraperitoneal gastroepiploic vessels. This is a single-stage reconstruction capable of reconstructing reliably a full-thickness defect involving any region of the abdominal wall. The fascial component of the flap reconstructs the abdominal wall with like tissue, and the cutaneous portion of the free tensor fascia lata provides a durable and aesthetically acceptable external cover. The intraperitoneal gastroepiploic artery and vein were the first-choice recipient vessels used in all three patients. These intraperitoneal recipient vessels allow uninterrupted fascial closure, restoring structural integrity to the abdominal wall, and allow the use of free flaps with short vascular pedicles. The authors present a series of three cases of full-thickness upper and lower abdominal wall reconstruction using this method, presenting its advantages compared with other methods.

Chevray PM, Singh NK. Abdominal wall reconstruction with the free tensor fascia lata musculofasciocutaneous flap using intraperitoneal gastroepiploic recipient vessels. *Ann Plast Surg.* 2003;51:97-102.

From the \*Department of Plastic Surgery, University of Texas M.D. Anderson Cancer Center, Houston, TX; and †Division of Plastic Surgery, Johns Hopkins Hospital, Baltimore, MD.

Received May 3, 2002, and in revised form Aug 31, 2002. Accepted for publication Aug 31, 2002.

Address correspondence and reprint requests to Dr. Chevray, Department of Plastic Surgery, University of Texas M.D. Anderson Cancer Center, 1515 Holcombe Boulevard, Box 443, Houston, TX 77030.

Reconstruction of large abdominal wall defects and hernias that cannot be closed primarily are problematic. Methods to solve this problem include use of prosthetic mesh, free fascial grafts, the components separation technique,<sup>1</sup> tissue expansion,<sup>2,3</sup> regional flaps, and free flaps. Prosthetic mesh, fascial grafts and flaps,<sup>4,5</sup> components separation, and internal tissue expansion are designed to reconstruct the fascial strength layer of the abdominal wall and are insufficient when the overlying abdominal skin cannot be reapproximated. Prosthetic mesh has increased risk for infection and enteric fistula

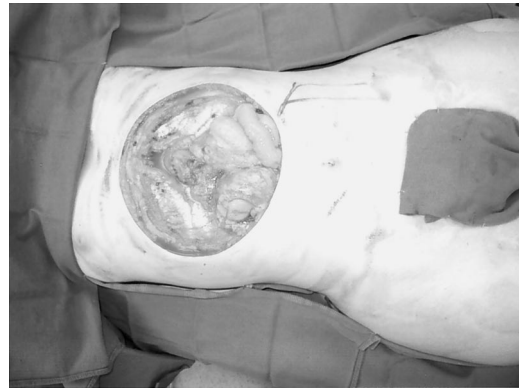formation and is relatively contraindicated in contaminated fields. The components separation technique is useful for midline and central defects. It is not effective for lateral defects or in cases of loss of the rectus abdominus muscles and fascia. Internal tissue expansion is a two-stage procedure that is not used widely. Commonly used regional flaps can provide a fascial and skin-covering component but typically cannot reach to reconstruct defects superior to the umbilicus.<sup>6</sup>

The tensor fascia lata (TFL) musculofasciocutaneous flap can provide a large and strong fascial component and skin and subcutaneous coverage for abdominal wall reconstruction.<sup>6-8</sup> Used as a free tissue transfer,<sup>9</sup> it can reconstruct large, full-thickness defects of any region of the abdominal wall.<sup>10,11</sup> The TFL muscle can also be reinnervated to reconstruct motor function of the abdominal wall.<sup>12</sup>

Identifying reliable recipient blood vessels in proximity to the field of interest is perhaps the most important step in a microvascular reconstruction. The use of various extraperitoneal recipient vessels such as the deep inferior epigastric vessels, the internal mammary vessels, and the saphenous vein, for abdominal wall reconstruction with the free TFL flap have been described.<sup>10,12</sup> However, intraperitoneal recipient vessels are conceptually superior because they are typically located immediately adjacent to the deep surface of the defect. This allows use of free flaps with short pedicles, or pedicles originating from the center of a wide, flat flap such as the TFL.<sup>11,13</sup> In addition, this arrangement allows a tight, continuous, circumferential fascial closure between the flap and native abdominal wall, which is topologically not possible when using extraperitoneal vessels.<sup>10</sup> Use of the intraperitoneal gastroepiploic vessels as recipi-



*Fig 1. Preoperative anterior view of the trunk showing the protruding subxiphoid, upper abdominal desmoid tumor, and previous chevron incision (patient 1).*



*Fig 2. Full-thickness 16-cm-diameter circular upper abdominal resection defect (patient 1).*

ents for free tissue transfer was first described in 1973<sup>14</sup> and subsequently by others.<sup>10,11,13,15</sup> The right and left gastroepiploic artery and vein have high flow rates, diameters of 2 to 3 mm, are easily identified, and are easily dissected. Their freely mobile length can exceed 10 cm, approximating the length of the greater curvature of the stomach.

We present a series of three cases of full-thickness upper or lower abdominal wall reconstruction using the free TFL musculofasciocutaneous flap anastomosed to the gastroepiploic vessels as first-choice recipient vessels. Three previous cases have been reported in the literature<sup>10,11</sup> with the gastroepiploic vessels used as a second choice when extraperitoneal recipient vessels were inadequate.

## Patient Reports

The defects in these three patients resulted from tumor resections. The patients were managed at separate institutions by the two authors individually. All three patients were ambulatory, at home, and tolerating a regular diet at a mean follow-up of 5 months.

### Patient 1

A 30-year-old healthy, nonsmoking woman had a 9-cm desmoid tumor at the apex of the subcostal chevron incision created 2 years earlier for elective donor hepatectomy (Fig 1). She underwent radical resection of the desmoid tumor by a surgical oncologist. This resulted in a full-thickness 16-cm-diameter circular midline abdominal wall defect extending from the xiphoid process inferiorly to within 5 cm of the umbilicus (Fig 2).

A 18- × 15-cm left TFL musculofasciocutaneous free flap was harvested with a 4-cm vascular pedicle taken to its origin from the deep femoral artery. Despite previous upper abdominal surgery, the right gastroepiploic vessels were identified easily and mobilized for 8 cm. The flap was transferred, and TFL fascia was sutured to abdominal wall fascia circumferentially. The left thigh donor site was closed partially and skin grafted (Fig 3).

The patient was readmitted on postoperative day 14 for abdominal distention and 6 hours of nausea and vomiting. This resolved with enemas for constipation related to narcotic analgesic use. The abdominal distention and vomiting had no negative effect on the arterial or venous sufficiency of the free flap. Two months following surgery the patient was at home, ambulatory, tolerating a regular diet, and had returned to work (Fig 4A). Eight months after the initial operation the left thigh donor site was revised by excision of the skin graft and primary closure (Fig 3B), and the laxity of the abdominal reconstruction was corrected by direct excision of redundant free TFL flap tissue (Figs 4B and 4C).

### Patient 2

A 55-year-old nonsmoking man with recurrent left pelvic retroperitoneal leiomyosarcoma involving the common iliac vessels and sciatic nerve was treated with preoperative chemotherapy. Surgical resection by a multidisciplinary team consisted of left external hemipelvectomy (amputation of the left leg) and pelvic exenteration. The left lower quadrant external hemipel-

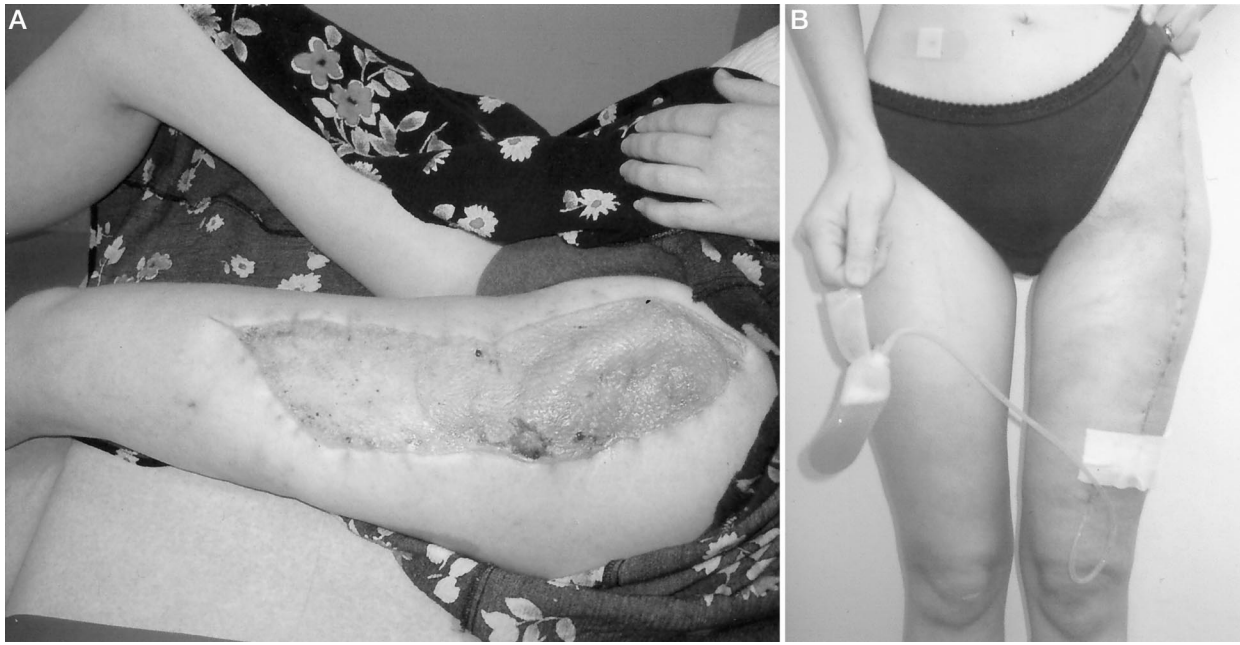


Fig 3. (A) Left lateral thigh TFL flap donor site, which required skin graft closure. (B) Anterior view of left thigh TFL donor site following revision by excision of the skin graft and primary closure (patient 1).

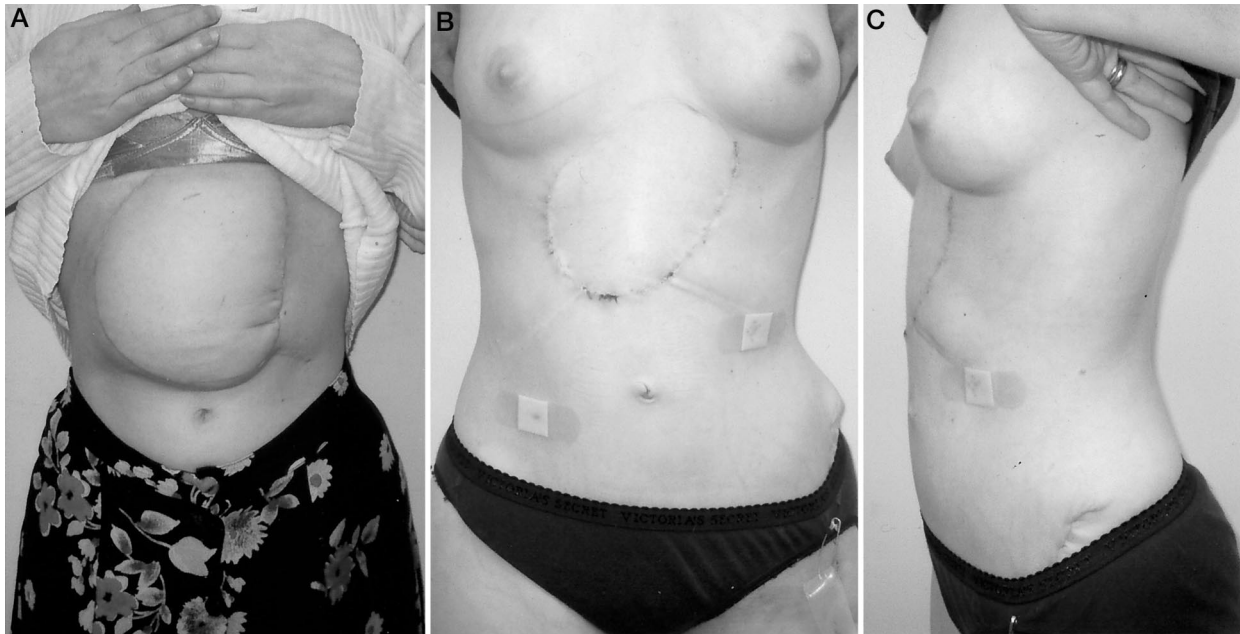


Fig 4. (A) Two month post-operative view of patient standing. Healed upper abdominal wall reconstruction. (B, C) Anterior and lateral views of abdominal wall reconstruction following correction of laxity by direct excision of redundant free TFL flap tissue (patient 1).

vectomy defect was closed with a pedicled gluteus maximus musculocutaneous flap.

The mid and lower abdominal defects were closed with a free TFL musculofasciocutaneous flap harvested from the amputated left leg (Fig 5). The flap pedicle was taken to the origin of the

lateral femoral circumflex vessels from the deep femoral vessels, and was approximately 6 cm long when straightened (Fig 6). The flap was ischemic for more than 7 hours, including completion of the ablative surgery, in addition to the revascularization microsurgery. During most of

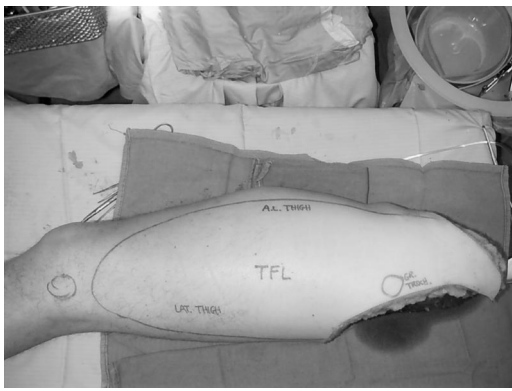

Fig 5. Amputated left leg with overlapping cutaneous territories of the tensor fascia lata, lateral thigh, and anterolateral thigh flaps marked (patient 2).

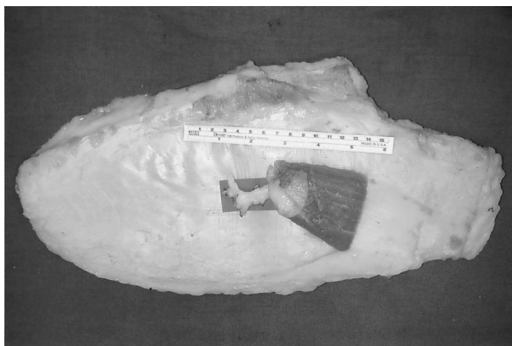


Fig 6. The tensor fascia lata (TFL) musculofasciocutaneous flap showing the short vascular pedicle taken at the origin of the lateral femoral circumflex vessels from the deep femoral vessels. The TFL muscle has been reflected toward the center of the flap (patient 2).

the ischemic time the flap was kept cool with towels soaked in a frozen slurry of normal saline solution.

Despite adhesions from previous abdominal surgery, the left gastroepiploic vessels were identified easily along the greater curvature of the stomach and were dissected free. The left gastroepiploic artery was 2.5 mm and the vein was 3 mm in external diameter. The flap was transferred, and the TFL fascia was sutured to the rectus abdominis fascia and linea alba. At the 6-month postoperative follow-up (Fig 7) the patient lives at home, has returned to his previous work full time, ambulates with crutches and a prosthetic left leg, and is without evidence of disease.

### Patient 3

A 36-year-old nonsmoking, Nigerian albino man was treated for a large, ulcerated, recurrent,

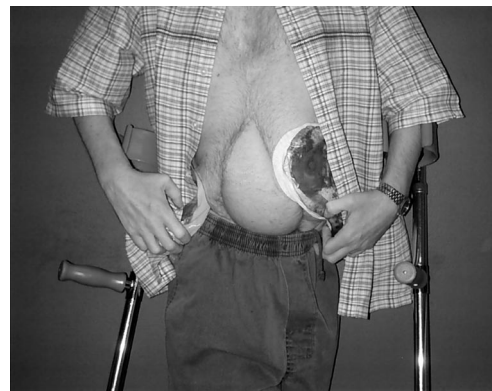

Fig 7. Two-month postoperative view of the patient standing. The patient is ambulatory with crutches and a prosthetic leg (not shown). The healed mid and lower abdominal flap, left colostomy, and right abdominal urinary conduit ostomy are shown (patient 2).

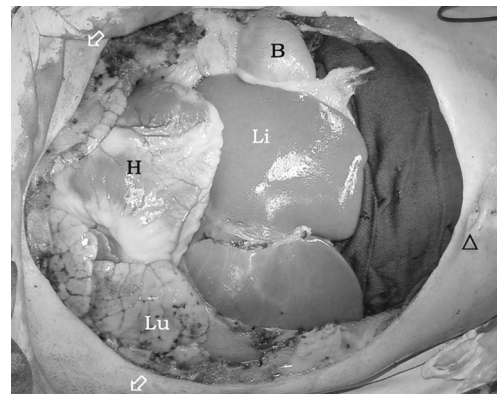


Fig 8. Full-thickness thoracoabdominal wall resection defect (patient 3). The umbilicus is indicated by the black triangle and the two nipples are indicated by the white arrows. H = heart; Lu = lung; Li = liver; B = intestine.

full-thickness anterior chest and abdominal wall basosquamous cell carcinoma. The surgical resection encompassed most of his anterior chest and abdominal wall and included diaphragm and pericardium (Fig 8). This is the largest full-thickness thoracoabdominal wall reconstruction of which we are aware.

A 33- × 13-cm right free TFL musculofasciocutaneous flap was harvested, and the donor site was closed with a skin graft. The right gastroepiploic vessels were dissected free from the omentum for approximately 6 cm. The flap was transferred uneventfully (Fig 9). The TFL fascia was sutured to the abdominal wall fascia and superiorly to the junction of the diaphragm and Marlex mesh reconstructing the thoracic cage.

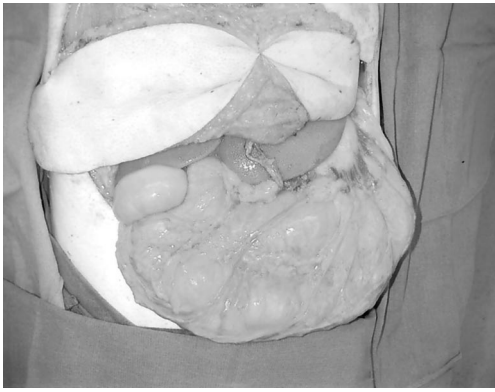


Fig 9. The free tensor fasciae lata musculofasciocutaneous flap is shown lying on the liver, anastomosed to the left gastroepiploic vessels. The omentum is draped over the bowel and lower abdomen (patient 3).

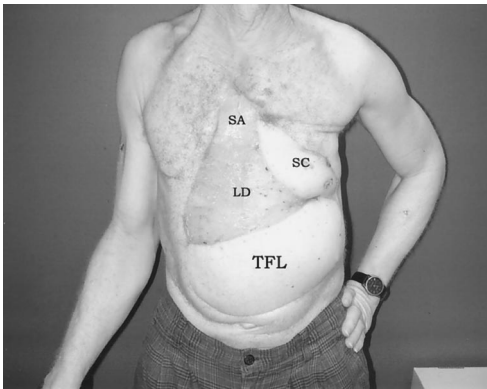


Fig 10. Four-month postoperative view of the patient standing. Healed upper abdominal wall reconstruction (patient 3). TFL = tensor fasciae lata free flap; LD = latissimus dorsi muscle free flap; SA = serratus anterior muscle free flap; SC = scapular fasciocutaneous free flap.

Four months after surgery, the patient was ambulatory, living independently, and returned home to Nigeria (Fig 10).

## Discussion

The free TFL flap is attractive for reconstruction of large abdominal wall defects.<sup>7</sup> Unlike the pedicled or island TFL flap, the free flap can reconstruct upper as well as lower abdominal defects. It can provide fascia, skin, subcutaneous tissue, and muscle to reconstruct full-thickness abdominal wall defects with like tissues. Its large and strong fascial component is nearly ideal for this purpose. The skin and subcutaneous tissue of the

abdominal wall is reconstructed with identical tissue from the flap, which typically has a close color match and thereby provides aesthetically acceptable external coverage. The free TFL flap is capable of withstanding tumoricidal doses of radiation therapy. In principle, the muscular component of the flap could be innervated to contribute motor or cutaneous sensory function.<sup>12</sup> Including the areolar tissue or muscle perimysium on the deep surface of the TFL fascia may prevent intraperitoneal adhesion formation.<sup>12</sup>

Intraperitoneal recipient blood vessels exist at the base of full-thickness abdominal wall defects. This allows use of free flaps with short vascular pedicles, even when the pedicle originates from the center of broad, flat flaps such as the TFL musculofasciocutaneous flap. Furthermore, use of intraperitoneal vessels allows a continuous, tight, circumferential fascial closure that is not possible when extraperitoneal vessels are used. The gastroepiploic vessels, in particular, are easy to find along the greater curvature of the stomach, even in patients with previous abdominal surgery as in two patients in this series. The gastroepiploic vessels can be mobilized for 10 cm or more, and can reach long distances if dissected as part of an omental flap.<sup>15</sup> For these reasons, we think that the gastroepiploic vessels should be a first-choice recipient vessel for free flap reconstruction of full-thickness abdominal wall defects. The combination of the free TFL musculofasciocutaneous flap and gastroepiploic recipient vessels is capable of reconstructing reliably full-thickness upper or lower abdominal wall defects in a single stage, with like tissue, and with aesthetically acceptable results.

## References

- 1 Ramirez O, Ruas E, Dellon A. "Components separation" method for closure of abdominal-wall defects: an anatomic and clinical study. *Plast Reconstr Surg.* 1990;86: 519-526.
- 2 Jacobsen W, Petty P, Bite U, et al. Massive abdominal-wall hernia reconstruction with expanded external/internal oblique and transversalis musculofascia. *Plast Reconstr Surg.* 1997;100:326-335.
- 3 Har-Shai Y, Schien M, Loberman Z, et al. Reconstruction of large skin-grafted abdominal wall defect after laparos-

- tomy: capsulofascial turnover flaps. *Contemp Surg*. 1998; 53:11–32.
- 4 Wangenstein O. Repair of recurrent and difficult hernias and other large defects of the abdominal wall employing the iliotibial tract of fascia latae as a pedicled flap. *Surg Gynecol Obstet*. 1934;59:766–780.
  - 5 Wangenstein O. Repair of large abdominal defects by pedicled fascial flaps. *Surg Gynecol Obstet*. 1946;82:144–150.
  - 6 Caffee H. Reconstruction of the abdominal wall by variations of the tensor fasciae latae flap. *Plast Reconstr Surg*. 1983;71:348–353.
  - 7 O'Hare P, Leonard A. Reconstruction of major abdominal wall defects using the tensor fasciae latae myocutaneous flap. *Br J Plast Surg*. 1982;35:361–366.
  - 8 Nahai F, Hill H, Hester T. Experiences with the tensor fascia lata flap. *Plast Reconstr Surg*. 1979;63:788–799.
  - 9 Hill L, Nahai F, Vasconez L. The tensor fascia lata myocutaneous free flap. *Plast Reconstr Surg*. 1978;61: 517–522.
  - 10 Penington A, Theile D, MacLeod A, et al. Free tensor fasciae latae flap reconstruction of defects of the chest and abdominal wall: selection of recipient vessels. *Scand J Plast Reconstr Surg Hand Surg*. 1996;30:299–305.
  - 11 Sekido M, Yamamoto Y, Sugihara T, et al. Microsurgical reconstruction of chest-and abdominal-wall defects associated with intraperitoneal vessels. *J Reconstr Microsurg*. 1996;12:425–430.
  - 12 Sasaki K, Nozaki M, Nakazawa H, et al. Reconstruction of a large abdominal wall defect using combined free tensor fasciae latae musculocutaneous flap and anterolateral thigh flap. *Plast Reconstr Surg*. 1998;102:2244–2252.
  - 13 Yamamoto Y, Nohira K, Minakawa H, et al. Use of intraperitoneal vessels in reconstructive microsurgery: an account of 117 cases. *Scand J Plast Reconstr Surg Hand Surg*. 1998;32:179–183.
  - 14 Harii K, Ohmori S. Use of the gastroepiploic vessels as recipient or donor vessels in the free transfer of composite flaps by microvascular anastomoses. *Plast Reconstr Surg*. 1973;52:541–548.
  - 15 Clement R, Young V, Marsh J. Use of the greater omentum as a vascular supply for free-flap transfer. *Plast Reconstr Surg*. 1984;74:131–132.